

JANUARY 2018

VOLUME 32

NUMBER 1

SUPPLEMENT TO

JOT

www.jorthotrauma.com

JOURNAL OF ORTHOPAEDIC TRAUMA



FRACTURE AND DISLOCATION CLASSIFICATION COMPENDIUM—2018

OFFICIAL JOURNAL OF

Orthopaedic Trauma Association

AO Trauma North America


Belgian Orthopaedic Trauma Association

Canadian Orthopaedic Trauma Society

Foundation for Orthopedic Trauma

International Society for Fracture Repair

The Japanese Society for Fracture Repair

 Wolters Kluwer

Contents

Fracture and Dislocation Compendium—2018

*A joint collaboration between the Orthopaedic Trauma Association
and the AO Foundation*

- S1 Introduction
- S11 Humerus
- S21 Radius and Ulna
- S33 Femur
- S45 Patella
- S49 Tibia
- S61 Fibula
- S65 Malleolar segment
- S71 Pelvic ring
- S77 Acetabulum
- S83 Hand and carpus
- S89 Foot
- S101 Scapula
- S105 Clavicle
- S106 OTA Open Fracture Classification (OTA-OFC)
- S107 Dislocations
- S117 AO Pediatric Comprehensive Classification of Long Bone Fractures (PCCF)
- S141 Unified Classification System for Periprosthetic Fractures (UCPF)
- S145 Spine
- S161 Thorax
- S167 Appendix

(continued next page)

Contents (continued)



Journal of Orthopaedic Trauma (ISSN 0890-5339) is published monthly by Wolters Kluwer Health, Inc., at 14700 Citicorp Drive, Bldg 3, Hagerstown, MD 21742. Business and production offices are located at Two Commerce Square, 2001 Market St., Philadelphia, PA 19103. Periodicals postage paid at Hagerstown, MD and at additional mailing offices. Copyright © 2017 Wolters Kluwer Health, Inc. All rights reserved.

The *Journal of Orthopaedic Trauma* was founded in partnership with the Orthopaedic Trauma Association (OTA) and is the official publication of the OTA.

Annual Subscription Rates: *United States*—\$746.00 Individual, \$1,820.00 Institution, \$304.00 In training. *Rest of the World*—\$870.00 Individual, \$2,056.00 Institution, \$319.00 In training. Single copy rate \$172. All prices include a handling charge. Subscriptions outside of North America must add \$26.00 for airfreight delivery. United States residents of AL, CO, DC, FL, GA, HI, IA, ID, IN, KS, KY, LA, MD, MO, ND, NM, NV, PR, RI, SC, SD, UT, VT, WA, WV add state sales tax. The GST tax of 7% must be added to all orders shipped to Canada (Wolters Kluwer Health, Inc.'s GST Identification #895524239, Publications Mail Agreement #617687). Subscription prices outside the United States must be prepaid. Prices subject to change without notice. Visit us online at www.lww.com.

Individual and in-training subscription rates include print and access to the online version. Institutional rates are for print only; online subscriptions are available via Ovid. Institutions can choose to purchase a print and online subscription together for a discounted rate. Institutions that wish to purchase a print subscription, please contact Wolters Kluwer Health, Inc. at 14700 Citicorp Drive, Bldg 3, Hagerstown, MD 21742; phone 800-638-3030 (outside the United States 301-223-2300); fax 301-223-2400. Institutions that wish to purchase an online subscription or online with print, please contact the Ovid Regional Sales Office near you or visit www.ovid.com/site/index.jsp and select Contact and Locations.

Website: www.jorthotrauma.com

Postmaster: Send address changes to *Journal of Orthopaedic Trauma*, P.O. Box 1610, Hagerstown, MD 21740.

Listed in *Index Medicus/MEDLINE*, *Current Contents/Clinical Medicine*, *Scisearch*, *Research Alert*, *Focus On: Sports Science and Medicine*, *Sociedad Iberoamericana de Información Científica*.

Address for non-member subscription information, orders, or change of address (except Japan): 14700 Citicorp Drive, Bldg 3, Hagerstown, MD 21742; phone 800-638-3030 (outside the United States 301-223-2300); fax 301-223-2400. In Japan, contact Wolters Kluwer Health Japan Co., Ltd., Forecast Mita Building 5th floor, 1-3-31 Mita Minato-ku, Tokyo, Japan 108-0073. Telephone: +81 3 5427 1969. E-mail: journal@wkjapan.co.jp

Wolters Kluwer Health cannot be held responsible for errors or for any consequences arising from the use of the information contained in this journal. The appearance of scientific reports and/or workshops, or any other material in the *Journal of Orthopaedic Trauma* does not constitute an endorsement or approval by Wolters Kluwer Health of the findings, data, conclusions, recommendations, procedures, results, or any other aspect of the content of such articles. The appearance of advertising in the *Journal of Orthopaedic Trauma* does not constitute an endorsement or approval by Wolters Kluwer Health, Inc. of the quality or value of the products advertised or any of the claims, data, conclusions, recommendations, procedures, results or any other information included in the advertisements.

Permissions: For permission and/or rights to use content for which the copyright holder is Wolters Kluwer Health or the society, please go to the journal's website and after clicking on the relevant article, click on the "Request Permissions" link under the "Article Tools" box that appears on the right side of the page. Alternatively, send an e-mail to customer-care@copyright.com.

For Translation Rights & Licensing queries, contact Silvia Serra, Translations Rights, Licensing & Permissions Manager, Wolters Kluwer Health (Medical Research) Ltd, 250 Waterloo Road, London SE1 8RD, UK. Phone: +44 (0) 207 981 0600. E-mail: silvia.serra@wolterskluwer.com

For Special Projects (U.S./Canada), contact Alan Moore, Director of Sales, Wolters Kluwer Health, Two Commerce Square, 2001 Market Street, Philadelphia, PA 19103. Phone: 215-521-8638. E-mail: alan.moore@wolterskluwer.com

For Special Projects (non-U.S./Canada), contact Silvia Serra, Translations Rights, Licensing & Permissions Manager, Wolters Kluwer Health (Medical Research) Ltd, 250 Waterloo Road, London SE1 8RD, UK. Phone: +44 (0) 207 981 0600. E-mail: silvia.serra@wolterskluwer.com

Instructions for Authors may be accessed on the journal's website at www.jorthotrauma.com.

Fracture and Dislocation Classification Compendium—2018

International Comprehensive Classification of Fractures and Dislocations Committee

AOTrauma International Board representatives: James F. Kellam MD, and Eric G. Meinberg MD***

*Orthopaedic Trauma Association representatives: Julie Agel MA, ATC ***, Matthew D. Karam, MD****, and Craig S. Roberts MD, MBA ******

Foreword

Dear Colleague

We would like to introduce you to the 2018 OTA/AO (or AO/OTA) Fracture and Dislocation Classification Compendium. This is the second revision of the compendium which was first published in 1996 as a cooperative effort of the AO Foundation and the Orthopaedic Trauma Association (OTA). Both organizations were committed to assuring that there was a standardized and rational methodology of describing fractures and dislocation as well as a mechanism to code data for future recall. These principles were absolutely necessary to establish a consistent system for clinical interaction and research.

After 20 years of use, the current revision addresses the many suggestions to help improve the application of the system, correct errors, and add new classifications. The process was under the direction of a committee of four individuals representing both organizations, with experience

in the day to day application of the compendium and fracture coding. The process was supervised and funded by the Classification Committee of the OTA and AOTrauma International Board (AOTIB). An ongoing agreement between both organizations to assure the ongoing collaborative support of the revision process of the compendium was also developed. Importantly, copyright will remain with both organizations so that its reproduction and promulgation will be unencumbered. This establishes not only mutual ownership but also responsibility and ensures continued collaboration and support.

We believe that this is an important step forward in the process of clinical research as well as standardizing day to day clinical communication. However, change is inevitable and both the OTA and the AOTIB encourage comment and criticisms so that the next revision process can continue to improve the compendium.

John H. Wilber MD
Chairman, AOTrauma International Board
Professor and Chair Department of Orthopaedic Surgery
MetroHealth Medical Center
Hansjoerg Wyss Professor Orthopaedic Trauma
Case Western Reserve University
Cleveland, Ohio

William M. Ricci MD
President, Orthopaedic Trauma Association
Chief, Combined HSS/NYP Trauma Service
Hospital for Special Surgery
New York Presbyterian Hospital
New York, NY

From the *Department of Orthopaedic Surgery, McGovern Medical School, University of Texas Health Sciences Center at Houston, ** Department of Orthopaedic Surgery, Zuckerberg San Francisco General Hospital, University of California, San Francisco; *** Department of Orthopaedic Surgery, Harborview Medical Center, Seattle, **** University of Iowa Department of Orthopaedics and Rehabilitation, Iowa City, ***** Department of Orthopaedic Surgery; University of Louisville School of Medicine

Disclosure: The authors report no conflicts of interest.

Material presented in this Compendium is based on the Comprehensive Classification of Fractures of Long Bones by M.E. Müller, J. Nazarian, P. Koch and J. Schatzker, Springer-Verlag, Berlin, 1990. The Orthopaedic Trauma Association is indebted to Professor Maurice Müller for allowing use of the system.

Correspondence: James F. Kellam, Department of Orthopaedic Surgery, McGovern Medical School, University of Texas Health Sciences Center at Houston, 6431 Fannin Street, MSB 6.146, Houston Texas, 77030 (e-mail: James.F.Kellam@uth.tmc.edu)

Copyright © 2017 by AO Foundation, Davos, Switzerland; Orthopaedic Trauma Association, IL, US

To encourage the use of this classification and this fracture classification compendium, the figures may be reproduced and the classification may be used for research, educational and or medical purposes without the need to request permission from the OTA, AO Foundation or the publisher. It cannot be used commercially or for-profit without permission.

Compendium introduction

The AO Foundation/Orthopaedic Trauma Association (AO/OTA) fracture classification was published as a compendium to the Journal of Orthopaedic Trauma (JOT) in 1996.¹ Using the principles of the Comprehensive Classification of Fractures of the Long Bones (CCF) developed by Müller and collaborators, the OTA classification committee classified and coded the remaining bones.^{2,3} This helped bring order to the state of fracture classification with its multiple systems that had thwarted any possibility of a standardized language and accumulation of uniform data.

Since the compendium was published in 1996, the classification has resided on the OTA and AO Foundation websites and has been regularly used in trauma databases, scientific journals, and textbooks worldwide. It is the official classification of the OTA, the AO, and JOT. It has gained wide acceptance and its use has dramatically improved the way information about fractures is communicated, stored, and used to advance knowledge. In some anatomical areas, this classification has largely supplanted multiple options achieving one of the original intentions.^{1,2,3}

The classification is intended to be a flexible evolving system in which changes are made based on user feedback, criticism, and appropriate clinical research, thus serving the needs of the orthopedic community for both clinical practice and research.

In 2007, the AO and OTA classification committees undertook a revision to address issues of reliability, reproducibility, and need. This revision was based on the premise that changes needed to be validated prior to being implemented. The validation process was expensive and not practical so a decision was made to not validate all edits. The 2007 revision standardized the two different alphanumeric codes into one agreed-upon scheme, thus developing an internationally recognized uniform system for clinical research on fractures and dislocations.

The validated AO Pediatric Classification of Fractures developed by Slongo was also included in the compendium.^{4,5} The two committees confirmed the original premise that the revision process needed to be undertaken every 10 years.

Ongoing concerns about terminology, the relevancy of certain classification schemes, and the need to streamline codes provided the impetus to undertake the 2018 review.^{6–12} To make this an effective, economical, and efficient process, the AOTrauma International Board (AOTIB) and OTA appointed five persons to form the International Comprehensive Classification of Fractures and Dislocations Committee (ICCF). The process began with the aims to address editorial errors, criticisms of the proximal humerus and proximal femur classification, and to simplify the coding process based on fracture pattern occurrence and complexity using a modified Delphi approach. A priority for this revision was to maintain the original principles of the CCF with regard to definitions and the basic coding system. It became apparent that many of the fracture patterns occurred so infrequently that there was no need to have a unique code for them, as they could easily be coded by a shortened generic system. Frequency plots of a large registry that uses these codes confirmed this. It became evident that it would be more accurate to code radius and ulna fractures separately and to align the system with ICD-10 terminology.¹³ The same was done for the other two-bone system by adding a new coding system for fibula fractures. The former editions had many qualifications and sub-qualifications for each fracture pattern, many of which were duplications. The committee decided to group these into a universal modifier list that could be applied to every fracture as desired by the end user, who codes the fracture. All fracture specific modifiers were maintained with their specific fracture or dislocation. As this classification system provides standard terminology and codes, it also felt appropriate to combine, insert, or reference other commonly accepted classifications (eg, Neer) into the AO/OTA descriptions and codes. This would assure consistency and greater clinical utility in fracture and dislocation classification.

The 2018 compendium revision

The compendium is branded as the AO/OTA or OTA/AO Fracture and Dislocation Classification Compendium. In publications, it will be cited as Meinberg E, Agel J, Roberts C, et al. Fracture and Dislocation Classification Compendium—2018, *Journal of Orthopaedic Trauma*. Volume 32: Number 1; Supplement, January 2018.

Future publications related to the revised Compendium will be authored and referenced as determined by the International Comprehensive Classification of Fractures and Dislocations Committee (ICFCF), irrespective of its member composition.

The mandates for the 2018 revision are the following:

- a) Editorial, terminology, and typographical changes and corrections:
 - i. The terms “complex” and “multifragmentary” have created confusion in their application. The term “complex” did not describe a fracture pattern consisting of many fragments while “multifragmentary” does. Multifragmentary was previously used generically to refer to diaphyseal type B and C and did not have a specific alphanumeric code so was rarely used. Consequently, the committee felt that it is more concise to have three types of diaphyseal fractures: simple, wedge, and multifragmentary. “Multifragmentary” will no longer be used as a generic term for diaphyseal types B and C. A multifragmentary diaphyseal or end segment extraarticular fracture is one with many fracture fragments and after reduction there is no contact between the main fragments. A multifragmentary complete articular fracture is one with more than two fracture fragments of the articular surface.
 - ii. The diaphyseal fracture classification has been made consistent for all bones. The diaphysis is defined as that part of the bone between the two end segments and is divided into three equal parts defining the location of the diaphyseal fracture. The fracture location within the diaphysis is a qualification as follows:
 - a Proximal 1/3
 - b Middle 1/3
 - c Distal 1/3
 - iii. A more precise description of the intraarticular portion of proximal tibia fractures has been recommended.^{14,15} A modification to the proximal tibia classification as recommended by Mauricio Kfuri and Joseph Schatzker to better define the significant joint fragmentation or displacement is added as qualifications for type B and C proximal tibial intraarticular fractures.¹⁶
 - iv. The written description of fractures has been standardized so that each fracture is presented in a similar order highlighting the specific region or fracture morphology.
 - v. To facilitate data entry and lessen the error rate in coding, the hyphen in the code has been removed.
 - vi. A code for fibula fractures based on the principles of the CCF has been added.
 - vii. The Neer classification has been integrated into the fracture description for proximal humeral fractures to facilitate the clinician comprehension of the terms unifocal and bifocal fractures.
 - viii. The proximal femoral classification terminology has been a source of confusion as a variety of descriptive terms have been used to describe similar fractures. There has also been a problem defining fractures for group 31A2. Definitions have been added to help classify these fractures and the codes reorganized to better represent these fractures. The femoral neck fractures have been organized to better align the fracture types. By adding the Pauwels classification as a qualification for femoral neck fractures a more detailed evaluation of high-energy fractures is available.
 - ix. The Young-Burgess Classification of Pelvic Ring Injuries has been integrated into the AO/OTA pelvic fracture classification.
- b) Addition of recently published validated classifications:
 - i. OTA Open Fracture Classification¹⁷
 - ii. AO/OTA Scapular Fracture Classification^{18,19}
 - iii. Unified Classification of Periprosthetic Fractures²⁰
 - iv. AOSpine Subaxial Cervical and Thoracolumbar spine injury classification²¹
 - v. AOSpine Sacral Fracture Classification²²
- c) At the request of the AOTK Thoracic Surgery Expert Group, a preliminary classification of rib and sternal fractures has been included. Publication of this classification will allow interested groups to assess its validity and reproducibility so in the next revision, a validated modification will be available.
- d) Review of the codes with regards to frequency and applicability:
 - i. Many of the qualifications and subqualifications of the first two compendiums were repetitious and on a survey of users were not routinely used. To simplify the usage, the common modifiers were placed in a list called Universal Modifiers. This simplifies the presentation of the codes and allows each clinician to use these as they see fit for their circumstances.
 - ii. Certain qualifications were fracture-specific and were left as qualifications within the specific fracture types and groups.
 - iii. Complex injuries such as the terrible triad of the elbow and a transolecranon fracture dislocation are difficult to code related to the fact that fractures of radius and ulna were placed into one code. The committee decided to separate the radius and ulna and classify fractures in each bone. This simplifies the process and when combined with the universal modifiers makes classification of complex injuries about the elbow more consistent and accurate. It also follows the ICD-10 system where each bone is coded separately.

It was recognized by the committee that this revision must maintain the principles and definitions of the CCF and the prior two compendiums. This revision represents a streamlining of the 2007 version. The aim was to assure that the majority of fracture patterns were represented. This revision provides a more concise and clinically relevant compendium. The user will be able to choose the code that best meets their needs. It is hoped that with the recognition of other standard classifications being integrated into the codes that this compendium will be of increasing value to many other orthopedic subspecialties.

Fundamentals of fracture classification

Classification is the process by which related groups are organized based on similarities and differences.⁵ It provides the language necessary to convey information among individuals to ensure standardization. This classification process may be looked upon as the systematic methodology of describing a fracture or dislocation. It is critical to note that a fracture should be coded only after all the information is obtained. It must be remembered that if there is doubt, then waiting until the complete information is available is mandatory before determining the final classification.^{23–28} The final classification may be delayed until the operative procedure is completed and the fracture fully visualized.

This system provides the clinician with standardized definitions so the verbal fracture description is precise and consistent from bone to bone and fracture to fracture. These standard definitions and guidelines for application assure consistency in the classification process.^{16,24–37} With the improved consistency of fracture descriptions, future investigations assessing treatment guidelines, prognosis, and risk of complications will be more reliable and meaningful. The system also provides a mechanism to convert the verbal description into an alphanumeric code to allow for data storage and future recall. The use of this alphanumeric coding scheme is absolutely necessary for multi-center collaboration, retrospective comparison of results, international communication, and to standardize recording information about all fractures in a trauma database.

The classification offers several other benefits. It provides a hierarchy of severity as the descriptions generally proceed from simple to multifragmentary fractures. This hierarchy is based on the energy of injury or potential complexity of treatment. Ease of use is also an important aspect for a classification. This system allows the clinician to be as general or detailed as necessary according to their clinical or research needs. The classification is logical, comprehensible, and does not contain an unmanageable number of categories, a problem that ensures poor reliability.

Principles of fracture and dislocation classification

The principles of classification² are based on understanding and applying standardized definitions. These definitions are universal and allow consistency in classification and communication. Although clinical decisions are sometimes made on incomplete information, this should be avoided as much as possible when classifying a fracture—the more precise the description the better the data recorded. Attention should be paid to upper-case versus lower-case letters and () versus [] as this will aid in accurate fracture pattern retrieval from databases.

Fracture localization—bones and segments

The bone is identified (**Fig 1**).

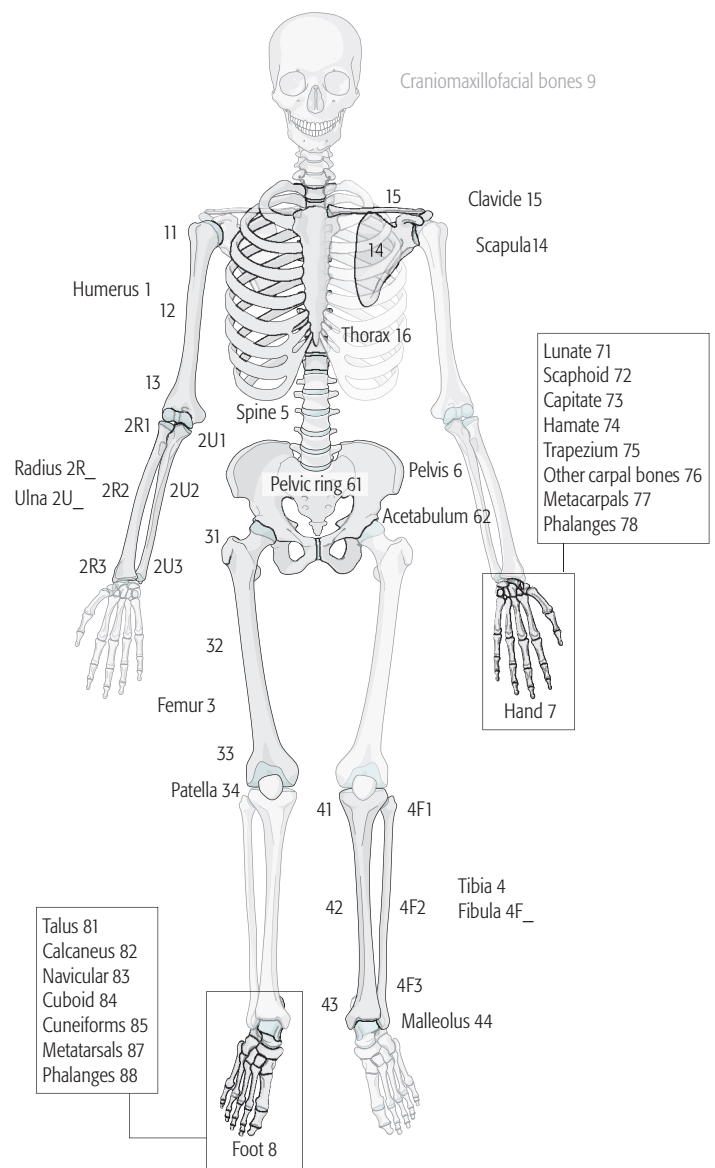


Fig 1 Designation of bone location.

Next, it is necessary to determine where in the bone the fracture is located. This requires precise definitions of the **parts of a bone**. The proximal and distal end segments of the long bones are defined by a square whose sides are the same length as the widest part of the epiphysis/metaphysis in question (Heim's system of squares).^{2,3} Each bone has a proximal and distal end segment, between which the diaphysis or shaft is located. These definitions apply to any bone with articulations at both ends and a segment of cortical bone between the articulations, for example, a femur, or a metacarpal, or a phalanx. With the two bone systems now having separate codes, it was decided to maintain the standard definition of the end segments with bones not separated (**Fig 2**).

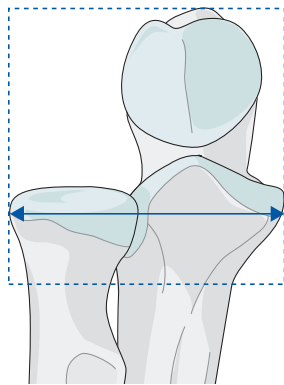


Fig 2 Determine the location of the end segment.

Two exceptions are the proximal femur, defined as being above a line that passes transversely through the inferior edge of the lesser trochanter and the malleolar segment of the distal tibia. The bone segments are numbered as:

- Proximal end segment = 1
- Diaphyseal segment = 2
- Distal end segment = 3

The **location of the fracture** is determined by finding its center. This is defined as follows:

- In a simple fracture, the center of the fracture is obvious (**Fig 3**).
- In a wedge fracture, the center is at the level of the broadest part of the wedge (**Fig 4**).
- In a fragmentary wedge and a multifragmentary fracture, the center can be determined only after reduction (**Fig 4**).
- Any diaphyseal fracture associated with a displaced articular component is considered an articular fracture.
- If a fracture is associated with an undisplaced fissure that reaches the joint, it is classified as a metaphyseal or diaphyseal fracture depending on its center.
- If one bone has two completely separate fractures, one in the diaphysis and one in the proximal or distal end segments (eg, a femoral diaphysis and a femoral neck fracture), each fracture must be classified separately.

Fracture morphology: types, groups, subgroups, qualifications, and universal modifiers

The type (upper-case letter) is a general description of fracture patterns while the group (numerals) is a more specific description based on the individual bone or specific fracture pattern.

The **morphology of the diaphyseal fracture** is defined as:

Simple—Type A fractures have a single circumferential disruption of the diaphysis. An oblique fracture forms an angle $\geq 30^\circ$ to a line perpendicular to the long axis of the bone. (**Fig 3**).

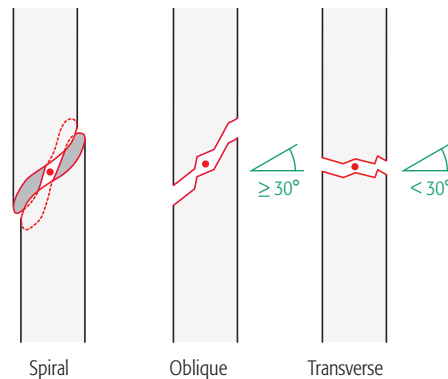


Fig 3 Simple fractures. The dot represents the center of the fracture.

Wedge—Type B fractures are characterized by contact between the main fragments after reduction usually restoring the normal length of the bone. The wedge fragment may be intact, or in multiple fragments (ie, fragmentary wedge). The differentiation between spiral and bending wedge is inconsistent and not easily determined so these terms were moved to the universal modifiers (**Fig 4**).

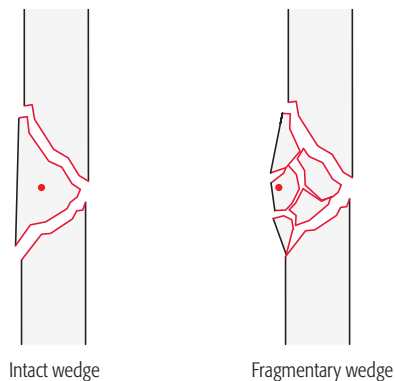


Fig 4 Wedge fractures. The dot represents the center of the fracture.

Multifragmentary—Type C fractures consist of many fracture lines and fracture fragments. These fractures were known as either wedge or complex fractures in the Müller comprehensive classification. “Complex” is a term that caused confusion because it is nonspecific and is replaced in the 2018 version by the term “multifragmentary” meaning many contiguous fracture fragments, and not a wedge fracture.

In the diaphyseal segment, the fractured segment is either intact or in many fragments so that after reduction if the fractured area were removed there would be no contact between the proximal and distal fragments. Fragmentary is used to describe fragmentation of a wedge or segment (**Fig 5**).

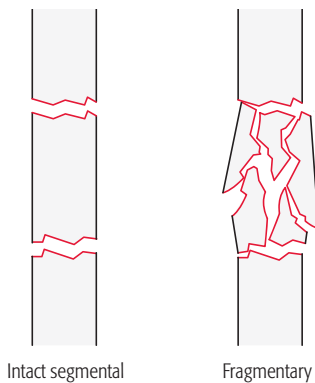


Fig 5 Multifragmentary fractures.

The **morphology for end segment fractures** is based on whether they are extraarticular (no extension into the articular surface) or intraarticular (has an extension into the articular surface).

Extraarticular—Type A: The fracture line may be metaphyseal or epiphyseal, but it always spares the articular surface although it may be intracapsular.

Partial articular—Type B: The fracture involves part of the articular surface while the remainder of the joint remains intact and is solidly connected to the supporting metaphysis and diaphysis.

Complete articular—Type C: There is a disruption of the articular surface and the articular surface is completely separated from the diaphysis.

Further description of fracture morphology at the articular surface or metaphysis use the previously defined terms of simple (single disruption of the joint surface) and multifragmentary (multiple disruptions of the joint surface) patterns. Avulsion fractures are always classified as extraarticular simple fractures (**Fig 6**).

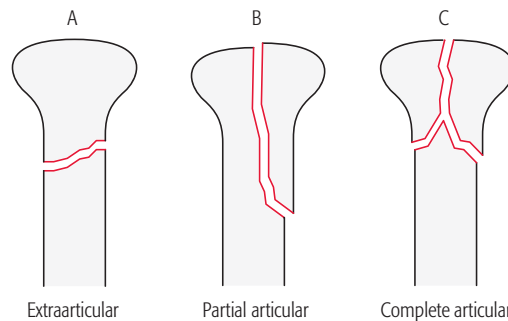


Fig 6 End segments fractures are divided into three types.

Exceptions

The proximal end segment of the humerus and femur are exceptions:

- Simple proximal humeral fractures involving one tuberosity or the metaphysis (unifocal or Neer 2-part fractures) and proximal femoral fractures involving the trochanteric area are type A
- The partial articular type does not exist in the humerus or femur. Proximal humeral fracture involving one tuberosity and the metaphysis (bifocal or Neer 3-part fractures), and the proximal femoral fracture involving the femoral neck are type B.
- Proximal humeral articular fractures involving the anatomical neck of the humerus and fractures involving the femoral head are type C.

The definitions or description of groups and subgroups are fracture specific.

Universal modifiers

The universal modifiers are descriptive terms of fracture morphology, displacement, associated injury, or location that are generalizable to most fractures. They provide detail that are optional for users.

Universal modifiers may be added to the end of the fracture code within square brackets, eg, [1].

Multiple universal modifiers may be contained within the same set of squared brackets and separated by a comma.

Example: A proximal humerus fracture-dislocation with **displacement, anterior dislocation, cartilage injury, and osteopenia** = 11A1.2[2,5a,8e,9]

Example: Humerus, proximal end segment, articular or 4-part fracture, with multifragmentary metaphyseal fracture and articular fracture with an **anterior dislocation** = 11C3.2[5a]

List of universal modifiers

- 1 Nondisplaced**
- 2 Displaced**
- 3 Impaction**
 - 3a Articular
 - 3b Metaphyseal
- 4 No impaction**
- 5 Dislocation**
 - 5a Anterior (volar, palmar, plantar)
 - 5b Posterior (dorsal)
 - 5c Medial (ulnar)
 - 5d Lateral (radial)
 - 5e Inferior (with hip is also obturator)
 - 5f Multidirectional
- 6 Subluxation/ligamentous instability**
 - 6a Anterior (volar, palmar, plantar)
 - 6b Posterior (dorsal)
 - 6c Medial (ulnar)
 - 6d Lateral (radial)
 - 6e Inferior (with hip is also obturator)
 - 6f Multidirectional
- 7 Diaphyseal extension**
- 8 Articular cartilage injury[#]**
 - 8a ICRS Grade 0 Normal
 - 8b ICRS Grade 1 Superficial indentation (A) and /or superficial fissures and cracks (B)
 - 8c ICRS Grade 2 Abnormal lesions extending down to 50% of cartilage depth
 - 8d ICRS Grade 3 (A) Severely abnormal with defects extending down >50% of cartilage depth; (B) down to calcified layer; (C) down to subchondral bone but not through; (D) blisters included
 - 8e ICRS Grade 4 Severely Abnormal Cartilage loss through subchondral bone
- 9 Poor bone quality**
- 10 Replantation**
- 11 Amputation associated with a fracture**
- 12 Associated with a nonarthroplasty implant**
- 13 Spiral type fracture**
- 14 Bending type fracture**

[#]This grading system is used with the permission of the International Cartilage Repair Society.³⁸

Qualifications

The fracture qualifications are descriptive terms of fracture morphology or location that are specific to each fracture.

- All fracture classification qualifications are lower-case letters to differentiate them from the fracture type, which is always an upper-case letter.
- All fracture qualifications are inserted in place of the asterisk in the fracture code as a lower-case letter within a round bracket, eg, (a).
- Where appropriate in the classification sections, the qualification that corresponds to an the image is bolded.

Example: Humerus, proximal end segment, articular or 4-part fracture, with multifragmentary metaphyseal fracture and **simple** articular fracture with an anterior dislocation 11C3.2(x)[5a]

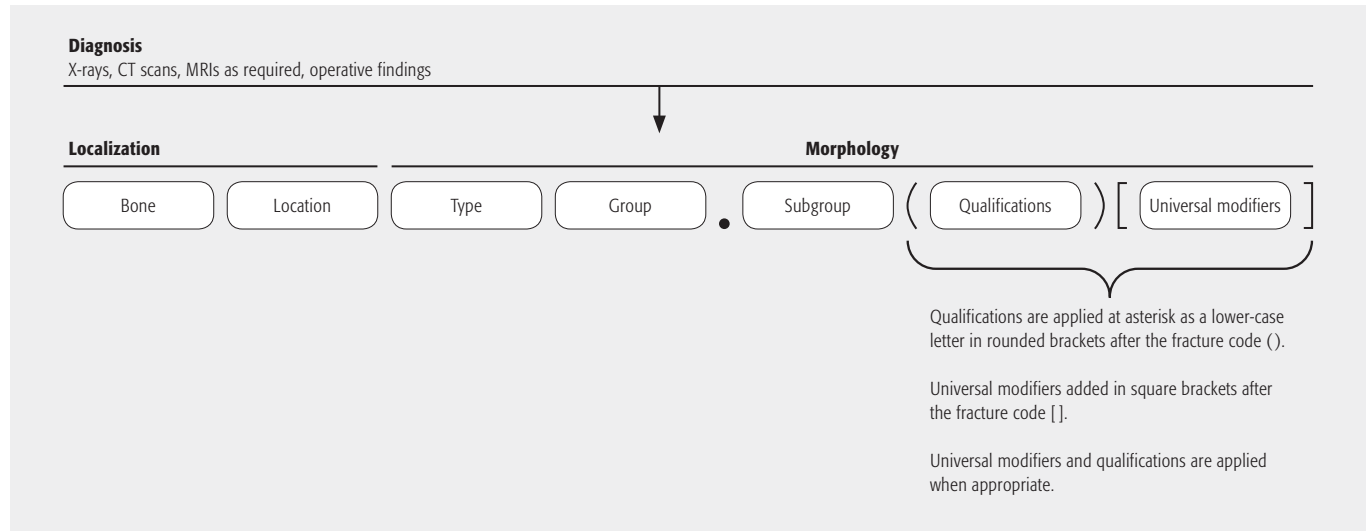
The process of classification and coding a diaphyseal fracture

Step	Question	Answer
1	What is the bone?	Specific bone (see Fig 1 for bone number)
2	Is the fracture at the end or middle segment?	Middle—diaphyseal segment (2)
3	What is the type?	Simple (A), wedge (B), multifragmentary (C)
4a	Group: If simple (A): What is the fracture pattern (group)?	Spiral (1), oblique (2), transverse (3)
4b	Group: If wedge (B): What is the fracture pattern (group)?	Intact (2) or fragmentary (3)
4c	Group: If multifragmentary (C): What is the fracture pattern (group)?	Intact segmental (2) or fragmentary segmental (3)
5	Add qualifications and/or universal modifiers	

The process of classification and coding an end-segment fracture

Step	Question	Answer
1	What is the bone?	Specific bone (see Fig 1 for bone number)
2	At which end is the fracture located?	Proximal (1) or distal (3)
3	Type: Does the fracture enter the joint surface (type)?	No—extraarticular (A), go to 5 Yes—articular (B or C), go to 4(a,b)
4a	Type: If articular, is it partial (part of joint attached to metaphysis)?	Yes (type B), go to 6
4b	Type: If articular, is it complete (no part of joint attached to metaphysis)?	Yes (type C), go to 7
5	Group: If extraarticular (A) what is the fracture pattern?	Avulsion (1), simple (2), wedge or multifragmentary (3)
6	Group: If partial articular (B) what is the fracture pattern?	Simple (1), split and/or depression (2), fragmentary (3)
7	Group: If complete articular (C) what is the articular fracture pattern?	Simple (1), multifragmentary (2)
8	Subgroup: If complete articular (C) what is the metaphyseal fracture pattern?	Simple articular with simple metaphyseal (1), simple articular fracture with multifragmentary metaphyseal (2), multifragmentary articular with multifragmentary metaphyseal (3)
9	Add qualifications and/or universal modifiers	

Alphanumeric structure of the AO/OTA classification



Summary

Since the original publication of the AO/OTA Fracture Classification in the 1996 Journal of Orthopaedic Trauma Compendium, there has been important progress in fracture classification toward the goal of a universally accepted comprehensive fracture language. The 21 years of use of the AO/OTA compendium has demonstrated its strengths and shortcomings. Although admirable, the process of classification validation has been time consuming and expensive and generally not practical in a retrospective manner for accepted classifications. With the increased use of validated patient outcomes, a standardized comprehensive classification of injury is necessary. The AOTIB and OTA Classification Committee through the International Comprehensive Classification of Fractures and Dislocations Committee realized the need to make the compendium as comprehensive and standardized as possible. This third compendium addresses many of the prior criticisms

as well as updating the prior editions and adding new published classifications. These changes in content and presentation should make the compendium more universal and simpler to use. These standardized classification systems should make injury description more standardized and so improve research and fracture outcomes assessments.

The collaboration of the AOTIB and the OTA through their classification committees has resulted in the return of the compendium copyright to both organizations so it is available for any clinician to use without charge. This collaboration has allowed its worldwide dissemination. The organizations are committed to working together to continually evaluate the compendium and revise as necessary.

Acknowledgments

The committee would like to acknowledge and gratefully thank Jessica Schisel, Jecca Reichmuth, Marcel Erismann, and Kathleen Caswell, all the staff of the OTA office, and the AO Education Institute for their tremendous support and encouragement.

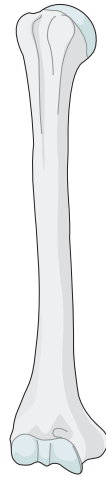
The committee would also like to acknowledge the important contributions to the prior compendiums from Larry Marsh, MD, Theddy Slongo MD, and Laurent Audige PhD.

References

1. **Association Committee for Coding and Classification.** Fracture and dislocation compendium. *J Orthop Trauma.* 1996;10 Suppl 1:v-ix, 1–154.
2. **Müller ME, Nazarian S, Koch P.** *Classification AO des fractures.* Tome I. Les os longs. 1st Ed. Berlin: Springer-Verlag; 1987.
3. **Müller ME, Nazarian S, Koch P, et al.** *The Comprehensive Classification of Fractures of Long Bones.* Berlin, Germany:Springer-Verlag;1990.
4. **Slongo T, Audigé L, Clavert JM, et al.** The AO comprehensive classification of pediatric long-bone fractures: a web-based multicenter agreement study. *J Pediatr Orthop.* 2007;27:171–180.
5. **Slongo T, Audigé L, Lutz N, et al.** Documentation of fracture severity with the AO classification of pediatric long-bone fractures. *Acta Orthop.* 2007;78:247–253.
6. *Webster's New Riverside University Dictionary.* Boston, MA: Riverside Publishing; 1984:268.
7. **Martin JS, Marsh JL.** Current classification of fractures. Rationale and utility. *Radiol Clin North Am.* 1997;35:491–506.
8. **Brumback RJ, Jones AL.** Interobserver agreement in the classification of open fractures of the tibia. The results of a survey of two hundred and forty-five orthopaedic surgeons. *J Bone Joint Surg Am.* 1994;76:1162–1166.
9. **Schatzker J, McBroom R, Bruce D.** The tibial plateau fracture. The Toronto experience 1968–1975. *Clin Orthop Relat Res.* 1979;138:94–104.
10. **Siebenrock KA, Gerber C.** The reproducibility of classification of fractures of the proximal end of the humerus. *J Bone Joint Surg Am.* 1993;75:1751–1755.
11. **Martin JS, Marsh JL, Bonar SK, et al.** Assessment of the AO/ASIF fracture classification for the distal tibia. *J Orthop Trauma.* 1997;11:477–483.
12. **Sidor ML, Zuckerman JD, Lyon T, et al.** The Neer classification system for proximal humeral fractures. An assessment of interobserver reliability and intraobserver reproducibility. *J Bone Joint Surg Am.* 1993;75:1745–1750.
13. *ICD-10-CM Expert for Physicians: The complete official code set.* Optum360, LLC; 2015.
14. **Luo CF, Sun H, Zhang B, et al.** Three-column fixation for complex tibial plateau fractures. *J Orthop Trauma.* 2010 Nov;24(11):683–692.
15. **Parsons BO, Klepps SJ, Miller S, et al.** Reliability and reproducibility of radiographs of greater tuberosity displacement. A cadaveric study. *J Bone Joint Surg Am.* 2005;87:58–65.
16. **Crist BD, Martin SL, Stannard JP.** Tibial Plateau Fractures. In: Stannard JP, Schmidt AH, eds. *Surgical Treatment of Orthopaedic Trauma—Second edition.* New York: Thieme; 2016:913–945.
17. **Evans AR, Agel J, DeSilva GL, et al. Orthopaedic Trauma Association: Open fracture study group.** A new classification scheme for open fractures. *J Orthop Trauma.* 2010 Aug;24(8):457–464.
18. **Audigé L, Kellam JF, Lambert S, et al.** The AO Foundation and Orthopaedic Trauma Association (AO/OTA) scapula fracture classification system: focus on body involvement. *J Shoulder Elbow Surg.* 2014 Feb;23(2):189–196.
19. **Jaeger M, Lambert S, Sudkamp NP, et al.** The AO Foundation and Orthopaedic Trauma Association (AO/OTA) scapula fracture classification system: focus on glenoid fossa involvement. *J Shoulder Elbow Surg.* 2013 Apr;22(4):512–520.
20. **Dunan CP, Haddad FS.** The Unified Classification System (UCS): improving our understanding of periprosthetic fractures. *Bone Joint J.* 2014 Jun;96-b(6):713–716.
21. **Vaccaro AR, Schroeder GD, Kepler CK, et al.** The surgical algorithm for the AOSpine thoracolumbar spine injury classification system. *Eur Spine J.* 2016 Apr;25(4):1087–1094.
22. **Bellabartba C, Schroeder G, Kepler C, et al.** The AOSpine Sacral Fracture Classification. *Global Spine J.* 06(S 01). 2016 April DOI: 10.1055/s-0036-1582696.
23. **Kristiansen B, Andersen UL, Olsen CA, et al.** The Neer classification of fractures of the proximal humerus. An assessment of interobserver variation. *Skeletal Radiol.* 1988;17(6):420–422.
24. **Bernstein J, Adler LM, Blank JE, et al.** Evaluation of the Neer system of classification of proximal humeral fractures with computerized tomographic scans and plain radiographs. *J Bone Joint Surg Am.* 1996;78:1371–1375.
25. **Flikkilä T, Nikkola-Sihto A, Kaarela O, et al.** Poor interobserver reliability of AO classification of fractures of the distal radius. Additional computed tomography is of minor value. *J Bone Joint Surg Br.* 1998;80:670–672.
26. **Humphrey CA, Dirschl DR, Ellis TJ.** Interobserver reliability of a CTbased fracture classification system. *J Orthop Trauma.* 2005;19:616–622.
27. **Barker L, Anderson J, Chesnut R, et al.** Reliability and reproducibility of dens fracture classification with use of plain radiography and reformatted computer-aided tomography. *J Bone Joint Surg Am.* 2006;88:106–112.
28. **Dirschl DR, Adams GL.** A critical assessment of factors influencing reliability in the classification of fractures, using fractures of the tibial plafond as a model. *J Orthop Trauma.* 1997;11 :471–476.
29. **Petrisor BA, Bhandari M, Orr RD, et al.** Improving reliability in the classification of fractures of the acetabulum. *Arch Orthop Trauma Surg.* 2003;123:228–233.
30. **Schipper IB, Steyerberg EW, Castelein RM, et al.** Reliability of the AO/ASIF classification for petrochanteric femoral fractures. *Acta Orthop Scand.* 2001;72:36–41.
31. **Walton NP, Harish S, Roberts C, et al.** AO or Schatzker? How reliable is classification of tibial plateau fractures? *Arch Orthop Trauma Surg.* 2003;123:396–398.
32. **Andersen DJ, Blair WF, Steyers CM, Jr, et al.** Classification of distal radius fractures: an analysis of interobserver reliability and intraobserver reproducibility. *J Hand Surg Am.* 1996 Jul;21(4):574–582.
33. **Swiontkowski MF, Sands AK, Agel J, et al.** Interobserver variation in the AO/OTA fracture classification system for pilon fractures: is there a problem? *J Orthop Trauma.* 1997;11:467–470.
34. **Kreder HJ, Hanel DP, McKee M, et al.** Consistency of AO fracture classification for the distal radius. *J Bone Joint Surg Br.* 1996;78:726–731.
35. **Oskam J, Kingma J, Klasen HJ.** Interrater reliability for the basic categories of the AO/ASIF's system as a frame of reference for classifying distal radial fractures. *Percept Mot Skills.* 2001;92:589–594.
36. **Audigé L, Bhandari M, Kellam J.** How reliable are reliability studies of fracture classifications? A systematic review of their methodologies. *Acta Orthop Scand.* 2004;75:184–194.
37. **Audigé L, Bhandari M, Hanson B, et al.** A concept for the validation of fracture classifications. *J Orthop Trauma.* 2005;19:401–406.
38. **International Cartilage Repair Society.** ICRS SCORE/GRADE: ICRS Clinical Cartilage Injury Evaluation System. Available at: <http://cartilage.org/society/publications/icrs-score/>

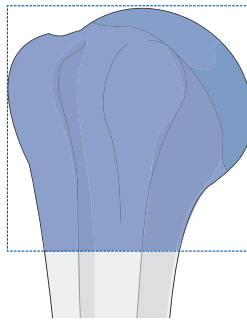
Humerus

Bone: Humerus 1



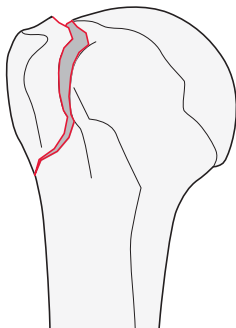
11

Location: Humerus, proximal end segment 11

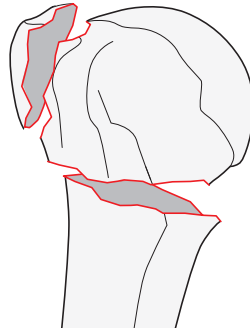


Types:

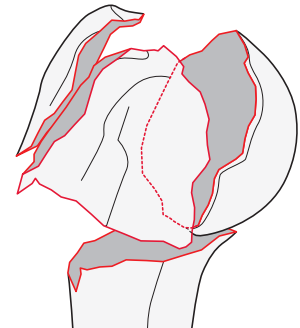
Humerus, proximal end segment,
extraarticular, unifocal, 2-part fracture
11A



Humerus, proximal end segment,
extraarticular, bifocal, 3-part fracture
11B



Humerus, proximal end segment,
articular or 4-part fracture
11C



Qualifications are optional and applied to the fracture code where the asterisk is located as a lower-case letter within rounded brackets. More than one qualification can be applied for a given fracture classification, separated by a comma. For a more detailed explanation, see the compendium introduction.

11A

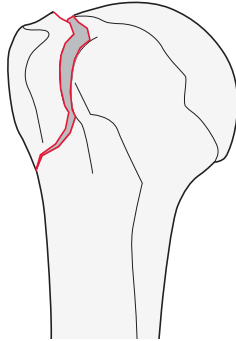
Type: Humerus, proximal end segment, **extraarticular, unifocal, 2-part fracture** 11A

Group: Humerus, proximal end segment, extraarticular, unifocal, 2-part, **tuberosity fracture** 11A1

Subgroups:

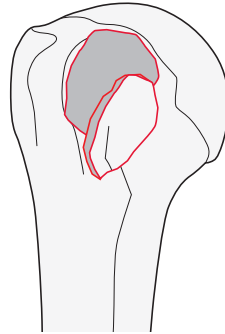
Greater tuberosity fracture

11A1.1



Lesser tuberosity fracture

11A1.2

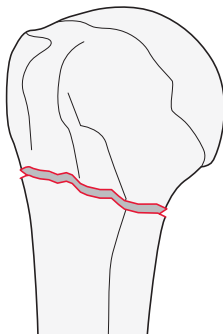


Group: Humerus, proximal end segment, extraarticular, unifocal, 2-part, **surgical neck fracture** 11A2

Subgroups:

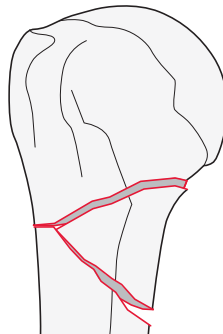
Simple fracture

11A2.1



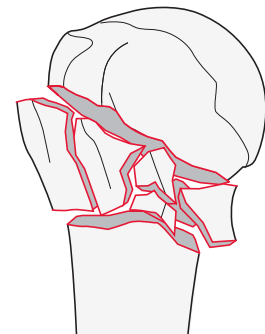
Wedge fracture

11A2.2

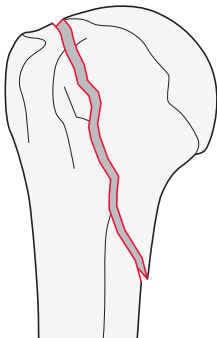


Multifragmentary fracture

11A2.3



Group: Humerus, proximal end segment, unifocal, 2-part, **extraarticular vertical fracture** 11A3



11B

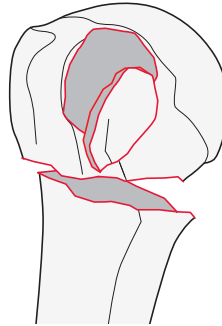
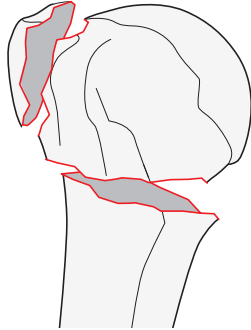
Type: Humerus, proximal end segment, **extraarticular, bifocal, 3-part fracture** 11B

Group: Humerus, proximal end segment, extraarticular, bifocal, 3-part, **surgical neck fracture** 11B1

Subgroups:

With greater tuberosity fracture
11B1.1*

With lesser tuberosity fracture
11B1.2*



*Qualifications:
u Intact wedge
v Fragmentary wedge

11C

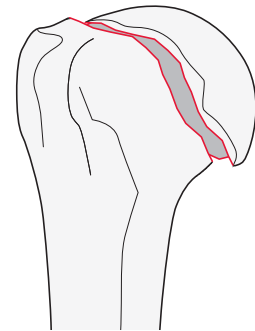
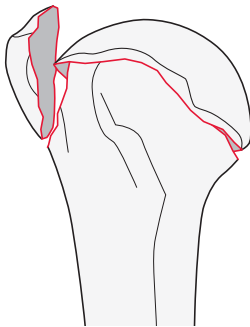
Type: Humerus, proximal end segment, **articular or 4-part fracture** 11C

Group: Humerus, proximal end segment, articular or 4-part, **anatomical neck fracture** 11C1

Subgroups:

Valgus impacted fracture
11C1.1*

Isolated anatomical neck fracture
11C1.3

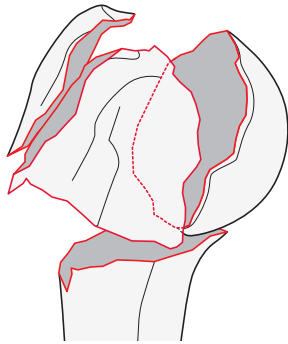


*Qualifications:
n **Greater tuberosity**
o Lesser tuberosity
p Both tuberosities

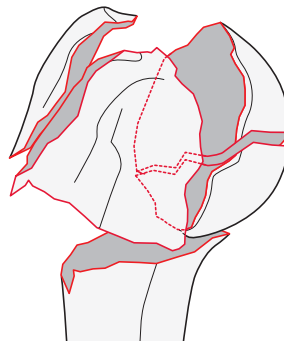
Group: Humerus, proximal end segment, articular or 4-part, **anatomical neck fracture associated with metaphyseal fracture** 11C3

Subgroups:

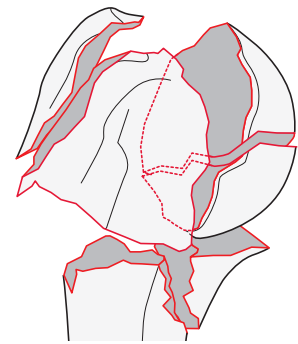
With a multifragmentary metaphyseal segment with intact articular surface
11C3.1



With a multifragmentary metaphyseal segment with articular fracture
11C3.2*



With a multifragmentary metaphyseal fracture, with diaphyseal extension and articular fracture
11C3.3*

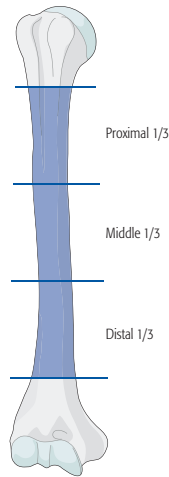


*Qualifications:

- x **Simple articular**
- y Multifragmentary articular

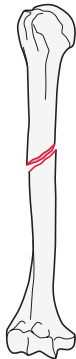12

Location: Humerus, **diaphyseal segment** 12

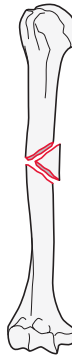


Types:

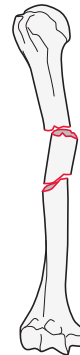
Humerus, diaphyseal segment, **simple fracture**
12A



Humerus, diaphyseal segment, **wedge fracture**
12B



Humerus, diaphyseal segment, **multifragmentary fracture**
12C

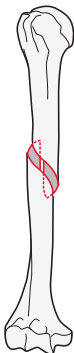


12A

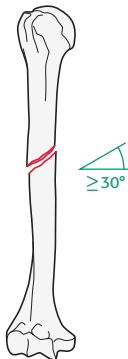
Type: Humerus, diaphyseal segment, **simple fracture** 12A

Groups:

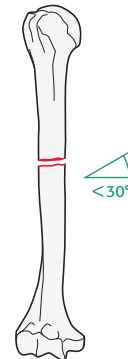
Humerus, diaphyseal segment, simple, **spiral fracture**
12A1*



Humerus, diaphyseal segment, simple, **oblique fracture ($\geq 30^\circ$)**
12A2*



Humerus, diaphyseal segment, simple, **transverse fracture ($< 30^\circ$)**
12A3*



*Qualifications:

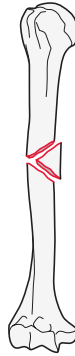
- a Proximal 1/3
- b **Middle 1/3**
- c Distal 1/3

12B

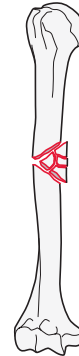
Type: Humerus, diaphyseal segment, **wedge fracture** 12B

Groups:

Humerus, diaphyseal segment,
intact wedge fracture
12B2*



Humerus, diaphyseal segment,
fragmentary wedge fracture
12B3*



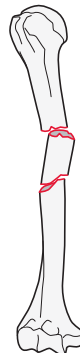
*Qualifications:
a Proximal 1/3
b **Middle 1/3**
c Distal 1/3

12C

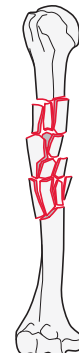Type: Humerus, diaphyseal segment, **multifragmentary fracture** 12C

Groups:

Humerus, diaphyseal segment, multifragmentary,
intact segmental fracture
12C2*



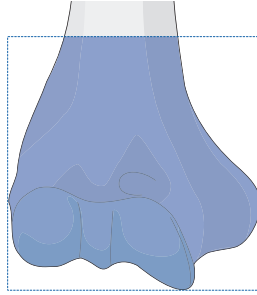
Humerus, diaphyseal segment, multifragmentary,
fragmentary segmental fracture
12C3*



*Qualifications:
i Proximal diaphyseal-metaphyseal
j **Pure diaphyseal**
k Distal diaphyseal-metaphyseal

13

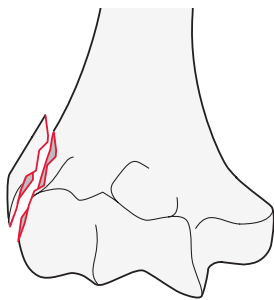
Location: Humerus, **distal end segment** 13



Types:

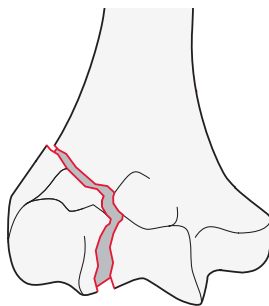
Humerus, distal end segment,
extraarticular fracture

13A



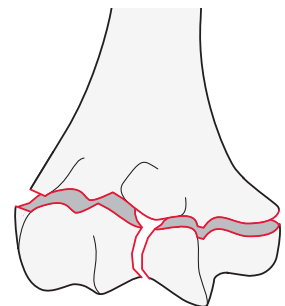
Humerus, distal end segment,
partial articular fracture

13B



Humerus, distal end segment,
complete articular fracture

13C



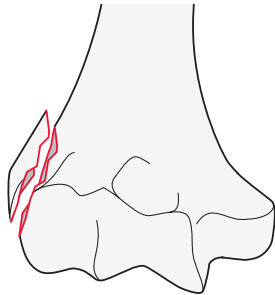
13A

Type: Humerus, distal end segment, **extraarticular fracture** 13A

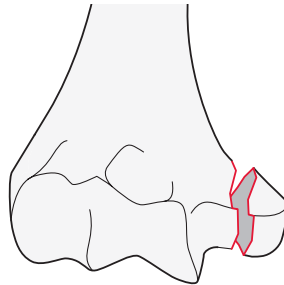
Group: Humerus, distal end segment, extraarticular, **avulsion fracture** 13A1

Subgroups:

Lateral epicondyle fracture
13A1.1



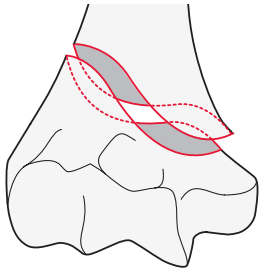
Medial epicondyle fracture
13A1.2



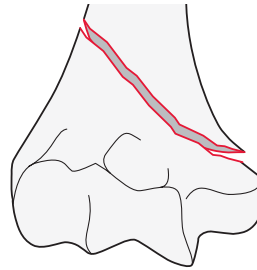
Group: Humerus, distal end segment, extraarticular, **simple fracture** 13A2

Subgroups:

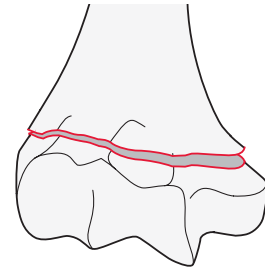
Spiral fracture
13A2.1



Oblique fracture
13A2.2



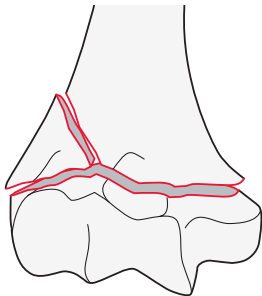
Transverse fracture
13A2.3



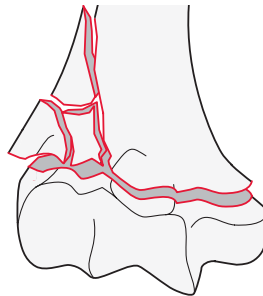
Group: Humerus, distal end segment, extraarticular, **wedge or multifragmentary fracture** 13A3

Subgroups:

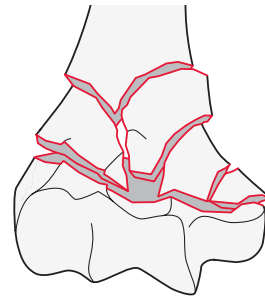
Intact wedge fracture
13A3.1*



Fragmentary wedge fracture
13A3.2*



Multifragmentary fracture
13A3.3



*Qualifications:
f Lateral
h Medial

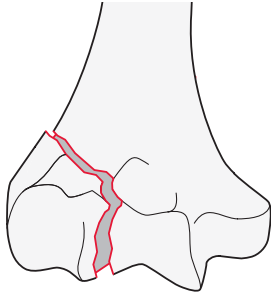
13B

Type: Humerus, distal end segment, **partial articular fracture** 13B

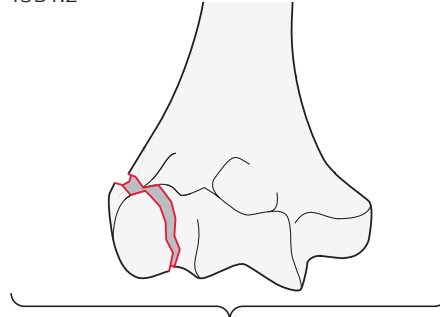
Group: Humerus, distal end segment, partial articular, **lateral sagittal fracture** 13B1

Subgroups:

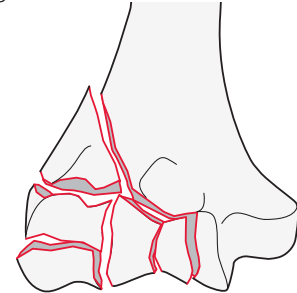
Simple transtrochlear fracture
13B1.1



Capitellum fracture
13B1.2*



Fragmentary transtrochlear fracture
13B1.3



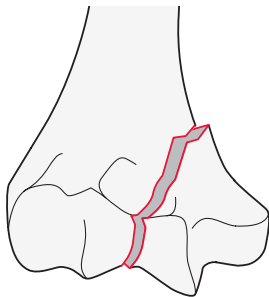
*Qualifications:

- q **Transcapitellar**
- r Between capitellum and trochlea

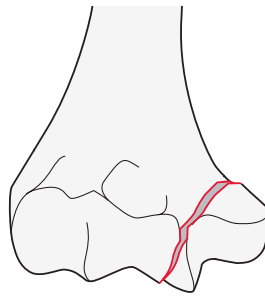
Group: Humerus, distal end segment, partial articular, **medial sagittal fracture** 13B2

Subgroups:

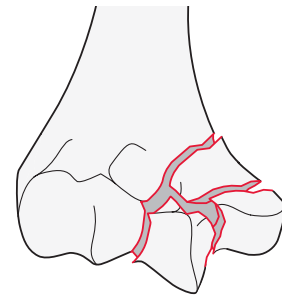
Simple transtrochlear fracture through the trochlear groove
13B2.1



Simple transtrochlear fracture through the medial articular surface
13B2.2



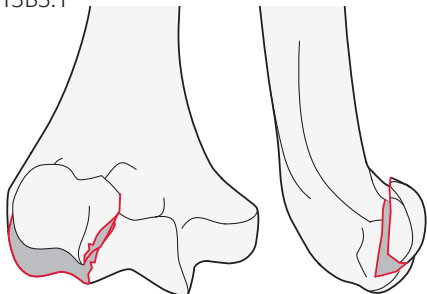
Fragmentary transtrochlear fracture
13B2.3



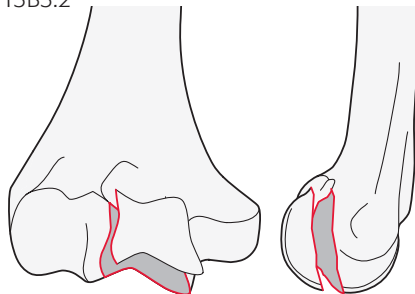
Group: Humerus, distal end segment, partial articular, **frontal/coronal plane fracture** 13B3

Subgroups:

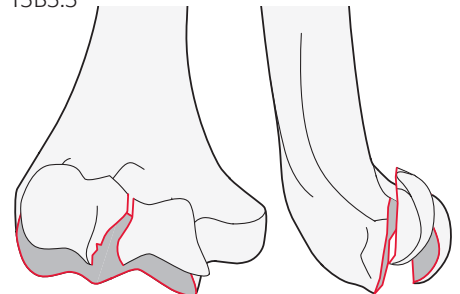
Capitellum fracture
13B3.1



Trochlea fracture
13B3.2



Capitellum and trochlea fracture
13B3.3

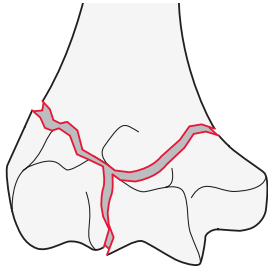


13C

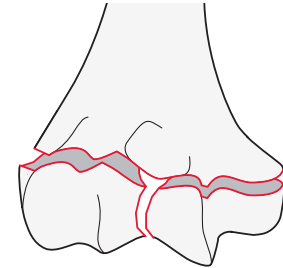
Type: Humerus, distal end segment, **complete articular fracture** 13C

Group: Humerus, distal end segment, complete, **simple articular, simple metaphyseal fracture** 13C1

Subgroups:
Above the transcondylar axis
13C1.1

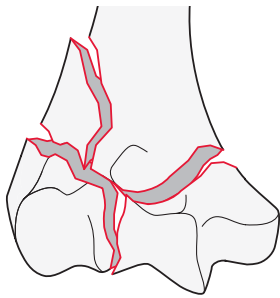


Through or below the transcondylar axis
13C1.3

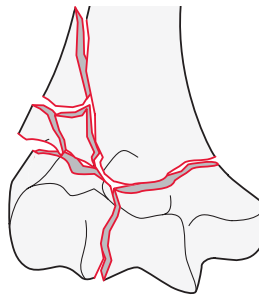


Group: Humerus, distal end segment, complete, **simple articular, wedge or multifragmentary metaphyseal fracture** 13C2

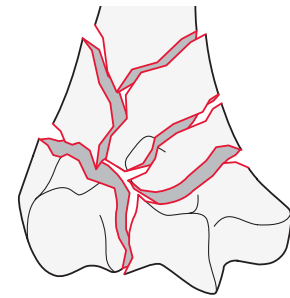
Subgroups:
Intact wedge fracture
13C2.1*



Fragmentary wedge fracture
13C2.2*



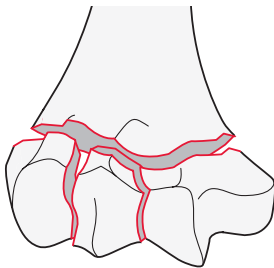
Multifragmentary fracture
13C2.3



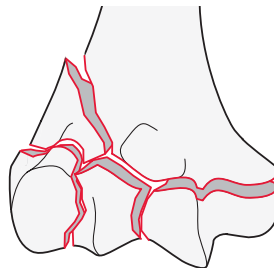
*Qualifications:
f **Lateral**
h Medial
u **Intact wedge**

Group: Humerus, distal end segment, complete, **multifragmentary articular fracture, wedge or multifragmentary metaphyseal fracture** 13C3

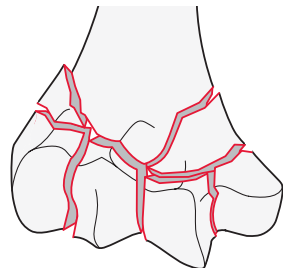
Subgroups:
Simple metaphyseal fracture
13C3.1*



Wedge metaphyseal fracture
13C3.2*



Multifragmentary metaphyseal fracture
13C3.3



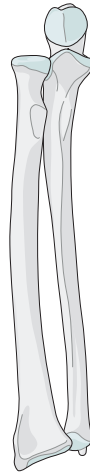
*Qualifications:
s **Proximal to transcondylar axis**
t Distal to transcondylar axis

*Qualifications:
f **Lateral** | Fragmentary
h Medial | u **Intact wedge**

Qualifications are optional and applied to the fracture code where the asterisk is located as a lower-case letter within rounded brackets. More than one qualification can be applied for a given fracture classification, separated by a comma. For a more detailed explanation, see the compendium introduction.

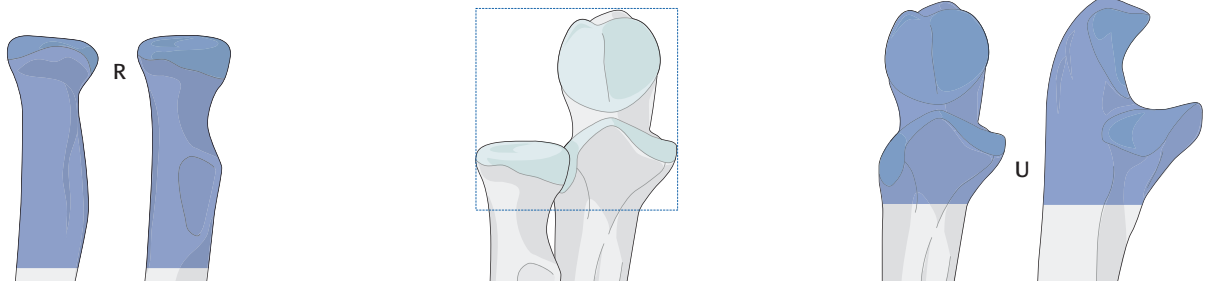
Radius and Ulna

Bone: Radius 2R/Ulna 2U



2R1/2U1

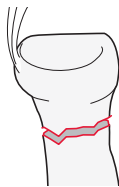
Location: Radius or Ulna, **proximal end segment** 2R1/2U1



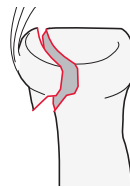
→ To facilitate the coding of radius and ulna fractures, they are now coded independently.
 → The end segment location of either bone is determined by using the two bones as a unit.

Types:

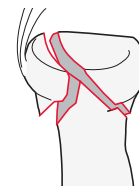
Radius, proximal end segment,
extraarticular fracture
 2R1A



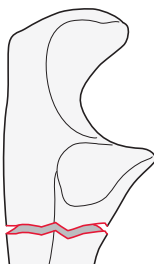
Radius, proximal end segment,
partial articular fracture
 2R1B



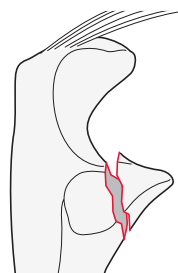
Radius, proximal end segment,
complete articular fracture
 2R1C



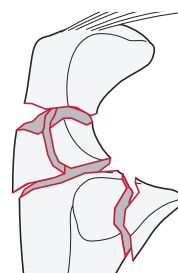
Ulna, proximal end segment,
extraarticular fracture
 2U1A



Ulna, proximal end segment,
partial articular fracture
 2U1B



Ulna, proximal end segment,
complete articular fracture
 2U1C



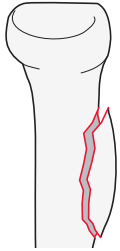
Qualifications are optional and applied to the fracture code where the asterisk is located as a lower-case letter within rounded brackets. More than one qualification can be applied for a given fracture classification, separated by a comma. For a more detailed explanation, see the compendium introduction.

2R1A/2U1A

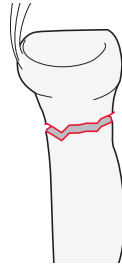
Type: Radius, proximal end segment, **extraarticular fracture** 2R1A

Groups:

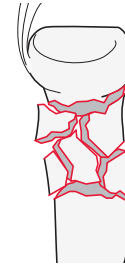Radius, proximal end segment, extraarticular, **avulsion of bicipital tuberosity**
2R1A1



Radius, proximal end segment, extraarticular, **neck, simple**
2R1A2



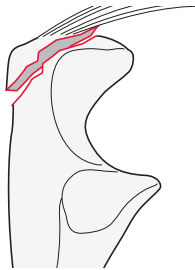
Radius, proximal end segment, extraarticular, **neck, multifragmentary**
2R1A3



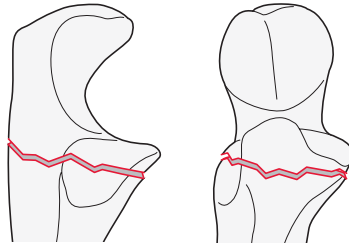
Type: Ulna, proximal end segment, **extraarticular fracture** 2U1A

Groups:

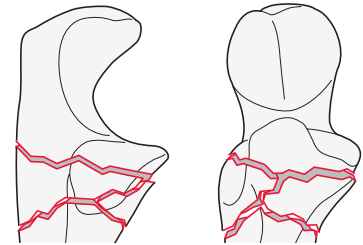
Ulna, proximal end segment, extraarticular, **avulsion of triceps insertion**
2U1A1



Ulna, proximal end segment, extraarticular, **metaphyseal simple fracture**
2U1A2



Ulna, proximal end segment, extraarticular, **metaphyseal multifragmentary fracture**
2U1A3

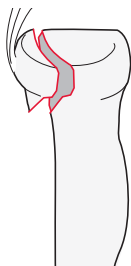


2R1B/2U1B

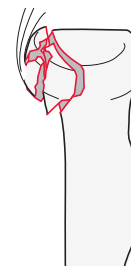Type: Radius, proximal end segment articular, **partial articular fracture** 2R1B

Groups:

Radius, proximal end segment articular, partial articular, **simple fracture**
2R1B1



Radius, proximal end segment articular, partial articular, **fragmentary fracture**
2R1B3

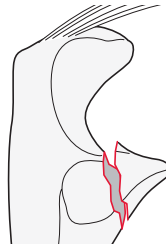
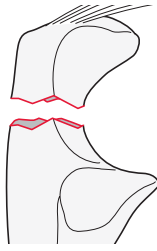


Type: Ulna, proximal end segment, **partial articular fracture** 2U1B

Groups:

Ulna, proximal end segment, partial articular, **olecranon fracture** 2U1B1*

Ulna, proximal end segment, partial articular, **coronoid fracture** 2U1B2*



*Qualifications:
d **Simple**
e Multifragmentary

*Qualifications:
n Involving sublime facet
o Tip (avulsion)
p **<50%**
q **≥50%**

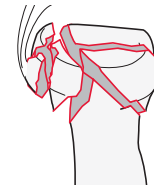
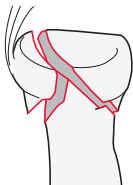
2R1C/2U1C

Type: Radius, proximal end segment articular, **complete articular fracture** 2R1C*

Groups:

Radius, proximal end segment articular, complete articular, **simple fracture** 2R1C1

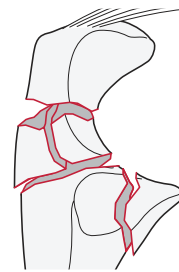
Radius, proximal end segment articular, complete articular, **multifragmentary fracture** 2R1C3



Type: Ulna, proximal end segment, **complete articular fracture** 2U1C

Groups:

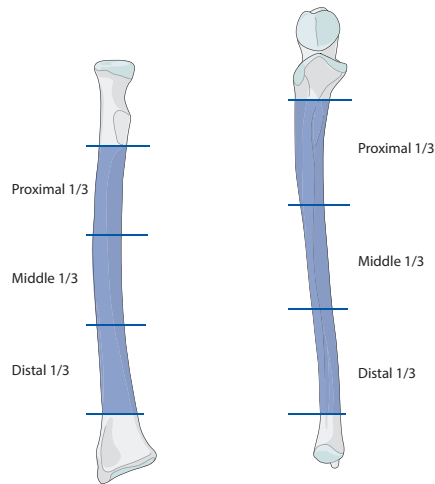
Ulna, proximal end segment, complete articular, **olecranon and coronoid fracture** 2U1C3*



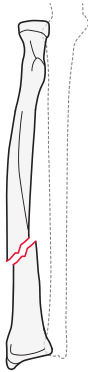
*Qualifications:
d Simple
r Multifragmentary olecranon
s **Multifragmentary involving coronoid process**

2R2/2U2

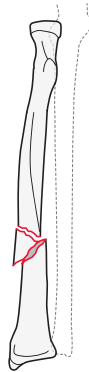
Location: Radius or ulna,
diaphyseal segment 2R2/2U2



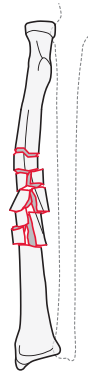
Types:
Radius, diaphyseal segment,
simple fracture
2R2A



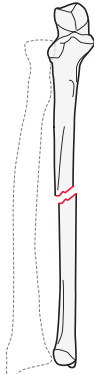
Radius, diaphyseal segment,
wedge fracture
2R2B



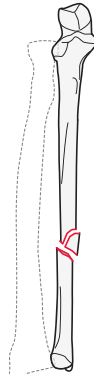
Radius, diaphyseal segment,
multifragmentary fracture
2R2C



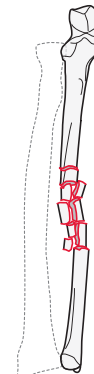
Ulna, diaphyseal segment,
simple fracture
2U2A



Ulna, diaphyseal segment,
wedge fracture
2U2B



Ulna, diaphyseal segment,
multifragmentary fracture
2U2C

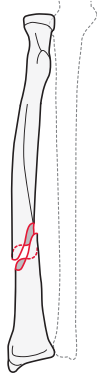


2R2A/2U2A

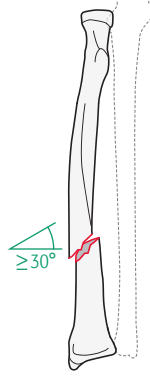
Type: Radius or ulna, diaphyseal segment, **simple fracture** 2R2A/2U2A

Groups:

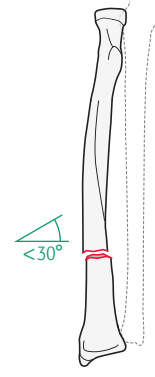
Radius, diaphyseal segment, simple, **spiral fracture**
2R2A1*



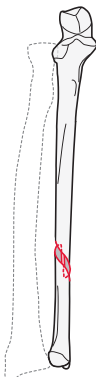
Radius, diaphyseal segment, simple, **oblique fracture ($\geq 30^\circ$)**
2R2A2*



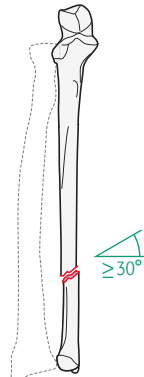
Radius, diaphyseal segment, simple, **transverse fracture ($< 30^\circ$)**
2R2A3*



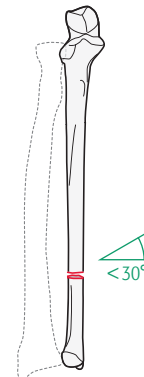
Ulna, diaphyseal segment, simple, **spiral fracture**
2U2A1*



Ulna, diaphyseal segment, simple, **oblique fracture ($\geq 30^\circ$)**
2U2A2*



Ulna, diaphyseal segment, simple, **transverse fracture ($< 30^\circ$)**
2U2A3*



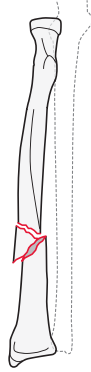
*Qualifications for radius and ulna:
a Proximal 1/3
b Middle 1/3
c **Distal 1/3**

2R2B/ 2U2B

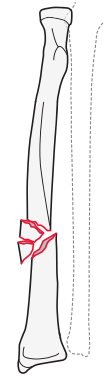
Type: Radius or ulna, diaphyseal segment, **wedge fracture** 2R2B/2U2B

Groups:

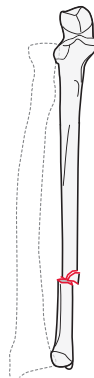
Radius, diaphyseal segment,
intact wedge fracture
2R2B2*



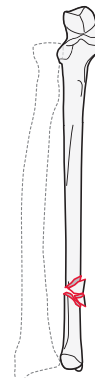
Radius, diaphyseal segment,
fragmentary wedge fracture
2R2B3*



Ulna, diaphyseal segment,
intact wedge fracture
2U2B2*



Ulna, diaphyseal segment,
fragmentary wedge fracture
2U2B3*



*Qualifications for radius and ulna:

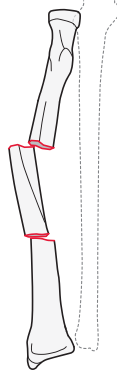
- a Proximal 1/3
- b Middle 1/3
- c **Distal 1/3**

2R2C/2U2C

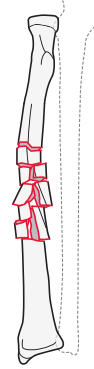
Type: Radius or ulna, diaphyseal segment, **multifragmentary fracture** 2R2C/2U2C

Groups:

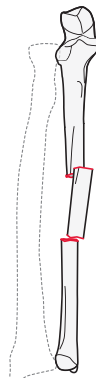
Radius, diaphyseal segment, multifragmentary, **intact segmental fracture**
2R2C2*



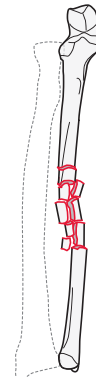
Radius, diaphyseal segment, multifragmentary, **fragmentary segmental fracture**
2R2C3*



Ulna, diaphyseal segment, multifragmentary, **intact segmental fracture**
2U2C2*



Ulna, diaphyseal segment, multifragmentary, **fragmentary segmental fracture**
2U2C3*



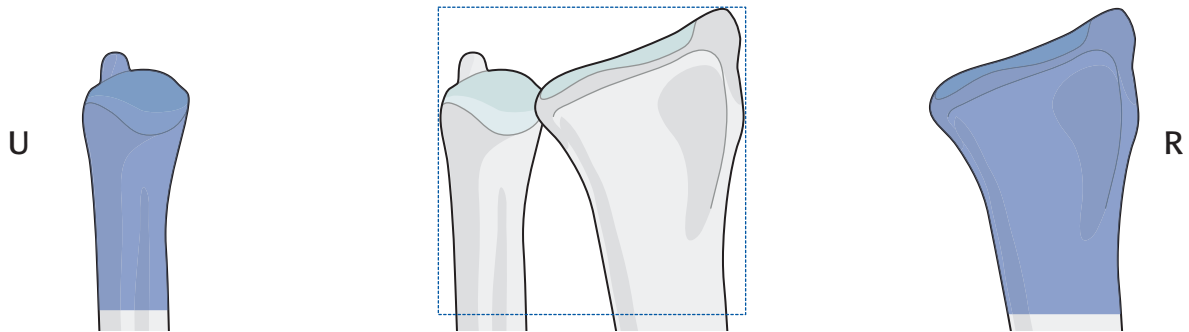
*Qualifications for radius and ulna:
i Proximal diaphyseal-metaphyseal
j **Pure diaphyseal**
k Distal diaphyseal-metaphyseal

→ **Galeazzi** and **Monteggia** fracture patterns can be coded as follows:

The code for the fracture pattern is the radius or ulna fracture code with qualifier of (g) for Galeazzi or (m) for Monteggia representing disruption of the radio-ulnar joint. For more information about Galeazzi and Monteggia fractures, please refer to the Appendix.

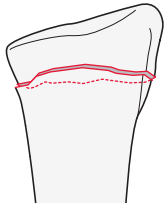
2R3/2U3

Location: Radius/Ulna, **distal end segment** 2R3/2U3

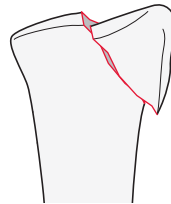


Types:

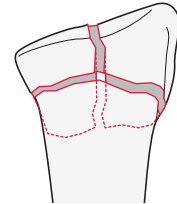
Radius, distal end segment,
extraarticular fracture
2R3A



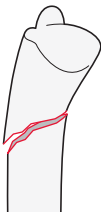
Radius, distal end segment,
partial articular fracture
2R3B



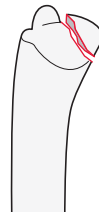
Radius, distal end segment,
complete articular fracture
2R3C



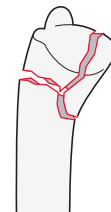
Ulna, distal end segment,
extraarticular fracture
2U3A



Ulna, distal end segment,
partial articular fracture
2U3B



Ulna, distal end segment,
complete articular fracture
2U3C

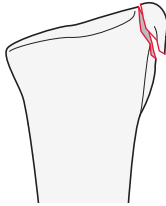


2R3A

Type: Radius, distal end segment, **extraarticular fracture** 2R3A

Group:

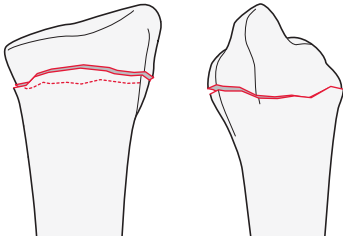
Radius, distal end segment, extraarticular,
radial styloid avulsion fracture
2R3A1



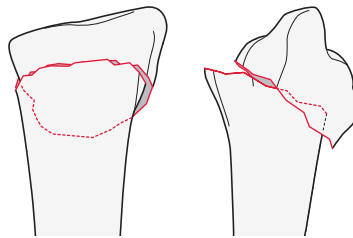
Group: Radius, distal end segment, extraarticular, **simple fracture** 2R3A2

Subgroups:

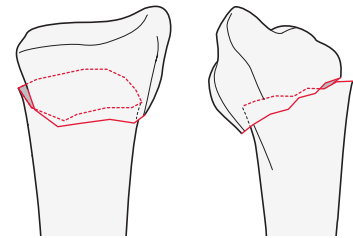
Transverse, no displacement/tilt
(may be shortened)
2R3A2.1



Dorsal displacement/tilt (Colles)
2R3A2.2



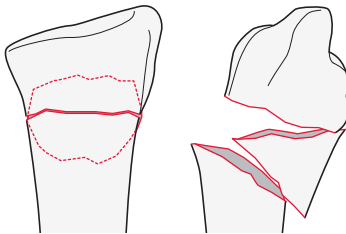
Volar displacement/tilt (Smith's)
2R3A2.3



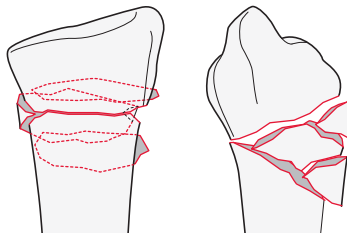
Group: Radius, distal end segment, extraarticular, **wedge or multifragmentary fracture** 2R3A3

Subgroups:

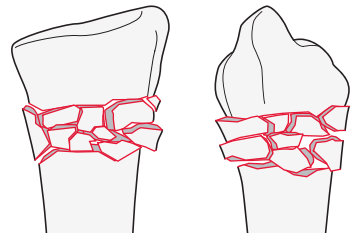
Intact wedge fracture
2R3A3.1



Fragmentary wedge fracture
2R3A3.2



Multifragmentary fracture
2R3A3.3



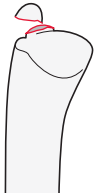2U3A

Type: Ulna, distal end segment, **extraarticular fracture** 2U3A

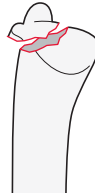Group: Ulna, distal end segment, **extraarticular, styloid process fracture** 2U3A1

Subgroups:

Tip of styloid fracture
2U3A1.1

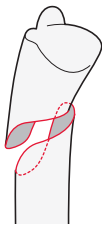


Base of styloid fracture
2U3A1.2

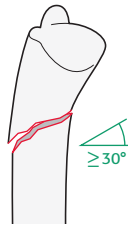


Group: Ulna, distal end segment, extraarticular, **simple fracture** 2U3A2

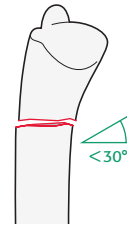
Subgroups:
Spiral fracture
2U3A2.1



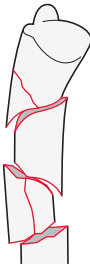
Oblique fracture ($\geq 30^\circ$)
2U3A2.2



Transverse fracture ($< 30^\circ$)
2U3A2.3



Group: Ulna, distal end segment, extraarticular, **multifragmentary fracture** 2U3A3



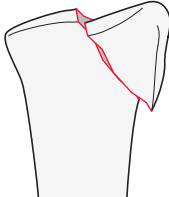
2R3B

Type: Radius, distal end segment, **partial articular fracture** 2R3B

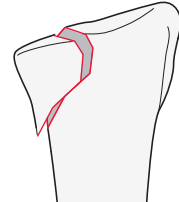
Group: Radius, distal end segment, partial articular, **sagittal fracture** 2R3B1

Subgroups:

Involving scaphoid fossa
2R3B1.1



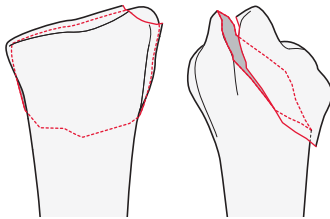
Involving lunate fossa
2R3B1.3



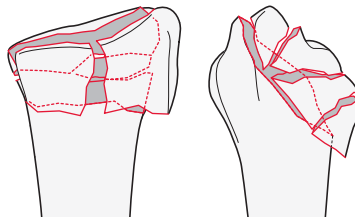
Group: Radius, distal end segment, partial articular, **dorsal rim (Barton's) fracture** 2R3B2

Subgroups:

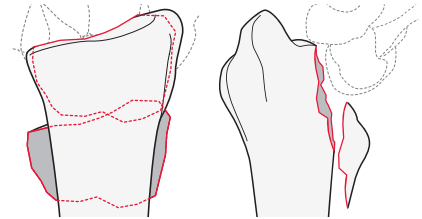
Simple fracture
2R3B2.1



Fragmentary fracture
2R3B2.2



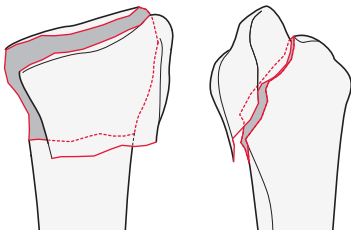
With dorsal dislocation
2R3B2.3



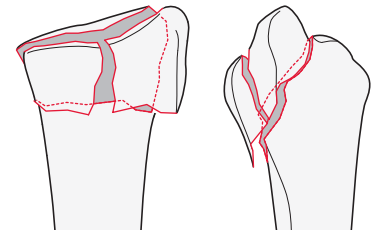
Group: Radius, distal end segment, partial articular, **volar rim (reverse Barton's, Goyrand-Smith's II) fracture** 2R3B3

Subgroups:

Simple fracture
2R3B3.1



Fragmentary fracture
2R3B3.3



2R3C

Type: Radius, distal end segment, **complete articular fracture** 2R3C

Group: Radius, distal end segment, complete, **simple articular and metaphyseal fracture** 2R3C1

Subgroups:

Dorsomedial articular fracture

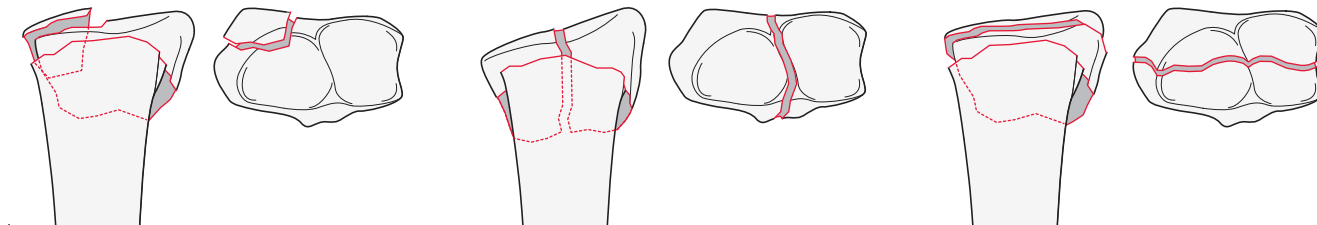
2R3C1.1*

Sagittal articular fracture

2R3C1.2*

Frontal/coronal articular fracture

2R3C1.3*



*Qualifications:
t DRUJ stable
u DRUJ unstable

Group: Radius, distal end segment, complete, simple articular, **metaphyseal multifragmentary fracture** 2R3C2

Subgroups:

Sagittal articular fracture

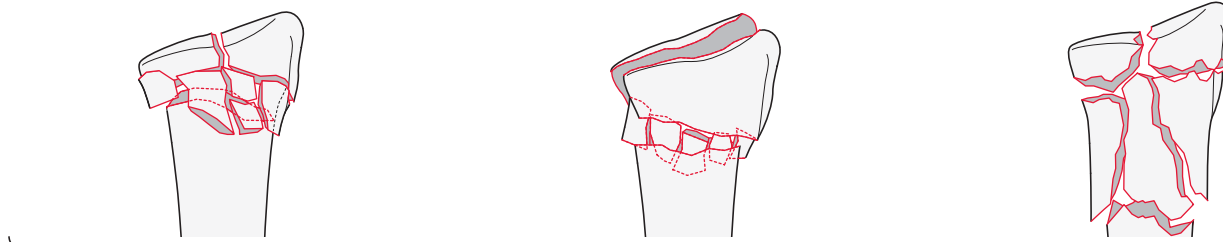
2R3C2.1*

Frontal/coronal fracture

2R3C2.2*

Extending into the diaphysis

2R3C2.3*



*Qualifications:
t DRUJ stable
u DRUJ unstable

Group: Radius, distal end segment, complete, **articular multifragmentary fracture, simple or multifragmentary metaphyseal fracture** 2R3C3

Subgroups:

Simple metaphyseal fracture

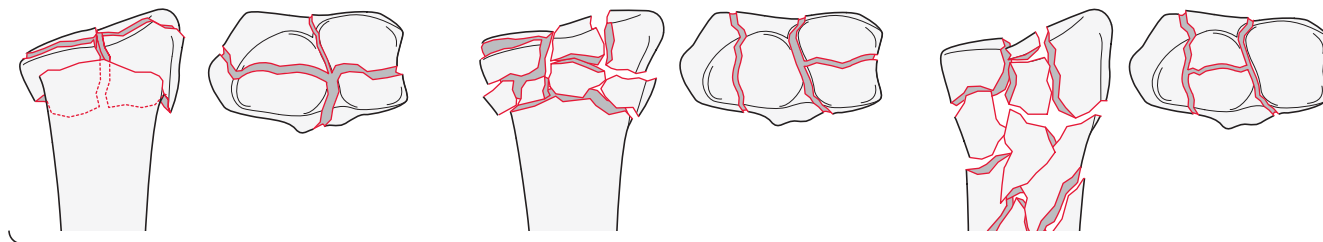
2R3C3.1*

Metaphyseal multifragmentary fracture

2R3C3.2*

Extending into the diaphysis

2R3C3.3*

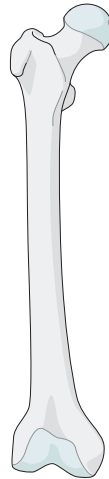


*Qualifications:
t DRUJ stable
u DRUJ unstable

Qualifications are optional and applied to the fracture code where the asterisk is located as a lower-case letter within rounded brackets. More than one qualification can be applied for a given fracture classification, separated by a comma. For a more detailed explanation, see the compendium introduction.

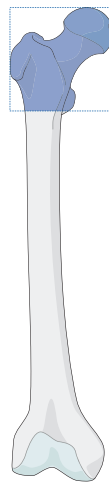
Femur

Bone: Femur 3



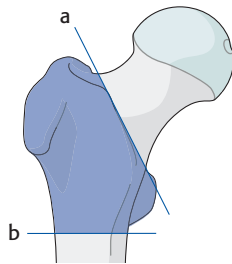
31

Location: Femur, proximal end segment 31



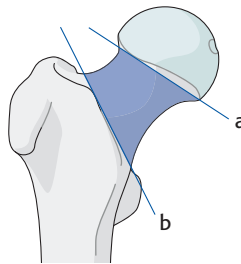
Types:

Femur, trochanteric region fracture
31A



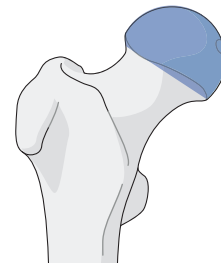Any fracture centered below the intertrochanteric line (a) and above a horizontal transverse line at the inferior border of the lesser trochanter (b).

Femur, neck fracture
31B



Any fracture centered between a line drawn at the distal extent of femoral head articular cartilage (a) and the intertrochanteric line distally (b) are subcapital or femoral neck fractures.

Femur, head fracture
31C



Fractures through the portion of the proximal segment covered with articular cartilage.

Qualifications are optional and applied to the fracture code where the asterisk is located as a lower-case letter within rounded brackets. More than one qualification can be applied for a given fracture classification, separated by a comma. For a more detailed explanation, see the compendium introduction.

31A

Type: Femur, proximal end segment, **trochanteric region fracture** 31A

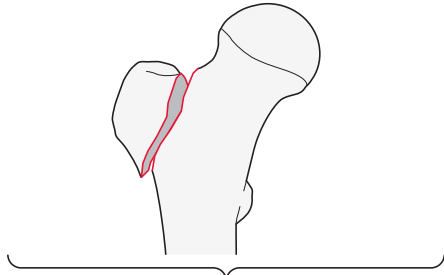
Group: Femur, proximal end segment, trochanteric region, **simple pertrochanteric fracture** 31A1

Subgroups:

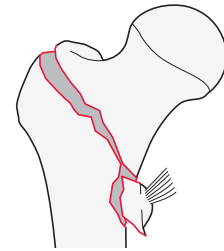
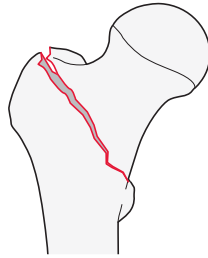
Isolated single trochanter fracture
31A1.1*

Two-part fracture
31A1.2

Lateral wall intact (>20.5 mm) fracture
31A1.3



*Qualifications:
n **Greater trochanter**
o Lesser trochanter

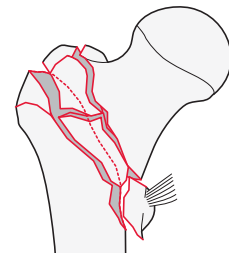
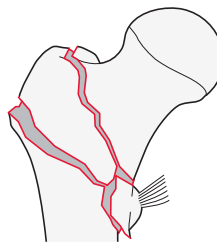


Group: Femur, proximal end segment, trochanteric region, **multifragmentary pertrochanteric, lateral wall incompetent (≤ 20.5 mm) fracture** 31A2

Subgroups:

With 1 intermediate fragment
31A2.2

With 2 or more intermediate fragments
31A2.3



→ For more information about calculating the lateral wall thickness, please refer to the Appendix.

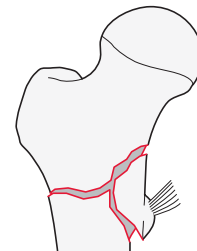
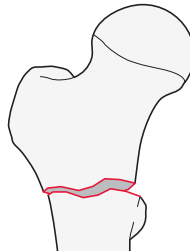
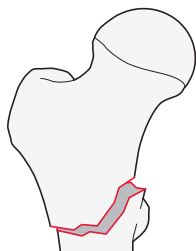
Group: Femur, proximal end segment, trochanteric region, **intertrochanteric (reverse obliquity) fracture** 31A3

Subgroups:

Simple oblique fracture
31A3.1

Simple transverse fracture
31A3.2

Wedge or multifragmentary fracture
31A3.3



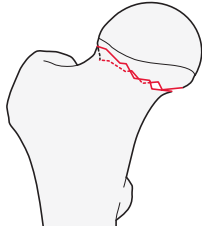
31B

Type: Femur, proximal end segment, **femoral neck fracture** 31B

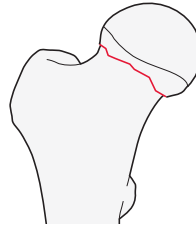
Group: Femur, proximal end segment, femoral neck, **subcapital fracture** 31B1

Subgroups:

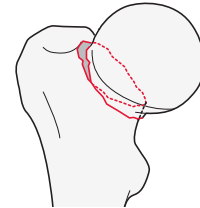
Valgus impacted fracture
31B1.1



Nondisplaced fracture
31B1.2



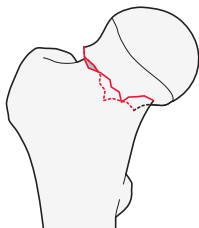
Displaced fracture
31B1.3



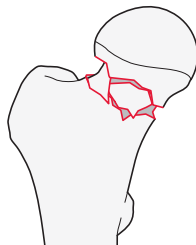
Group: Femur, proximal end segment, femoral neck, **transcervical fracture** 31B2

Subgroups:

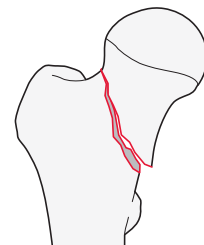
Simple fracture
31B2.1*



Multifragmentary fracture
31B2.2*

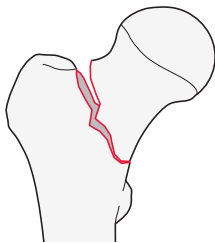


Shear fracture
31B2.3*



*Qualifications:
p Pauwels 1 (<30°)
q Pauwels 2 (30–70°)
r Pauwels 3 (>70°)

Group: Femur, proximal end segment, femoral neck, **basicervical fracture** 31B3



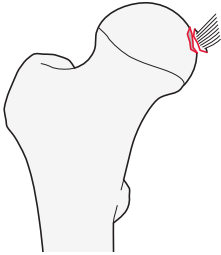
31C

Type: Femur, proximal end segment, **femoral head fracture** 31C

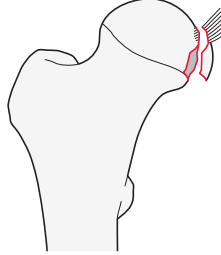
Group: Femur, proximal end segment, femoral head, **split fracture** 31C1

Subgroups:

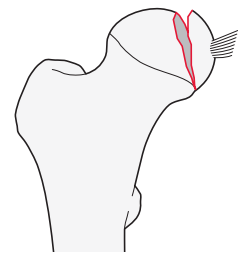
Avulsion of ligamentum teres fracture
31C1.1



Split, infrafoveal fracture
31C1.2



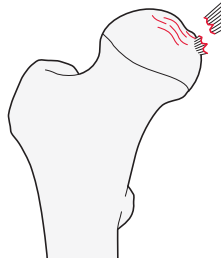
Split, suprafoveal fracture
31C1.3



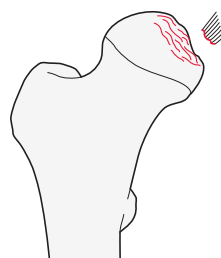
Group: Femur, proximal end segment, femoral head, **depression fracture** 31C2

Subgroups:

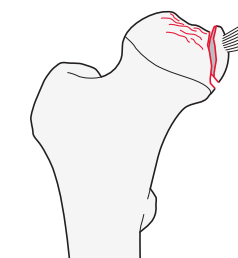
Chondral lesion
31C2.1



Depression impaction fracture
31C2.2



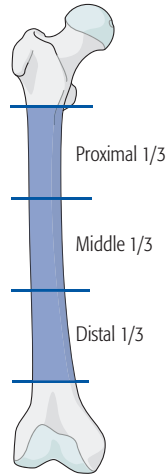
Split depression fracture
31C2.3



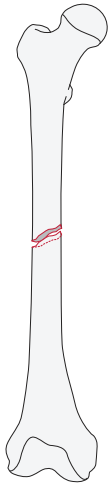
→ Associated dislocations are coded using the dislocation direction universal modifier in square brackets [5_].

32

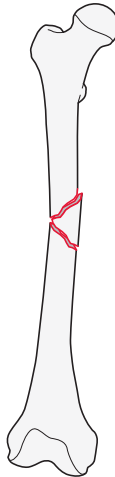
Location: Femur, **diaphyseal segment** 32



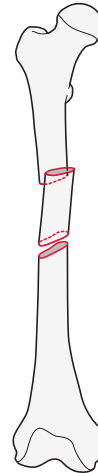
Types:
Femur, diaphyseal segment,
simple fracture
32A



Femur, diaphyseal segment,
wedge fracture
32B



Femur, diaphyseal segment,
multifragmentary fracture
32C



32A

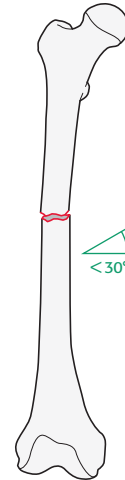
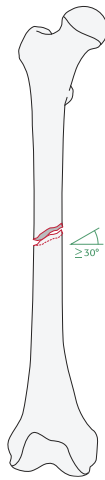
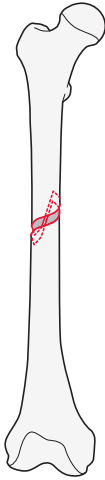
Type: Femur, diaphyseal segment **simple fracture** 32A

Groups:

Femur, diaphyseal segment, simple, **spiral fracture**
32A1*

Femur, diaphyseal segment, simple, **oblique fracture ($\geq 30^\circ$)**
32A2*

Femur, diaphyseal segment, simple, **transverse fracture ($< 30^\circ$)**
32A3*



*Qualifications:
a Proximal 1/3
b **Middle 1/3**
c Distal 1/3

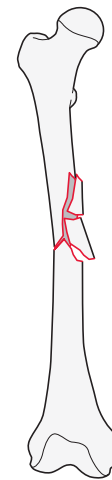
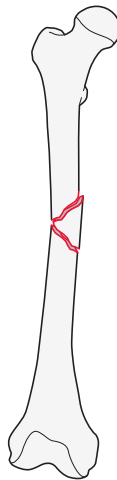
32B

Type: Femur, diaphyseal segment, **wedge fracture** 32B

Groups:

Femur, diaphyseal segment, **intact wedge fracture**
32B2*

Femur, diaphyseal segment, **fragmentary wedge fracture**
32B3*



*Qualifications:
a Proximal 1/3
b **Middle 1/3**
c Distal 1/3

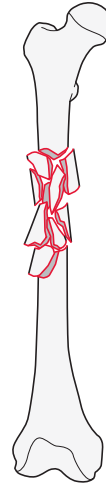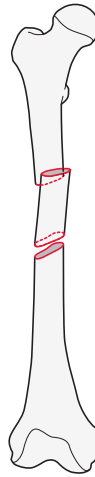
32C

Type: Femur, diaphyseal segment, **multifragmentary fracture** 32C

Groups:

Femur, diaphyseal segment, multifragmentary, **intact segmental fracture**
32C2*

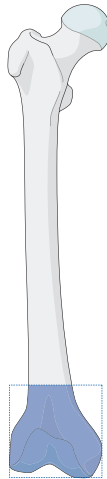
Femur, diaphyseal segment, multifragmentary, **fragmentary segmental fracture**
32C3*



*Qualifications:
i Proximal diaphyseal-metaphyseal
j **Pure diaphyseal**
k Distal diaphyseal-metaphyseal

33

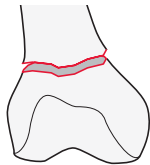
Location: Femur, **distal end segment** 33



Types:

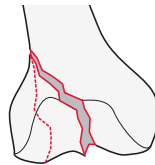
Femur, distal end segment, **extraarticular fracture**

33A



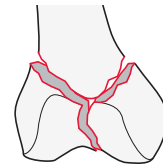
Femur, distal end segment, **partial articular fracture**

33B



Femur, distal end segment, **complete articular fracture**

33C



33A

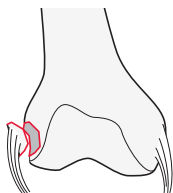
Type: Femur, distal end segment, **extraarticular fracture** 33A

Group: Femur, distal end segment, extraarticular, **avulsion fracture** 33A1

Subgroups:

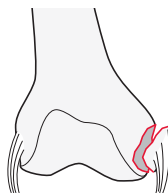
Lateral epicondyle fracture

33A1.1



Medial epicondyle fracture

33A1.2

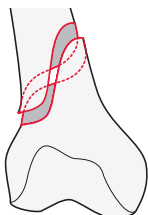


Group: Femur, distal end segment, extraarticular, **simple fracture** 33A2

Subgroups:

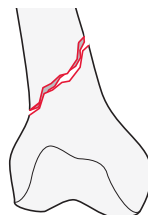
Spiral fracture

33A2.1



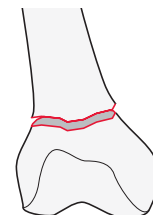
Oblique fracture

33A2.2



Transverse fracture

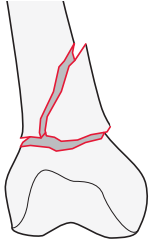
33A2.3



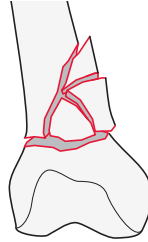
Group: Femur, distal end segment, extraarticular, **wedge or multifragmentary fracture** 33A3

Subgroups:

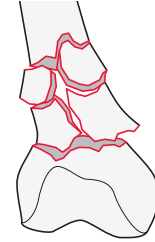
Intact wedge fracture
33A3.1*



Fragmentary wedge fracture
33A3.2*



Multifragmentary fracture
33A3.3



*Qualifications:
f Lateral
h **Medial**

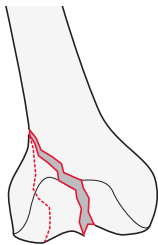
33B

Type: Femur, distal end segment, **partial articular fracture** 33B

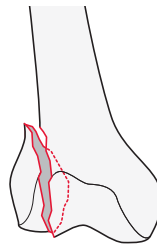
Group: Femur, distal end segment, partial articular, **lateral condyle, sagittal fracture** 33B1

Subgroups:

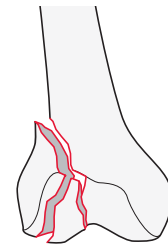
Simple through the notch
33B1.1



Simple through the load bearing surface
33B1.2



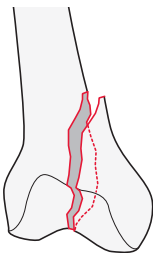
Fragmentary fracture
33B1.3



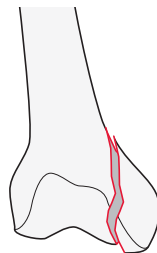
Group: Femur, distal end segment, partial articular, **medial condyle, sagittal fracture** 33B2

Subgroups:

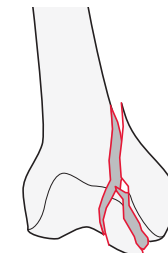
Simple through the notch
33B2.1



Simple through the load bearing surface
33B2.2



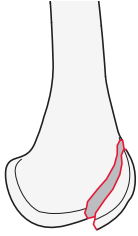
Fragmentary fracture
33B2.3



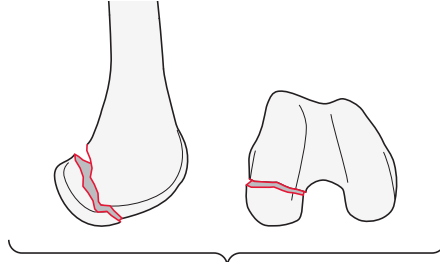
Group: Femur, distal end segment, partial articular, **frontal/coronal fracture** 33B3

Subgroups:

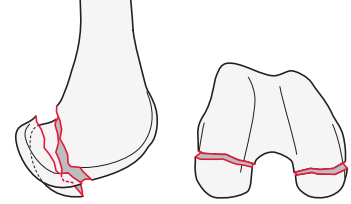
Anterior and lateral flare fracture
33B3.1



Posterior unicondylar fracture (Hoffa)
33B3.2*



Posterior bicondylar fracture (bilateral Hoffa)
33B3.3



*Qualifications:
f **Lateral**
h **Medial**

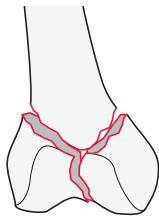
33C

Type: Femur, distal end segment, **complete articular fracture** 33C

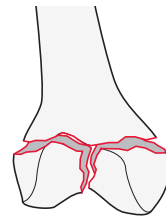
Group: Femur, distal end segment, complete, **simple articular, simple metaphyseal fracture** 33C1

Subgroups:

Above transcondylar axis
33C1.1



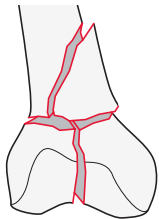
Through or below transcondylar axis
33C1.3



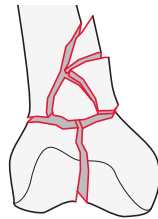
Group: Femur, distal end segment, complete, **simple articular, wedge or multifragmentary metaphyseal fracture** 33C2

Subgroups:

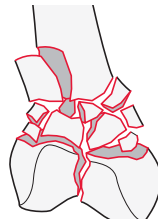
Intact wedge metaphyseal fracture
33C2.1*



Fragmentary wedge metaphyseal fracture
33C2.2*



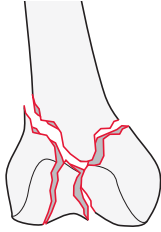
Multifragmentary metaphyseal fracture
33C2.3



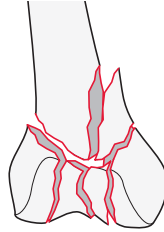
*Qualifications:
f **Lateral**
h **Medial**

Group: Femur, distal end segment, complete, **multifragmentary articular fracture, simple, wedge or multifragmentary metaphyseal fracture** 33C3

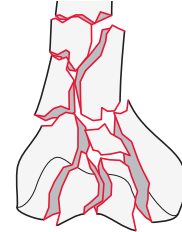
Subgroups:
Simple metaphyseal fracture
 33C3.1



Wedge metaphyseal fracture
 33C3.2*



Multifragmentary metaphyseal fracture
 33C3.3

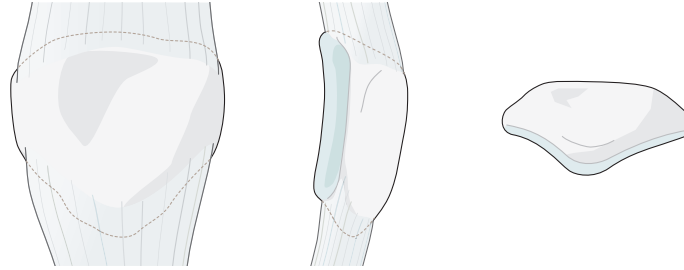


*Qualifications:
 f Lateral
 h **Medial**
 s **Intact**
 l Fragmentary

Qualifications are optional and applied to the fracture code where the asterisk is located as a lower-case letter within rounded brackets. More than one qualification can be applied for a given fracture classification, separated by a comma. For a more detailed explanation, see the compendium introduction.

Patella

Bone: Patella 34

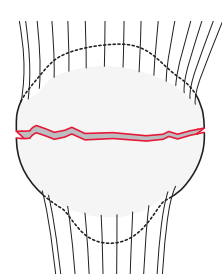
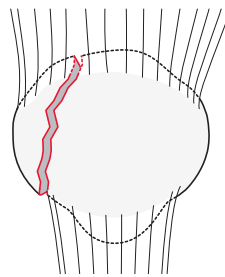
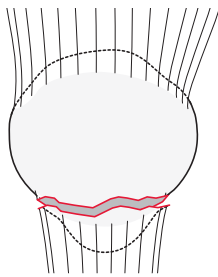


Types:

Patella, **extraarticular fracture**
34A

Patella, **partial articular sagittal fracture**
34B

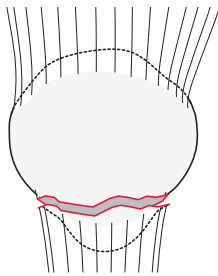
Patella, **complete articular fracture, frontal/coronal plane**
34C



34A

Type: Patella, **extraarticular fracture** 34A

Group: Patella, extraarticular, **avulsion fracture** 34A1*



*Qualifications:

- a Proximal pole
- b **Distal pole**
- c Lateral side
- d Medial side

Qualifications are optional and applied to the fracture code where the asterisk is located as a lower-case letter within rounded brackets. More than one qualification can be applied for a given fracture classification, separated by a comma. For a more detailed explanation, see the compendium introduction.

34B

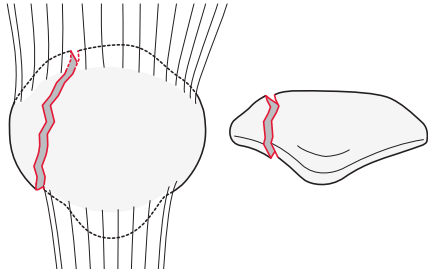
Type: Patella, **partial articular, sagittal fracture** 34B

Group: Patella, partial articular, sagittal, **lateral fracture** 34B1

Subgroup:

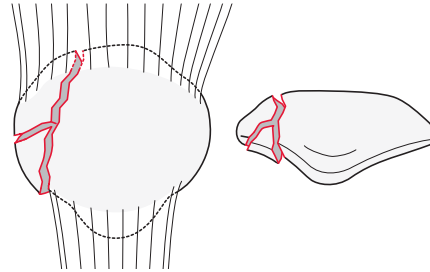
Simple fracture

34B1.1



Fragmentary fracture

34B1.2

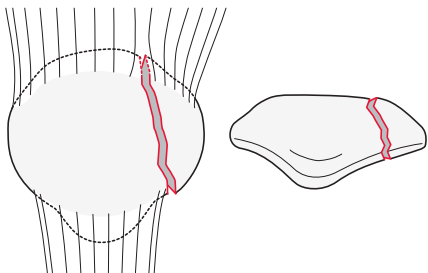


Group: Patella, partial articular, sagittal, **medial fracture** 34B2

Subgroup:

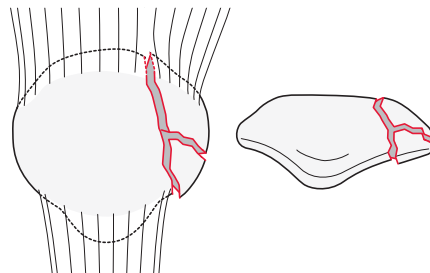
Simple fracture

34B2.1



Fragmentary fracture

34B2.2



34C

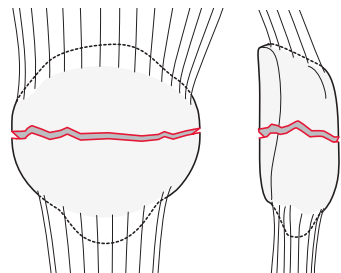
Type: Patella, **complete articular, frontal/coronal fracture** 34C

Group: Patella, complete articular, **frontal/coronal, simple fracture** 34C1

Subgroup:

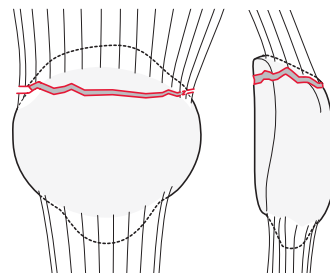
Middle third fracture

34C1.1



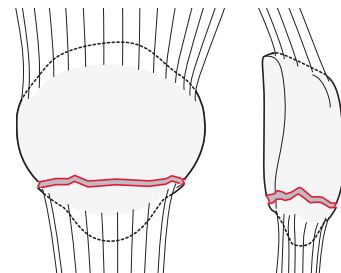
Proximal third fracture

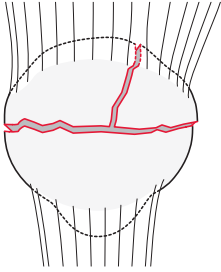
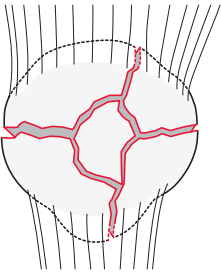
34C1.2



Distal third fracture

34C1.3

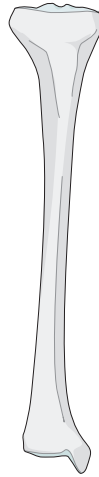


Group:Patella, complete articular, frontal/coronal, **wedge fracture** 34C2**Group:**Patella, complete articular, frontal/coronal, **multifragmentary fracture** 34C3

Qualifications are optional and applied to the fracture code where the asterisk is located as a lower-case letter within rounded brackets. More than one qualification can be applied for a given fracture classification, separated by a comma. For a more detailed explanation, see the compendium introduction.

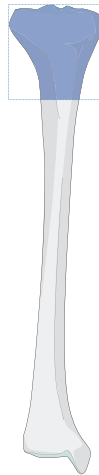
Tibia

Bone: **Tibia** 4



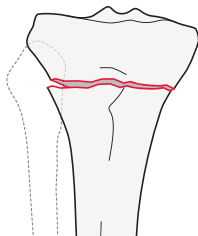
41

Location: **Proximal end segment** 41

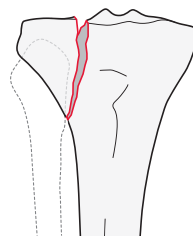


Types:

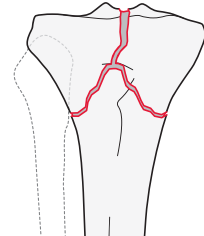
Tibia, proximal end segment,
extraarticular fracture
41A



Tibia, proximal end segment,
partial articular fracture
41B



Tibia, proximal end segment
complete articular fracture
41C



→ To facilitate the coding of tibia and fibula fractures, they are now coded independently. The use of an "F" is required to designate the fibula.

Qualifications are optional and applied to the fracture code where the asterisk is located as a lower-case letter within rounded brackets. More than one qualification can be applied for a given fracture classification, separated by a comma. For a more detailed explanation, see the compendium introduction.

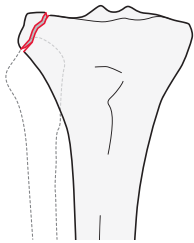
41A

Type: Tibia, proximal end segment, **extraarticular fracture** 41A

Group: Tibia, proximal end segment, extraarticular, **avulsion fracture** 41A1

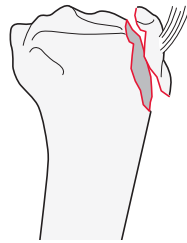
Subgroups:

Of the capsular attachments
41A1.1*

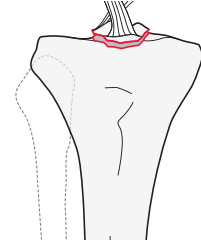


*Qualifications:
n **Lateral (Segond)**
h Medial

Of the tibial tubercle
41A1.2



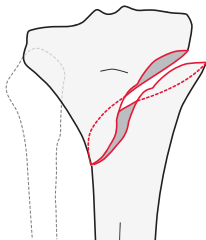
Of tibial spine (cruciate attachment)
41A1.3*



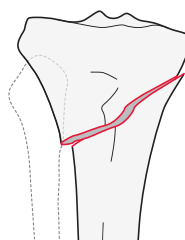
*Qualifications:
o **Anterior**
p Posterior

Group: Tibia, proximal end segment, extraarticular, **simple fracture** 41A2

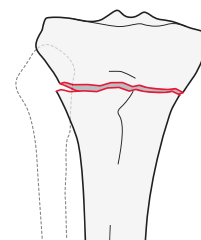
Subgroups:
Spiral fracture
41A2.1



Oblique fracture
41A2.2

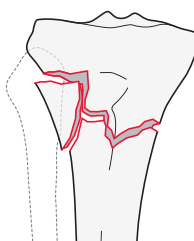


Transverse fracture
41A2.3

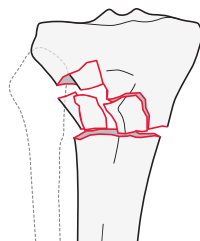


Group: Tibia, proximal end segment, extraarticular, **wedge or multifragmentary fracture** 41A3

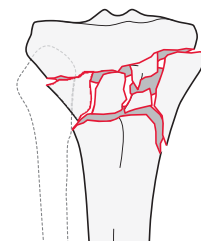
Subgroups:
Intact wedge fracture
41A3.1*



Fragmentary wedge fracture
41A3.2*



Multifragmentary fracture
41A3.3



*Qualifications:
f **Lateral**
h Medial

41B

Type: Tibia, proximal end segment, **partial articular fracture** 41B

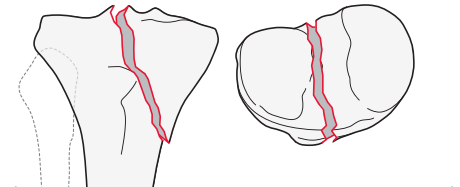
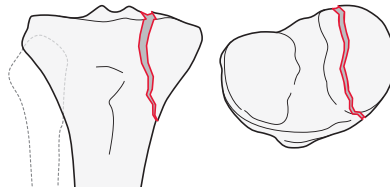
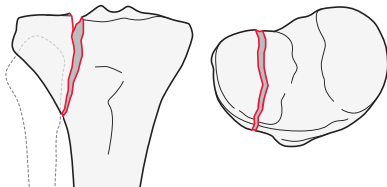
Group: Tibia, proximal end segment, partial articular, **split fracture** 41B1

Subgroups:

Lateral plateau fracture
41B1.1

Medial plateau fracture
41B1.2

Oblique, involving the tibial spines and 1 of the tibial plateaus
41B1.3*



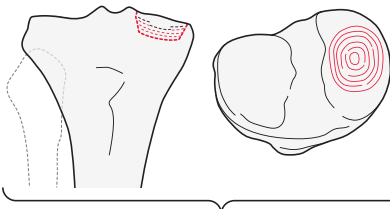
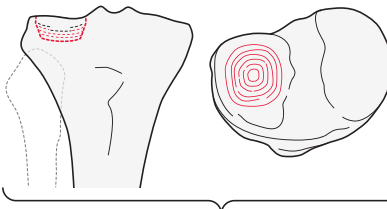
*Qualifications:
f **Lateral**
h **Medial**

Group: Tibia, proximal end segment, partial articular, **depression fracture** 41B2

Subgroups:

Lateral plateau fracture
41B2.1*

Medial plateau fracture
41B2.2



*Qualifications:
t Anterolateral (AL)
u **Posterolateral (PL)**
x Central

*Qualifications:
v Anteromedial (AM)
w Posteromedial (PM)
x **Central**

→ For more information about the division of the proximal tibia into quadrants, please refer to the Appendix.

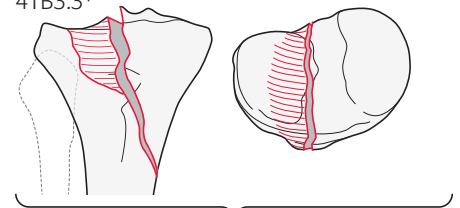
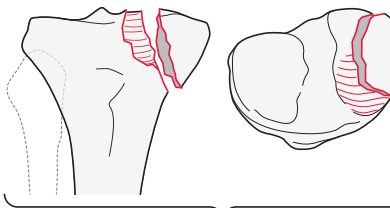
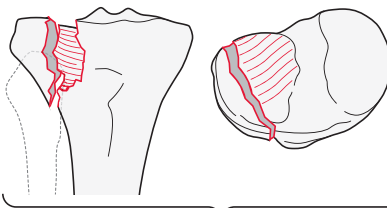
Group: Tibia, proximal end segment, partial articular, **split-depression fracture** 41B3

Subgroups:

Lateral plateau fracture
41B3.1*

Medial plateau fracture
41B3.2*

Involving the tibial spines and 1 of the tibial plateaus
41B3.3*



*Qualifications:
t Anterolateral (AL)
u **Posterolateral (PL)**
x Central

*Qualifications:
v **Anteromedial (AM)**
w Posteromedial (PM)
x Central

*Qualifications:
f **Lateral**
h **Medial**

→ For more information about the division of the proximal tibia into quadrants, please refer to the Appendix.

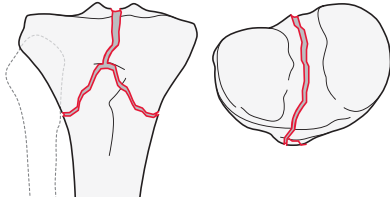
41C

Type: Tibia, proximal end segment, **complete articular fracture** 41C

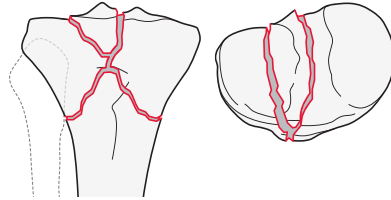
Group: Tibia, proximal end segment, complete, **simple articular, simple metaphyseal fracture** 41C1

Subgroups:

Without intercondylar eminence fracture
41C1.1



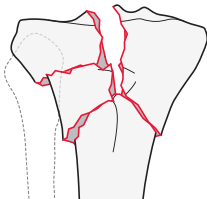
With intercondylar eminence fracture
41C1.2



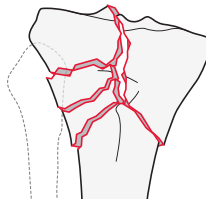
Group: Tibia, proximal end segment, complete, **simple articular, wedge or multifragmentary metaphyseal fracture** 41C2

Subgroups:

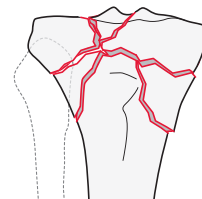
Intact wedge fracture
41C2.1*



Fragmentary wedge fracture
41C2.2*



Multifragmentary metaphyseal fracture
41C2.3

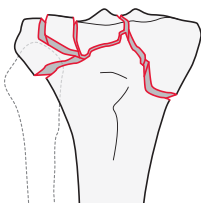


*Qualifications
f **Lateral**
h Medial

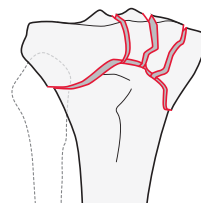
Group: Tibia, proximal end segment, complete, **fragmentary or multifragmentary metaphyseal fracture** 41C3

Subgroups:

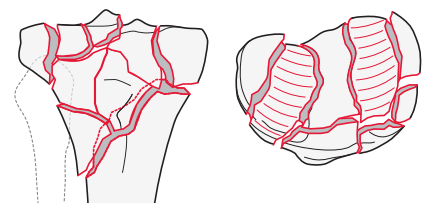
Fragmentary lateral plateau fracture
41C3.1*



Fragmentary medial plateau fracture
41C3.2*



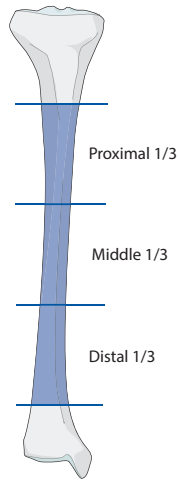
Multifragmentary medial and lateral plateau fracture
41C3.3*



*Qualifications:
d Simple metaphysis
e Multifragmentary metaphysis
s Metadiaphyseal extension
t Anterolateral (AL)
u Posterolateral (PL)
v Anteromedial (AM)
w Posteromedial (PM)
x Central

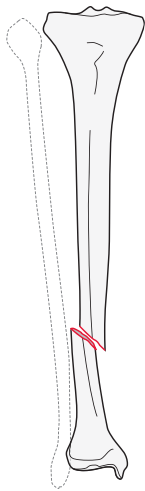
42

Location: Tibia, **diaphyseal segment** 42

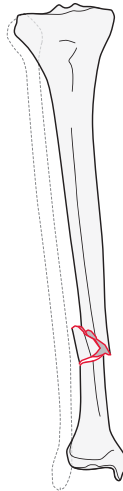


Types:

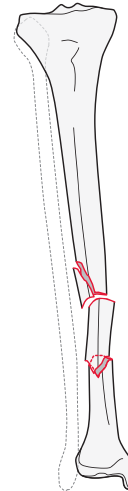
Tibia, diaphyseal segment
simple fracture
42A



Tibia, diaphyseal segment,
wedge fracture
42B



Tibia, diaphyseal segment,
multifragmentary fracture
42C



42A

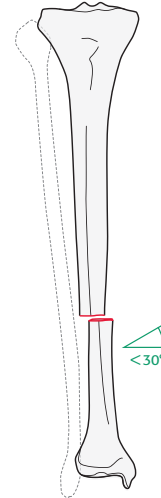
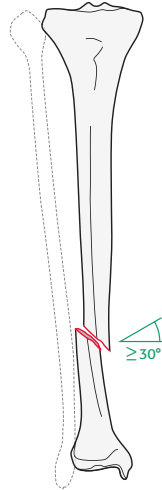
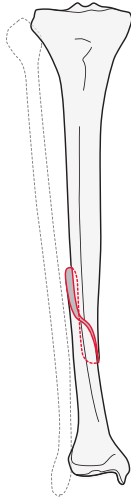
Type: Tibia, diaphyseal segment, **simple fracture** 42A

Groups:

Tibia, diaphyseal segment, simple, **spiral fracture** 42A1*

Tibia, diaphyseal segment, simple, **oblique fracture ($\geq 30^\circ$)** 42A2*

Tibia, diaphyseal segment, simple, **transverse fracture ($<30^\circ$)** 42A3*



*Qualifications:
 a Proximal 1/3
 b Middle 1/3
 c **Distal 1/3**

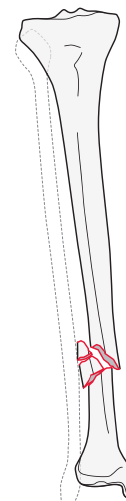
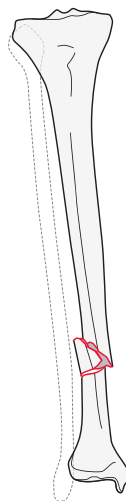
42B

Type: Tibia, diaphyseal segment, **wedge fracture** 42B

Groups:

Tibia, diaphyseal segment, **intact wedge fracture** 42B2*

Tibia, diaphyseal segment, **fragmentary wedge fracture** 42B3*



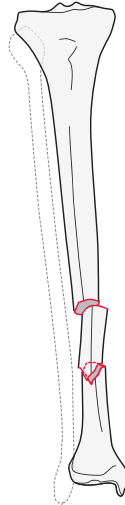
*Qualifications:
 a Proximal 1/3
 b Middle 1/3
 c **Distal 1/3**

42C

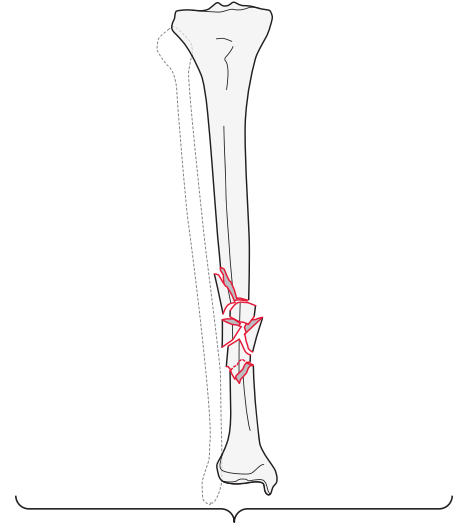
Type: Tibia, diaphyseal segment, **multifragmentary fracture** 42C

Groups:

Tibia, diaphyseal segment, multifragmentary,
intact segmental fracture
42C2



Tibia, diaphyseal segment, multifragmentary,
fragmentary segmental fracture
42C3*

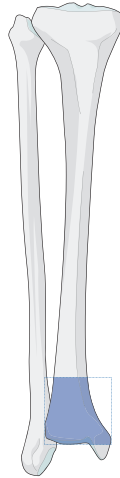

*Qualifications:

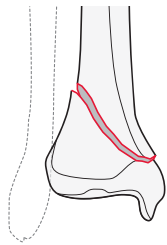
- i Proximal diaphyseal-metaphyseal
- j **Pure diaphyseal**
- k Distal diaphyseal-metaphyseal

43

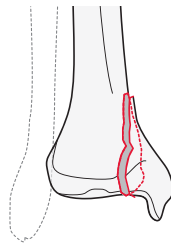
Location: Tibia, **distal end segment** 43



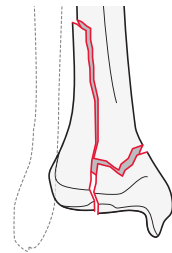
Types:
Tibia, distal end segment,
extraarticular fracture
43A



Tibia, distal end segment,
partial articular fracture
43B



Tibia, distal end segment,
complete articular fracture
43C

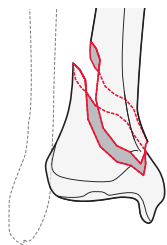


43A

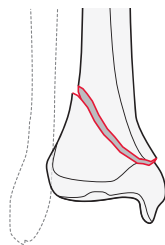
Type: Tibia, distal end segment, **extraarticular fracture** 43A

Group: Tibia, distal end segment, extraarticular, **simple fracture** 43A1

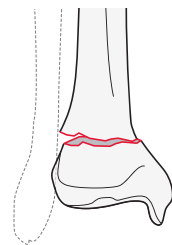
Subgroups:
Spiral fracture
43A1.1



Oblique fracture
43A1.2



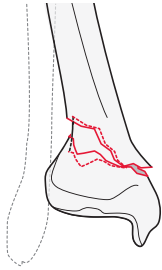
Transverse fracture
43A1.3



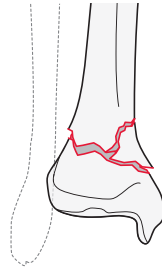
Group: Tibia, distal end segment, extraarticular, **wedge fracture** 43A2

Subgroups:

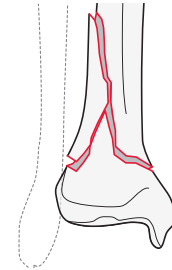
Posterolateral impaction fracture
43A2.1



Anteromedial wedge fracture
43A2.2



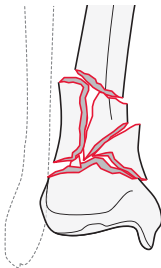
Fracture extending into diaphysis
43A2.3



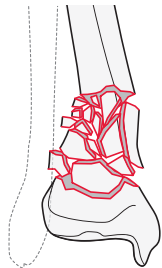
Group: Tibia, distal end segment, extraarticular, **multifragmentary fracture** 43A3

Subgroups:

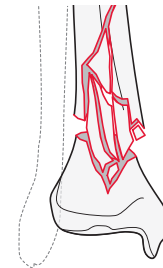
With 3 intermediate fragments
43A3.1



With more than 3 intermediate fragments
43A3.2



Extending into diaphysis
43A3.3



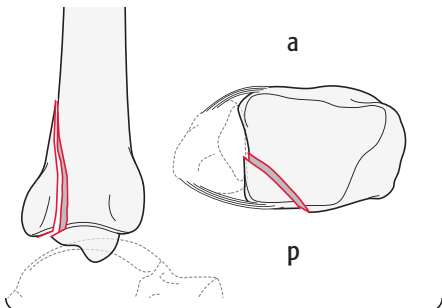
43B

Type: Tibia, distal end segment, **partial articular fracture** 43B

Group: Tibia, distal end segment, partial articular, **split fracture** 43B1

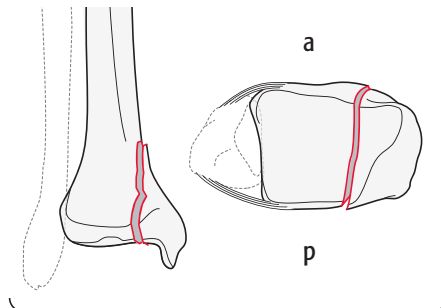
Subgroups:

Frontal/coronal fracture
43B1.1*



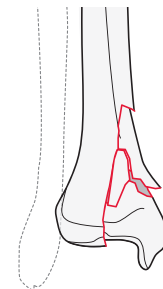
*Qualifications:
o Anterior
y **Posterior Volkmann**

Sagittal fracture
43B1.2*



*Qualifications:
f Lateral
z **Medial articular surface including medial malleolus**

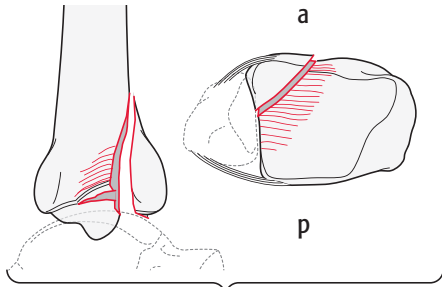
Fragmentary metaphyseal fracture
43B1.3



Group: Tibia, distal end segment partial articular, **split depression fracture** 43B2

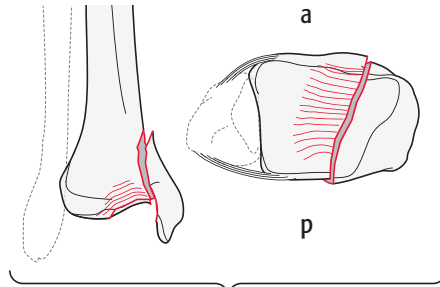
Subgroups:

Frontal/coronal fracture
43B2.1*



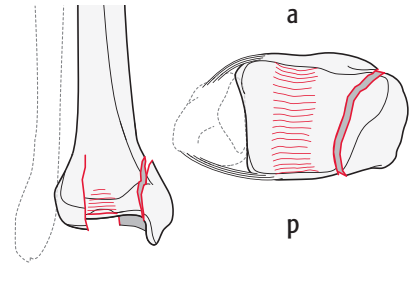
*Qualifications:
o **Anterior**
y **Posterior** Volkmann

Sagittal fracture
43B2.2*



*Qualifications:
f **Lateral**
h **Medial**

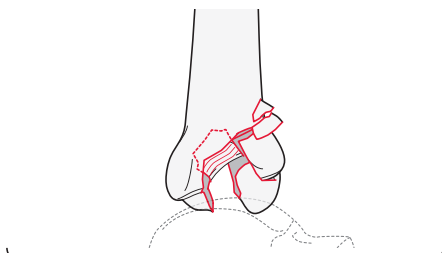
Central fragment fracture
43B2.3



Group: Tibia, distal end segment, partial articular, **depression fracture** 43B3

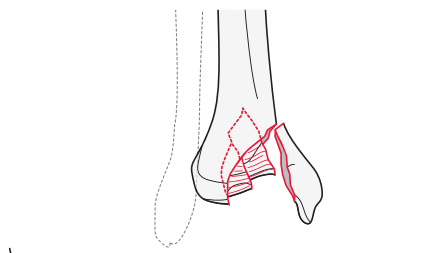
Subgroups:

Frontal/coronal fracture
43B3.1*



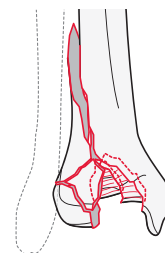
*Qualifications:
o **Anterior**
y **Posterior** Volkmann

Sagittal fracture
43B3.2*



*Qualifications:
f **Lateral**
h **Medial**

Fragmentary metaphyseal fracture
43B3.3



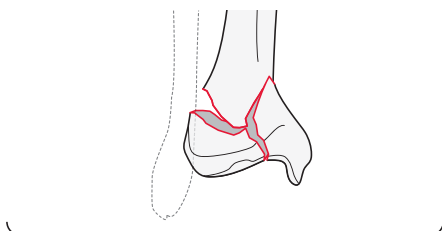
43C

Type: Tibia, distal end segment, **complete articular fracture** 43C

Group: Tibia, distal end segment, complete, **simple articular, simple metaphyseal fracture** 43C1

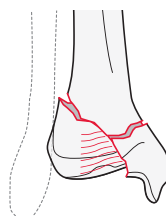
Subgroups:

Without impaction
43C1.1*

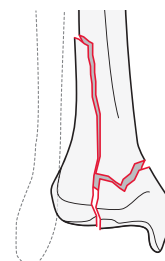


*Qualifications:
q **Frontal/coronal plane**
r **Sagittal plane**

With epiphyseal depression
43C1.2



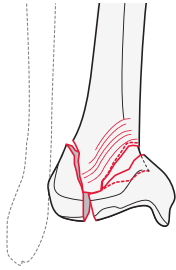
Extending into diaphysis
43C1.3



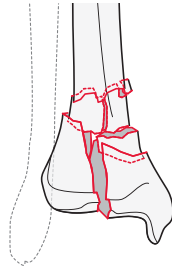
Group: Tibia, distal end segment, complete, **simple articular, multifragmentary metaphyseal fracture** 43C2

Subgroups:

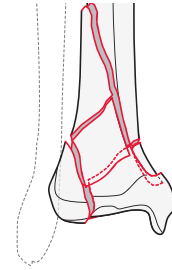
With asymmetric impaction
43C2.1*



Without asymmetric impaction
43C2.2



Extending into diaphysis
43C2.3

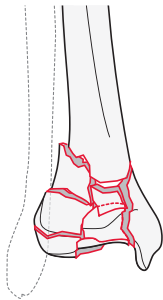


*Qualifications:
q Frontal/coronal plane
r **Sagittal plane**

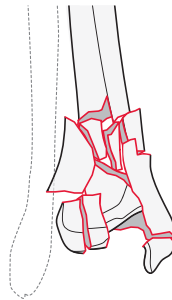
Group: Tibia, distal end segment, complete, **multifragmentary articular and metaphyseal fracture** 43C3

Subgroups:

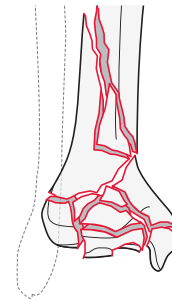
Epiphyseal fracture
43C3.1



Epiphyseal-metaphyseal fracture
43C3.2



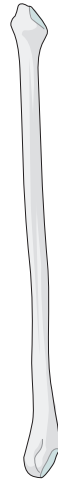Epiphyseal-metaphyseal-diaphyseal fracture
43C3.3



Qualifications are optional and applied to the fracture code where the asterisk is located as a lower-case letter within rounded brackets. More than one qualification can be applied for a given fracture classification, separated by a comma. For a more detailed explanation, see the compendium introduction.

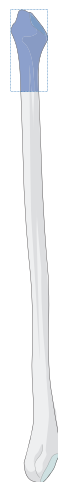Fibula

Bone: Fibula 4F



4F1

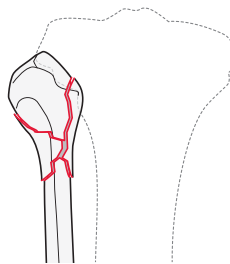
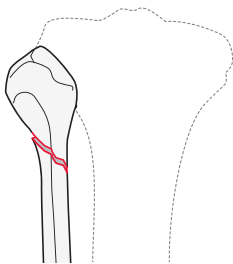
Location: Fibula, proximal end segment 4F1



Types:

Fibula, proximal end segment,
simple fracture
4F1A*

Fibula, proximal end segment,
multifragmentary fracture
4F1B*



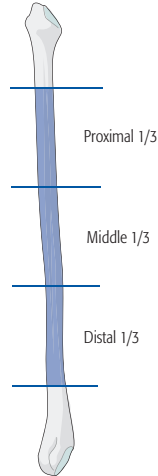
*Qualifications:
n Extraarticular
o Intraarticular

→ To facilitate the coding of tibia/fibula fractures, they are now coded independently. The use of an "F" is required to designate the fibula.

Qualifications are optional and applied to the fracture code where the asterisk is located as a lower-case letter within rounded brackets. More than one qualification can be applied for a given fracture classification, separated by a comma. For a more detailed explanation, see the compendium introduction.

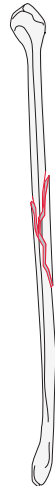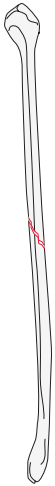4F2

Location: Fibula, **diaphyseal segment** 4F2



Types:
Fibula, diaphyseal segment,
simple fracture
4F2A*

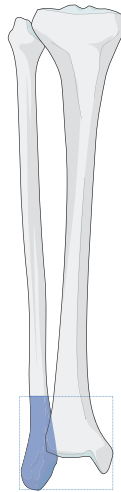
Fibula, diaphyseal segment,
wedge or multifragmentary fracture
4F2B*



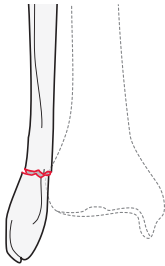
*Qualifications:
a Proximal 1/3
b **Middle 1/3**
c Distal 1/3

4F3

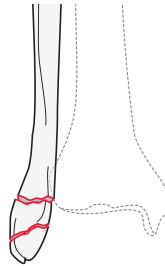
Location: Fibula, **distal end segment**
(excluding lateral malleolar fractures 44) 4F3



Types:
Distal end segment,
simple fracture
4F3A



Distal end segment
wedge or multifragmentary fracture
4F3B

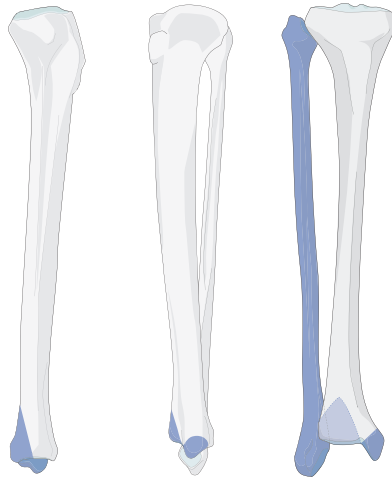


→ The fibular fracture code is used only if the distal fibula fracture is NOT part of a malleolar fracture (44). For further information, please refer to the Appendix.

Qualifications are optional and applied to the fracture code where the asterisk is located as a lower-case letter within rounded brackets. More than one qualification can be applied for a given fracture classification, separated by a comma. For a more detailed explanation, see the compendium introduction.

Malleolar segment

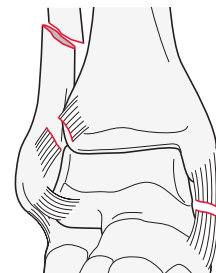
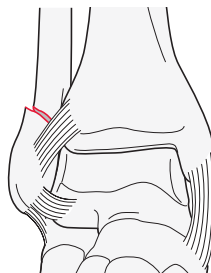
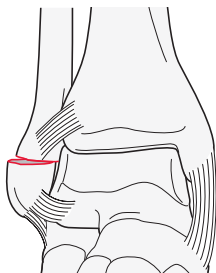
Location: Tibia/fibula, **malleolar segment** 44



Types:
Tibia/ fibula, malleolar segment,
infrasyndesmotic fibula injury
44A

Tibia/fibula, malleolar segment,
transsyndesmotic fibula fracture
44B

Tibia/fibula, malleolar segment,
suprasyndesmotic fibula fracture
44C



44A

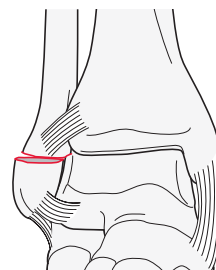
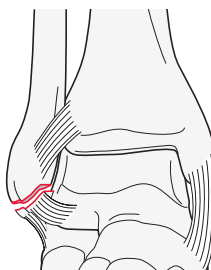
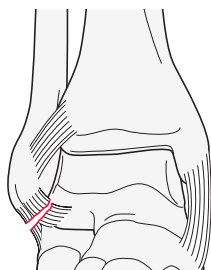
Type: Tibia/fibula, malleolar segment, **infrasyndesmotic fibula injury** 44A

Group: Tibia/fibula, malleolar segment, infrasyndesmotic, **isolated fibula injury** 44A1

Subgroups:
Rupture of the lateral collateral ligament
44A1.1

Avulsion fracture of the tip of the lateral malleolus
44A1.2

Transverse fracture of the lateral malleolus
44A1.3

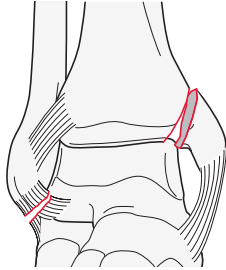


Qualifications are optional and applied to the fracture code where the asterisk is located as a lower-case letter within rounded brackets. More than one qualification can be applied for a given fracture classification, separated by a comma. For a more detailed explanation, see the compendium introduction.

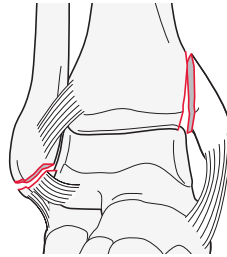
Group: Tibia/fibula, malleolar, infrasyn-desmotic fibula injury **with a medial malleolar fracture** 44A2

Subgroups:

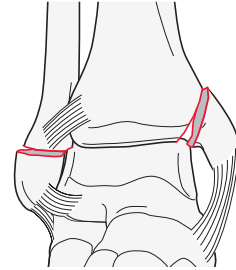
Rupture of the lateral collateral ligament
44A2.1



Avulsion fracture of the tip of the lateral malleolus
44A2.2



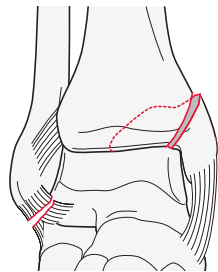
Transverse fracture of the lateral malleolus
44A2.3



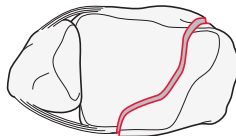
Group: Tibia/fibula, malleolar, infrasyn-desmotic fibular injury **with a posteromedial fracture** 44A3

Subgroups:

Rupture of the lateral collateral ligament with a posteromedial fracture
44A3.1

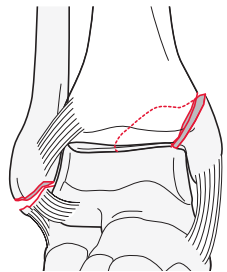


a

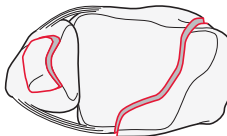


p

Avulsion fracture of the tip of the lateral malleolus with a posteromedial fracture
44A3.2

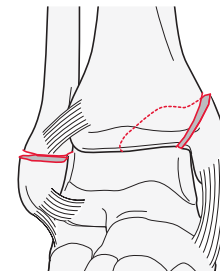


a

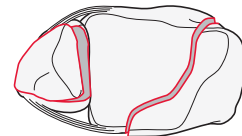


p

Transverse fracture of the lateral malleolus with a posteromedial fracture
44A3.3



a



p

44B

Type: Tibia/fibula, malleolar segment, **transsyndesmotic fibula fracture** 44B

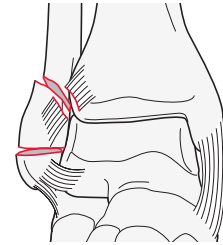
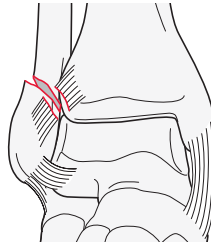
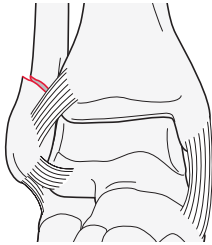
Group: Tibia/fibula, malleolar segment, transsyndesmotic **isolated fibula fracture** 44B1

Subgroups:

Simple fibula fracture
44B1.1*

With a rupture of the anterior syndesmosis
44B1.2*

Wedge or multifragmentary fibula fracture
44B1.3*



*Qualifications:
n Tillaux-Chaput tubercle fracture
o Wagstaffe-Le Fort avulsion fracture
u Syndesmosis unstable

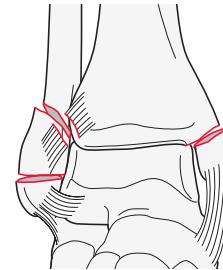
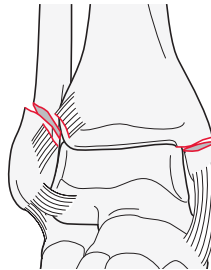
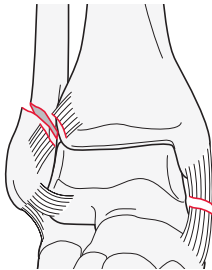
Group: Tibia/fibula, malleolar segment, transsyndesmotic fibula fracture **with a medial injury** 44B2

Subgroups:

With a rupture of the deltoid ligament and anterior syndesmosis
44B2.1*

With a medial malleolus fracture and a rupture of the anterior syndesmosis
44B2.2*

Wedge or multifragmentary fibula fracture with medial injury
44B2.3*



*Qualifications:
n Tillaux-Chaput tubercle fracture
o Wagstaffe-Le Fort avulsion fracture
u Syndesmosis unstable

*Qualifications:
r Rupture of deltoid ligament
s **Fracture of medial malleolus**
u Syndesmosis unstable

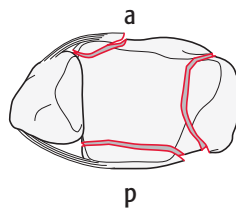
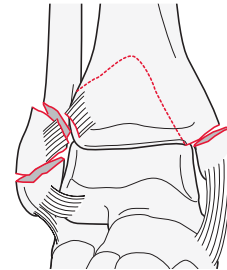
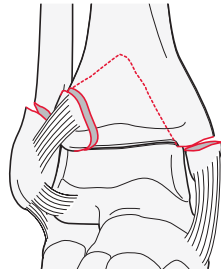
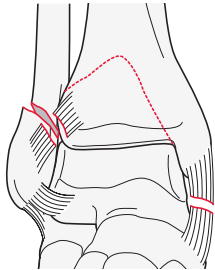
Group: Tibia/fibula, malleolar segment, **transsyndesmotic fibula fracture with a medial injury and fracture of the posterolateral rim (Volkman's fragment)** 44B3

Subgroups:

Simple, with a deltoid ligament rupture
44B3.1*

Simple medial malleolus fracture
44B3.2*

Wedge or multifragmentary fibular fracture with a fracture of the medial malleolus
44B3.3*



*Qualifications:
n Tillaux-Chaput tubercle fracture
o Wagstaffe-Le Fort avulsion fracture
u Syndesmosis unstable

44C

Type: Tibia/fibula, malleolar segment, **suprasyndesmotic fibula injury** 44C

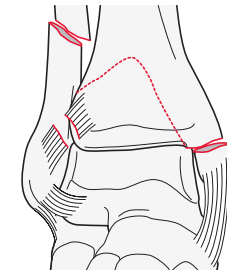
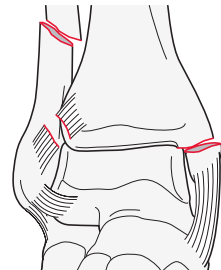
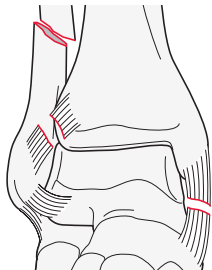
Group: Tibia/fibula, malleolar segment, suprasyndesmotic, **simple diaphyseal fibula fracture** 44C1

Subgroups:

With a rupture of the deltoid ligament
44C1.1*

With a fracture of the medial malleolus
44C1.2*

With a medial and a posterior malleolus fracture
44C1.3*



*Qualifications:
t Syndesmosis stable
u Syndesmosis unstable

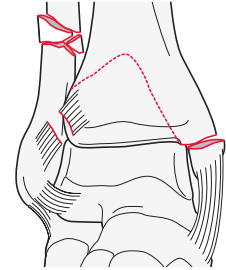
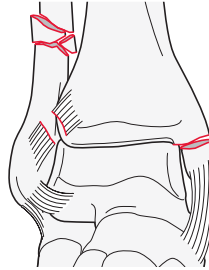
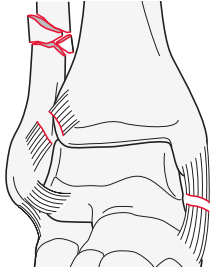
Group: Tibia/fibula, malleolar segment, suprasyndesmotoc, **wedge or multifragmentary diaphyseal fibula fracture** 44C2

Subgroups:

With a rupture of the deltoid ligament
44C2.1*

With a fracture of the medial malleolus
44C2.2*

With a fracture of the medial malleolus and posterior malleolus
44C2.3*



*Qualifications:
t Syndesmosis stable
u Syndesmosis unstable

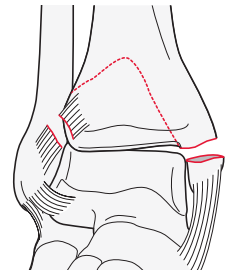
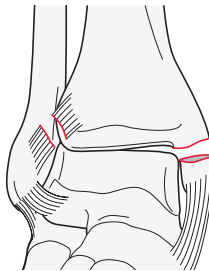
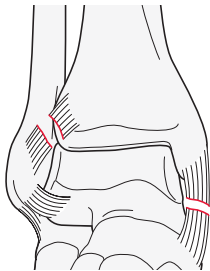
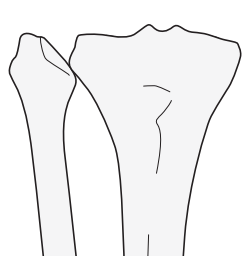
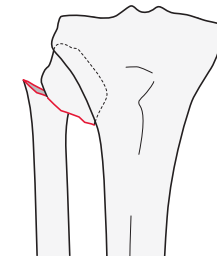
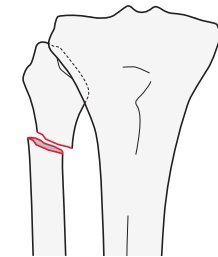
Group: Tibia/fibula, malleolar segment, suprasyndesmotoc, **proximal fibula injury** 44C3

Subgroups:

With a medial side injury
44C3.1*

With shortening and a medial side injury
44C3.2*

With a medial side injury and a posterior malleolus fracture
44C3.3*

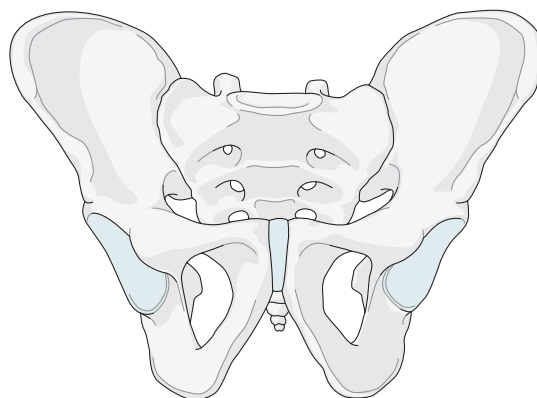


*Qualifications:
p Fibula neck fracture
q Proximal tibio-fibular joint dislocation
r Rupture of deltoid ligament
s Fracture of medial malleolus

Qualifications are optional and applied to the fracture code where the asterisk is located as a lower-case letter within rounded brackets. More than one qualification can be applied for a given fracture classification, separated by a comma. For a more detailed explanation, see the compendium introduction.

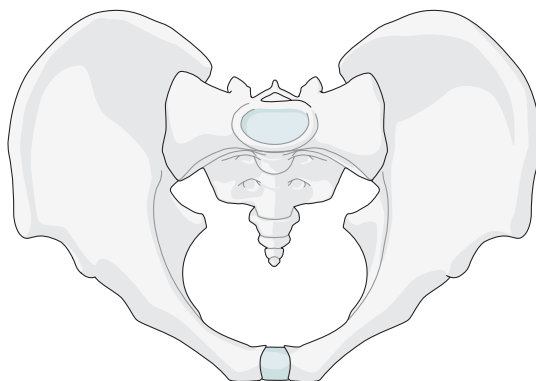
Pelvic ring

Bone: Pelvis 6



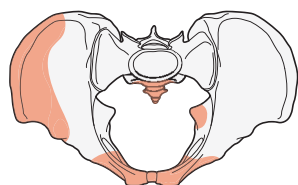
61

Location: Pelvis, pelvic ring 61

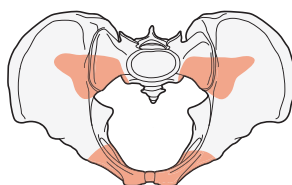


Types:

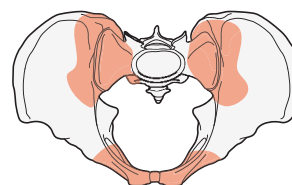
Pelvis, pelvic ring, **intact posterior arch**
61A



Pelvis, pelvic ring, **incomplete disruption of posterior arch**
61B



Pelvis, pelvic ring, **complete disruption of posterior arch**
61C



Qualifications are optional and applied to the fracture code where the asterisk is located as a lower-case letter within rounded brackets. More than one qualification can be applied for a given fracture classification, separated by a comma. For a more detailed explanation, see the compendium introduction.

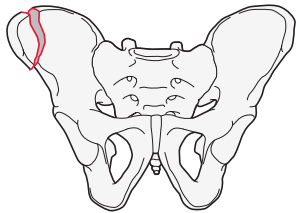
61A

Type: Pelvis, pelvic ring, **intact posterior arch** 61A

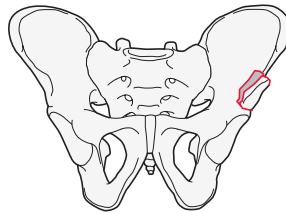
Group: Pelvis, pelvic ring, intact posterior arch, **innominate bone avulsion fracture** 61A1

Subgroups:

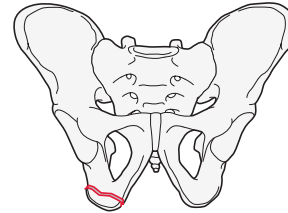
Anterior superior iliac spine fracture
61A1.1



Anterior inferior iliac spine fracture
61A1.2



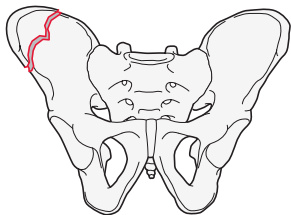
Ischial tuberosity fracture
61A1.3



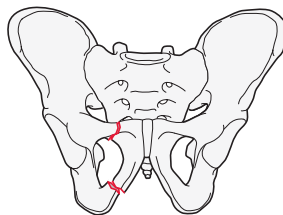
Group: Pelvis, pelvic ring, intact posterior arch, **innominate bone fracture** 61A2

Subgroups:

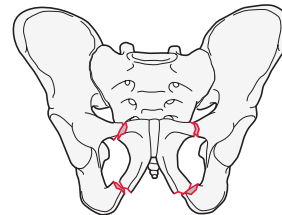
Iliac wing fracture
61A2.1



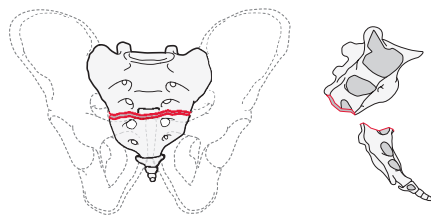
Unilateral fracture of the anterior arch
61A2.2



Bilateral fractures of the anterior arch
61A2.3



Group¹: Pelvis, pelvic ring, **transverse fracture of sacrum (S3, S4, S5) and coccyx** 61A3



¹Fracture of the upper sacral segments attached to sacroiliac joints (S1, S2) are classified as part of the pelvic ring injury. If a more detailed classification is required refer to sacral classification (S4) in the Spine classification.

61B

Type: Pelvis, pelvic ring, **incomplete disruption of posterior arch** 61B

Group: Pelvis, pelvic ring, incomplete disruption of posterior arch, **no rotational instability** 61B1

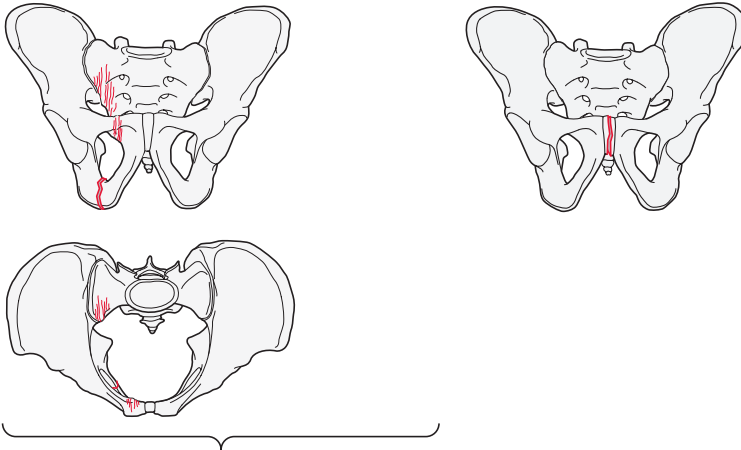
Subgroups:

Lateral compression fracture (LC1)

61B1.1*

Open book fracture (APC1)

61B1.2



*Qualifications:

- a Ipsilateral or unilateral pubic ramus fracture
- b Bilateral pubic rami fracture
- c Contralateral pubic ramus fracture
- e Parasymphyseal fracture
- f Tilt fracture
- g Locked symphysis

Group: Pelvis, pelvic ring, incomplete disruption of posterior arch, **rotationally unstable, unilateral posterior injury** 61B2

Subgroups:

Lateral compression fracture of the sacrum with internal rotation instability (LC1)

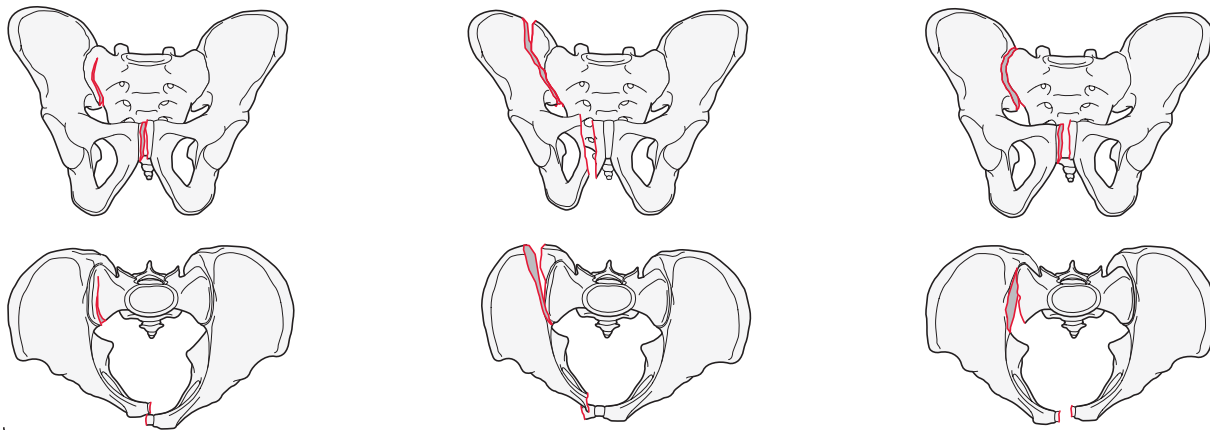
61B2.1*

Lateral compression fracture of the ilium (crescent) with internal rotation instability (LC2)

61B2.2*

Open book or external rotation instability (APC2)

61B2.3*



*Qualifications:

- a Ipsilateral or unilateral pubic ramus fractures
- b Bilateral pubic rami fractures
- c Contralateral pubic ramus fractures
- d Symphysis disruption
- e Parasymphyseal fracture
- f Tilt fracture
- g Locked symphysis

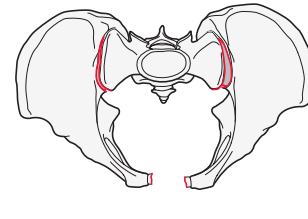
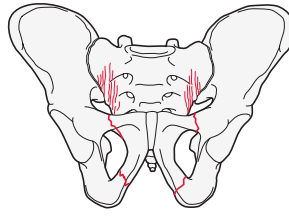
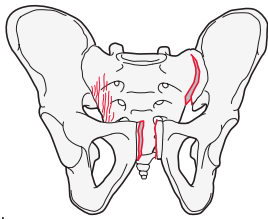
Group: Pelvis, pelvic ring, incomplete disruption of posterior arch, rotationally unstable, **bilateral posterior injury** 61B3

Subgroups:

Internal rotationally unstable on one side and external rotationally unstable on the contralateral side (LC3)
61B3.1*

Bilateral lateral compression sacral fracture
61B3.2*

Open book or external rotation instability (bilateral APC2)
61B3.3*



*Qualifications:

- a Ipsilateral or unilateral pubic ramus fractures
- b Bilateral pubic rami fractures
- c Contralateral pubic ramus fracture
- d Symphysis disruption
- e Parasymphyseal fracture
- f Tilt fracture
- g Locked symphysis

61C

Type: Pelvis, pelvic ring, **complete disruption of posterior arch** 61C

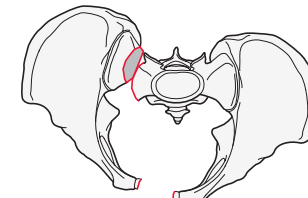
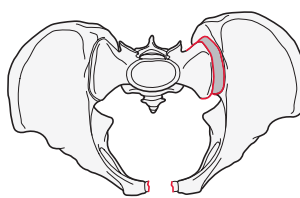
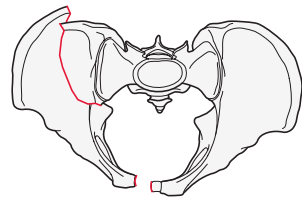
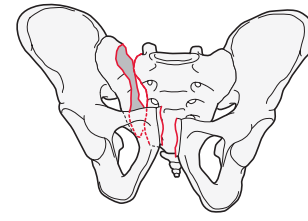
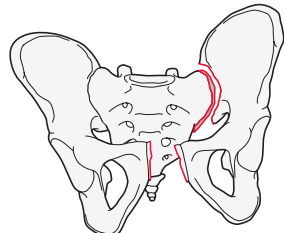
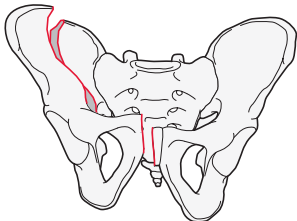
Group: Pelvis, pelvic ring, complete disruption of posterior arch, **unilateral posterior injury (APC3, vertical shear)** 61C1

Subgroups:

With iliac fracture
61C1.1*

Through the sacroiliac joint
61C1.2*

With a sacral fracture
61C1.3*



*Qualifications:

- a Ipsilateral or unilateral pubic ramus fracture
- b Bilateral pubic rami fracture
- c Contralateral pubic ramus fracture
- d **Symphysis disruption**
- e Parasymphyseal fracture
- f Tilt fracture
- g Locked symphysis
- j Sacroiliac joint fracture dislocation

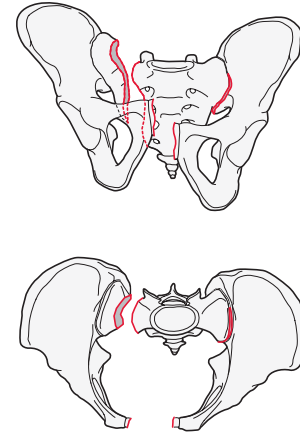
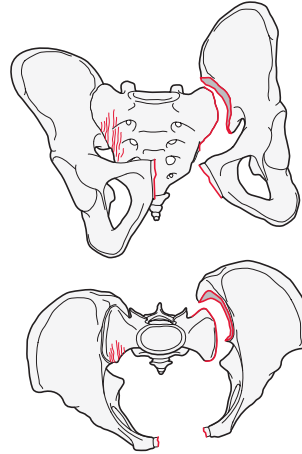
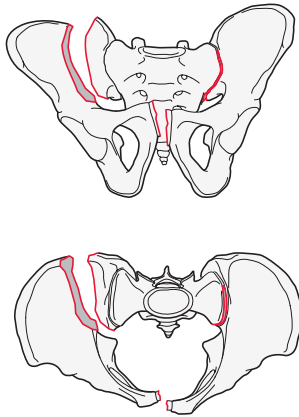
Group: Pelvis, pelvic ring, complete disruption of posterior arch, **bilateral posterior injury, one hemipelvis injury complete disruption, contralateral hemipelvis injury incomplete disruption (LC3)** 61C2

Subgroups:

Complete disruption through ilium
61C2.1*

Complete disruption through sacroiliac joint
61C2.2*

Through the sacrum
61C2.3*



*Qualifications:

- | | |
|--|--|
| a Ipsilateral or unilateral pubic ramus fracture | g Locked symphysis |
| b Bilateral pubic rami fracture | k Contralateral posterior lateral compression lesion: sacrum |
| c Contralateral pubic ramus fracture | l Contralateral posterior lateral compression lesion: ilium (crescent) |
| d Symphysis disruption | m Contralateral posterior external rotation lesion: sacroiliac joint |
| e Parasymphyseal fracture | n Contralateral posterior external rotation lesion: fracture dislocation |
| f Tilt fracture | |

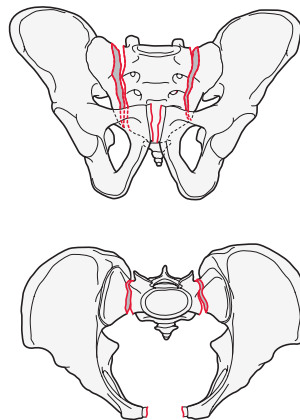
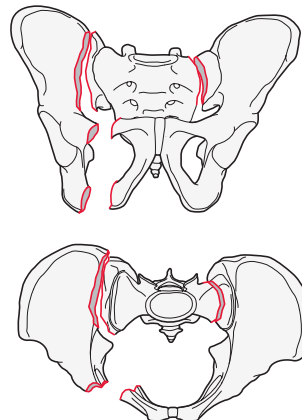
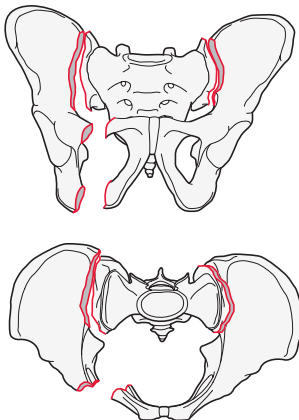
Group: Pelvis, pelvic ring, complete disruption of posterior arch, **bilateral posterior injury, both sides complete disruption (APC3, vertical shear)** 61C3

Subgroups:

Extrasacral on both sides
61C3.1*

Sacral one side, extra sacral other side
61C3.2*

Sacral both sides
61C3.3*



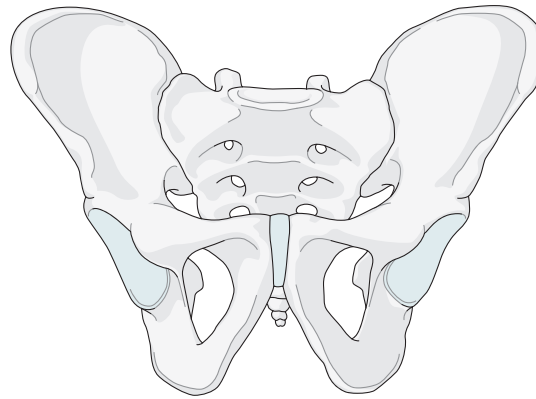
*Qualifications:

- | | |
|--|-------------------------------|
| a Ipsilateral or unilateral pubic ramus fracture | f Tilt fracture |
| b Bilateral pubic rami fracture | g Locked symphysis |
| c Contralateral pubic ramus fracture | h Iliac wing fracture |
| d Symphysis disruption | j Sacroiliac joint disruption |
| e Parasymphyseal fracture | |

Qualifications are optional and applied to the fracture code where the asterisk is located as a lower-case letter within rounded brackets. More than one qualification can be applied for a given fracture classification, separated by a comma. For a more detailed explanation, see the compendium introduction.

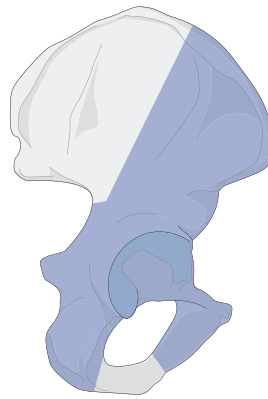
Acetabulum

Bone: Pelvis 6



62

Location: Pelvis, acetabulum 62



Types:

Pelvis, acetabulum, **partial articular, isolated column and/or wall fracture**

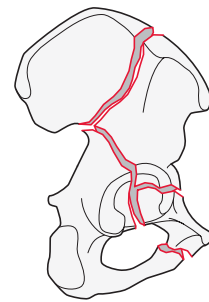
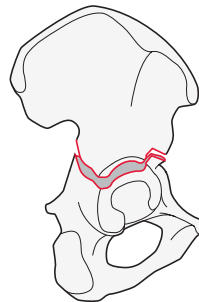
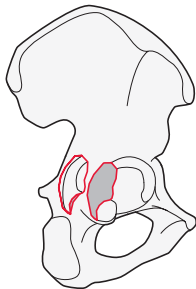
62A

Pelvis, acetabulum, **partial articular, transverse type fracture**

62B

Pelvis, acetabulum, **complete articular, associated both column fracture**

62C



Qualifications are optional and applied to the fracture code where the asterisk is located as a lower-case letter within rounded brackets. More than one qualification can be applied for a given fracture classification, separated by a comma. For a more detailed explanation, see the compendium introduction.

62A

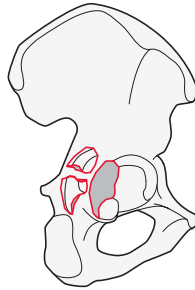
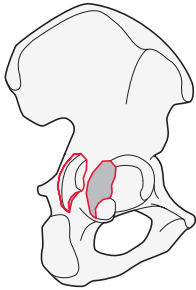
Type: Pelvis, acetabulum, **partial articular, isolated column and/or wall fracture** 62A

Group: Pelvis, acetabulum, partial articular, isolated column and/or wall, **posterior wall fracture** 62A1

Subgroups:

Simple fracture
62A1.1*

Multifragmentary fracture
62A1.2*



*Qualification:
a With marginal impaction

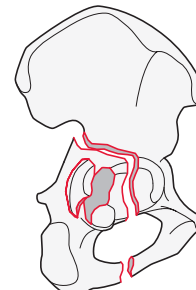
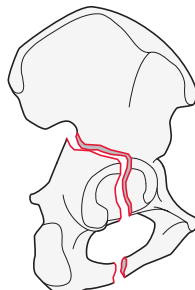
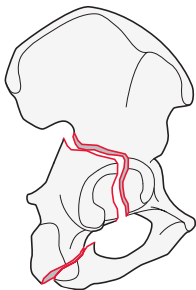
Group: Pelvis, acetabulum, partial articular, isolated column and/or wall, **posterior column fracture** 62A2

Subgroups:

Through the ischium
62A2.1

Through the obturator ring
62A2.2

With associated posterior wall fracture
62A2.3*

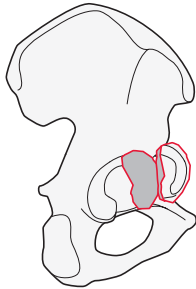


*Qualifications:
h Simple posterior wall fracture
i **Multifragmentary posterior wall fracture**
j Posterior wall fracture with marginal impaction

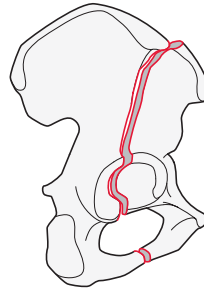
Group: Pelvis, acetabulum, partial articular, isolated column or wall, **anterior column or wall fracture** 62A3

Subgroups:

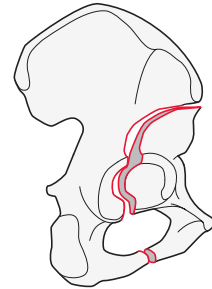
Anterior wall fracture
62A3.1*



High anterior column fracture (exits along iliac crest)
62A3.2*



Low anterior column fracture (exits below anterior superior iliac spine [ASIS])
62A3.3*



*Qualification:
a With marginal impaction

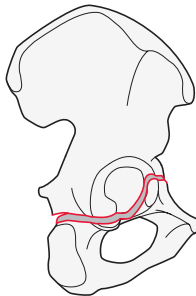
62B

Type: Pelvis, acetabulum, **partial articular, transverse type fracture** 62B

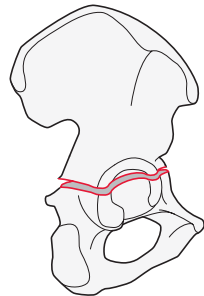
Group: Pelvis, acetabulum, partial articular, transverse type, **transverse fracture** 62B1

Subgroups:

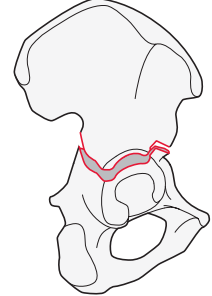
Infratectal fracture
62B1.1*



Juxtatectal fracture
62B1.2*



Transtectal fracture
62B1.3*

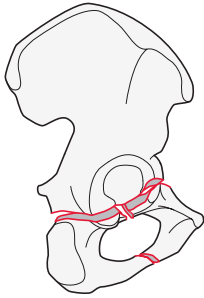


*Qualifications:
b Associated posterior wall fracture
c Associated posterior wall fracture with marginal impaction

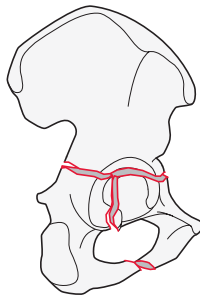
Group: Pelvis, acetabulum, partial articular, transverse type, **T fracture** 62B2

Subgroups:

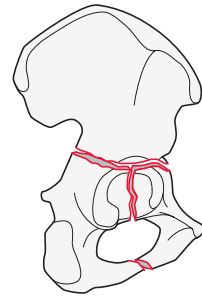
With infratectal transverse component
62B2.1*



With juxtatectal transverse component
62B2.2*



With transtectal transverse component
62B2.3*



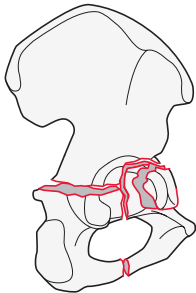
*Qualifications:

- b Associated posterior wall fracture
- c Associated posterior wall fracture with marginal impaction

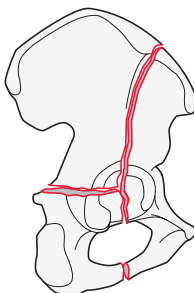
Group: Pelvis, acetabulum, partial articular, transverse type, **with anterior column, posterior hemitransverse fracture** 62B3

Subgroups:

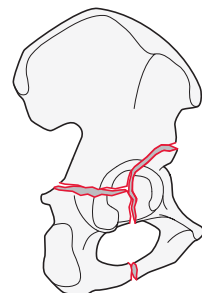
Associated with anterior wall
62B3.1



High anterior column fracture (exits along iliac crest)
62B3.2



Low anterior column fracture (exits below anterior superior iliac spine [ASIS])
62B3.3



62C

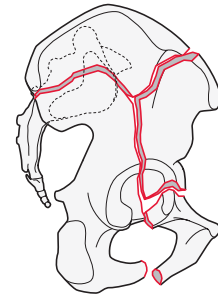
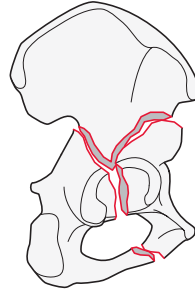
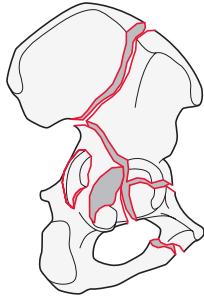
Type: Pelvis, acetabulum, complete articular, **associated both column fracture**

Groups:

Pelvis, acetabulum, complete articular, both columns, **high anterior column fracture (exits along iliac crest)**
62C1*

Pelvis, acetabulum, complete articular, both columns, **low anterior column fracture (exits below anterior superior iliac spine [ASIS])**
62C2*

Pelvis, acetabulum, complete articular, both columns, **involving the sacroiliac (SI) joint**
62C3*



*Qualifications:

- d Both columns simple
- e Multifragmentary anterior column
- f **Multifragmentary posterior column**
- g Both columns multifragmentary

*Qualifications:

- d **Both columns simple**
- e Multifragmentary anterior column
- f Multifragmentary posterior column
- g Both columns multifragmentary

*Qualifications:

- d **Both columns simple**
- e Multifragmentary anterior column
- f Multifragmentary posterior column
- g Both columns multifragmentary

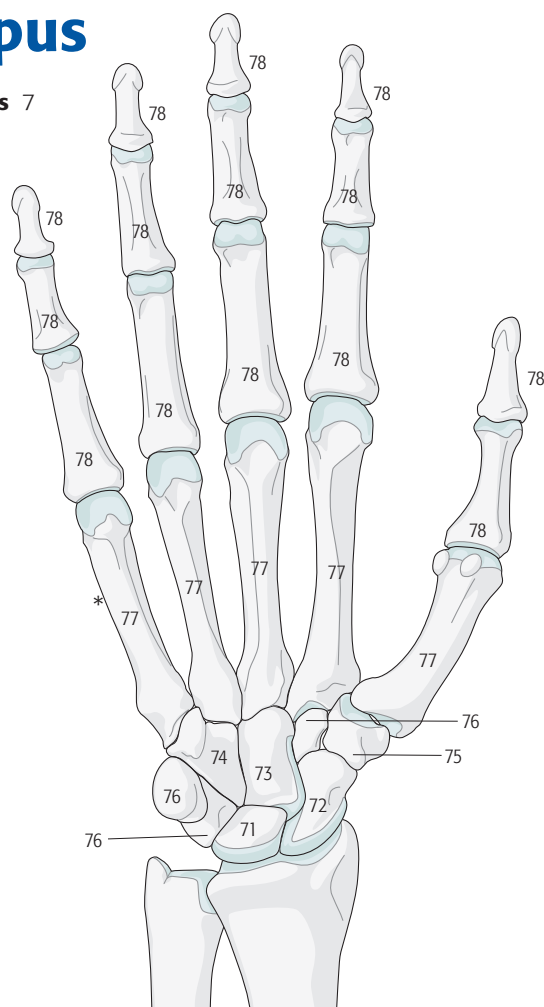
Based on the Letournel Classification of Acetabular Fractures:

Letournel E, Judet R. *Fractures of the Acetabulum*. Berlin: Springer-Verlag; 1993.

Qualifications are optional and applied to the fracture code where the asterisk is located as a lower-case letter within rounded brackets. More than one qualification can be applied for a given fracture classification, separated by a comma. For a more detailed explanation, see the compendium introduction.

Hand and carpus

Anatomical region: Hand and carpus 7



Bones:

- Hand and carpus, **Lunate** 71
- Hand and carpus, **Scaphoid** 72
- Hand and carpus, **Capitate** 73
- Hand and carpus, **Hamate** 74
- Hand and carpus, **Trapezium** 75
- Hand and carpus, **Other carpal bones** 76
- Hand and carpus, **Metacarpal** 77
- Hand and carpus, **Phalanx** 78
- Hand and carpus, **Crushed, multiple fractures** 79

Qualifications are optional and applied to the fracture code where the asterisk is located as a lower-case letter within rounded brackets. More than one qualification can be applied for a given fracture classification, separated by a comma. For a more detailed explanation, see the compendium introduction.

Lunate 71

Bone: Hand and carpus, **lunate** 71

Types:

Hand and carpus, lunate,
avulsion fracture
71A

Hand and carpus, lunate,
simple fracture
71B

Hand and carpus, lunate,
multifragmentary fracture
71C

Scaphoid 72

Bone: Hand and carpus, **scaphoid** 72

Types:

Hand and carpus, scaphoid,
avulsion fracture
72A

Hand and carpus, scaphoid,
simple fracture
72B*

Hand and carpus, scaphoid,
multifragmentary fracture
72C*

*Qualifications:

- a Proximal pole
- b Waist
- c Distal pole

Capitate 73

Bone: Hand and carpus, **capitate** 73

Types:

Hand and carpus, capitate,
avulsion fracture
73A

Hand and carpus, capitate,
simple fracture
73B

Hand and carpus, capitate,
multifragmentary fracture
73C

Hamate 74

Bone: Hand and carpus, **hamate** 74

Types:

Hand and carpus, hamate,
hook fracture
74A

Hand and carpus, hamate,
simple fracture
74B

Hand and carpus, hamate,
multifragmentary fracture
74C

Trapezium 75

Bone: Hand and carpus, **trapezium** 75

Types:

Hand and carpus, trapezium,
avulsion fracture
75A

Hand and carpus, trapezium,
simple fracture
75B

Hand and carpus, trapezium,
multifragmentary fracture
75C

Other 76.__.

Bone: Hand and carpus, **other** 76.__.

Pisiform

76.1.

Triquetrum

76.2.

Trapezoid

76.3.

→ The bone identifier (between two dots __.) is added to the code after the anatomical region.

76.1

Hand and carpus, **pisiform** 76.1.

Type:

Hand and carpus, other, pisiform,

avulsion fracture

76.1.A

Hand and carpus, other, pisiform,

simple fracture

76.1.B

Hand and carpus, other, pisiform,

multifragmentary fracture

76.1.C

76.2

Hand and carpus, **triquetrum** 76.2.

Type:

Hand and carpus, other, triquetrum,

avulsion fracture

76.2.A

Hand and carpus, other, triquetrum,

simple fracture

76.2.B

Hand and carpus, other, triquetrum,

multifragmentary fracture

76.2.C

76.3

Hand and carpus, **trapezoid** 76.3.

Type:

Hand and carpus, other, trapezoid,

avulsion fracture

76.3.A

Hand and carpus, other, trapezoid,

simple fracture

76.3.B

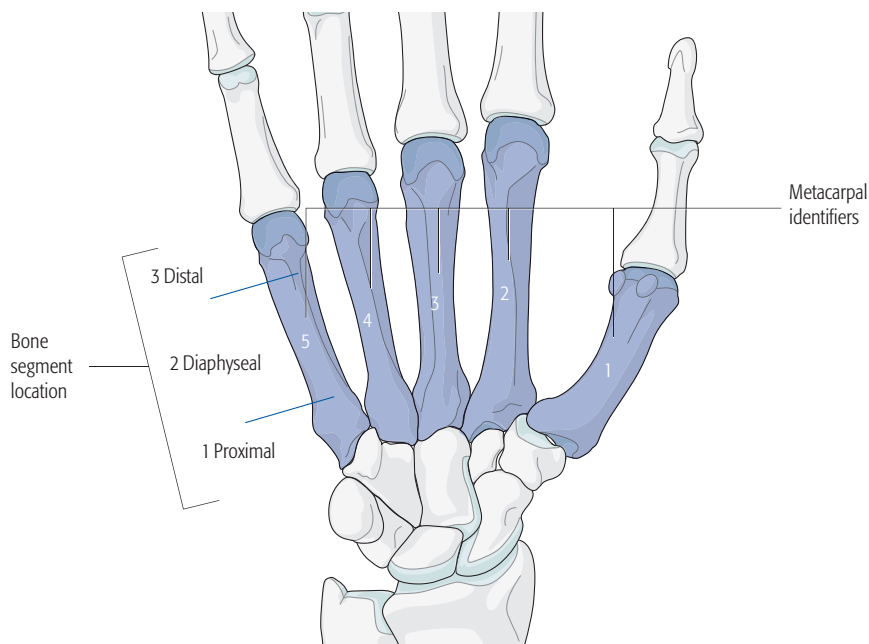
Hand and carpus, other, trapezoid,

multifragmentary fracture

76.3.C

Metacarpals 77.____.

Bone: Hand and carpus, **metacarpal** 77.____.



- The metacarpal bones are identified as follows: Thumb = 1, index = 2, long or middle = 3, ring = 4, and little = 5.
- The metacarpal identifier is added (between two dots .__) after the bone code.
- The bone segment location is then added.
- Example: Hand, 3rd metacarpal, proximal end segment = 77.3.1

Location: Hand and carpus, metacarpal, **proximal end segment** 77.____.1

- Example code for the 3rd metacarpal is indicated with an underline 77.3.1

Types:

Hand and carpus, metacarpal, proximal end segment, **extraarticular fracture**
77.3.1A

Hand and carpus, metacarpal, proximal end segment, **partial articular fracture**
77.3.1B

Hand and carpus, metacarpal, proximal end segment, **complete articular fracture**
77.3.1C

Location: Hand and carpus, metacarpal, **diaphyseal fracture** 77.____.2

- Example code for the 3rd metacarpal is indicated with an underline 77.3.2

Types:

Hand and carpus, metacarpal, diaphyseal, **simple fracture**
77. 3.2A

Hand and carpus, metacarpal, diaphyseal, **wedge fracture**
77. 3.2B

Hand and carpus, metacarpal, diaphyseal, **multifragmentary fracture**
77. 3.2C

Location: Hand and carpus, metacarpal, **distal end segment** 77.____.3

- Example code for the 3rd metacarpal is indicated with an underline 77.3.3

Types:

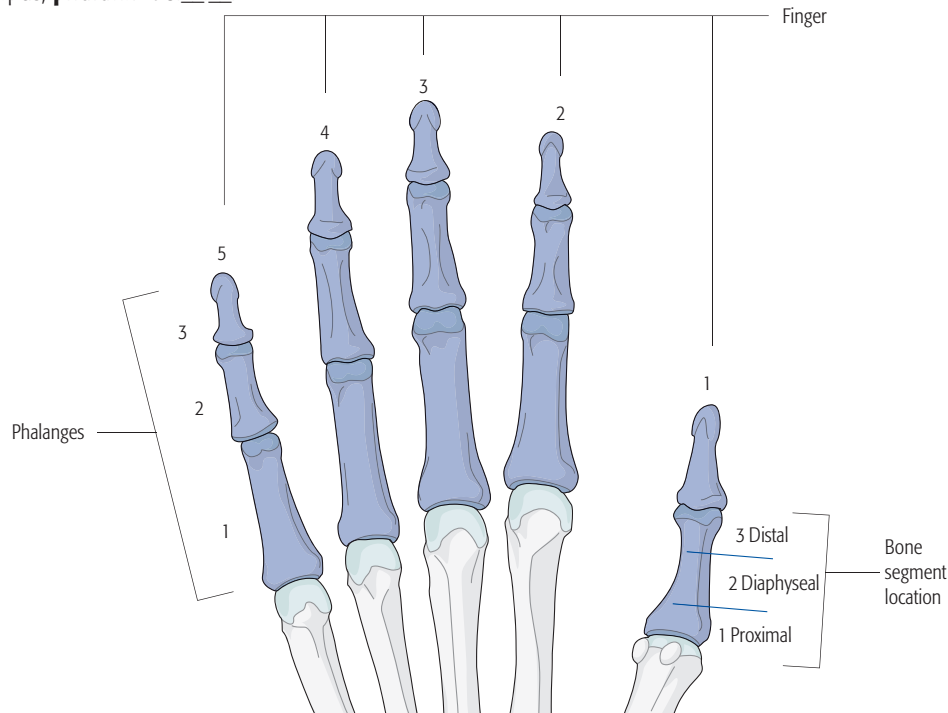
Hand and carpus, metacarpal, distal end segment, **extraarticular fracture**
77. 3.3A

Hand and carpus, metacarpal, distal end segment, **partial articular fracture**
77. 3.3B

Hand and carpus, metacarpal, distal end segment, **complete articular fracture**
77. 3.3C

Phalanx 78. . . .

Bone: Hand and carpus, **phalanx** 78. . . .



- The fingers and phalanges are identified as follows:
 Fingers: Thumb = 1, index = 2, long or middle = 3, ring = 4, and little = 5.
 Phalanges: Proximal phalanx = 1, middle phalanx = 2, and distal phalanx = 3.
 The finger identifier plus phalanx identifier are added (between dots) after the bone code.
- Example: Proximal thumb phalanx is 78.1.1.
- The location is then added.
- **Anatomical region+bone.Finger.Phalanx.Bone segment location**
- Example: Proximal thumb phalanx proximal end segment is 78.1.1.1

Location: Hand and carpus, phalanx, **proximal end segment** 78.1.1.1
 → Example code for proximal thumb phalanx is indicated with an underline 78.1.1.1

Types: Hand and carpus, phalanx, proximal end segment, extraarticular fracture 78.1.1.1A	Hand and carpus, phalanx, proximal end segment, partial articular fracture 78.1.1.1B	Hand and carpus, phalanx, proximal end segment, complete articular fracture 78.1.1.1C
--	--	---

Location: Hand and carpus, phalanx **diaphyseal fracture** 78.1.1.2
 → Example code for proximal thumb phalanx is indicated with an underline 78.1.1.2

Types: Hand and carpus, phalanx, diaphyseal, simple fracture 78.1.1.2A	Hand and carpus, phalanx, diaphyseal, wedge fracture 78.1.1.2B	Hand and carpus, phalanx, diaphyseal, multifragmentary fracture 78.1.1.2C
--	--	---

Location: Hand and carpus, phalanx, **distal end segment** 78.1.1.3
 → Example code for proximal thumb phalanx is indicated with an underline 78.1.1.3

Types: Hand and carpus, phalanx, distal end segment, extraarticular fracture 78.1.1.3A	Hand and carpus, phalanx, distal end segment, partial articular fracture 78.1.1.3B	Hand and carpus, phalanx, distal end segment, complete articular fracture 78.1.1.3C
--	--	---

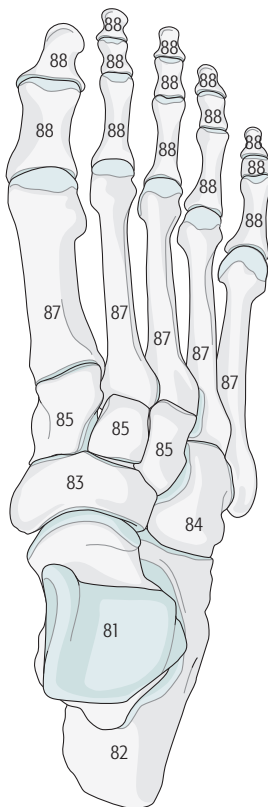
Crushed, multiple fractures 79

Hand and carpus, **crush, multiple fractures hand** 79

Qualifications are optional and applied to the fracture code where the asterisk is located as a lower-case letter within rounded brackets. More than one qualification can be applied for a given fracture classification, separated by a comma. For a more detailed explanation, see the compendium introduction.

Foot

Anatomical region: Foot 8



Bones:

- Foot, **Talus** 81
- Foot, **Calcaneus** 82
- Foot, **Navicular** 83
- Foot, **Cuboid** 84
- Foot, **Cuneiforms** 85
- Foot, **Metatarsals** 87
- Foot, **Phalanges** 88
- Foot, **Crush, multiple foot fractures** 89

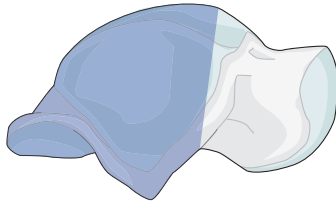
Qualifications are optional and applied to the fracture code where the asterisk is located as a lower-case letter within rounded brackets. More than one qualification can be applied for a given fracture classification, separated by a comma. For a more detailed explanation, see the compendium introduction.

Talus 81

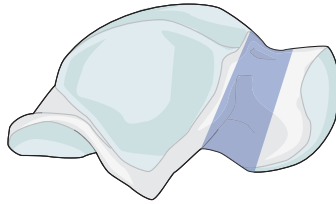
Bone: Foot, **talus** 81

Locations:

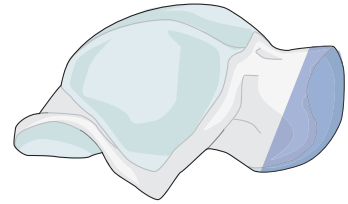
Foot, talus, **body**
81.1.



Foot, talus, **neck**
81.2.



Foot, talus, **head**
81.3.



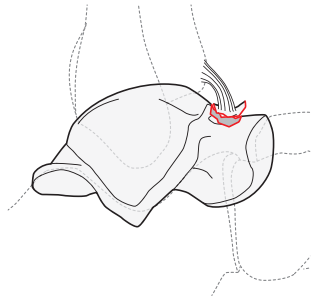
→ The talus is anatomically identified as follows: body = 1, neck = 2, and head = 3.
→ The talar anatomical division is added (between two dots ._.) after the bone code.

81.1.

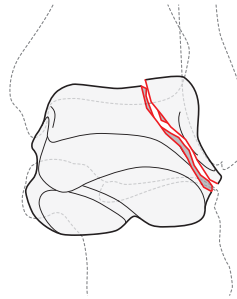
Location: Foot, talus, **body** 81.1.

Types:

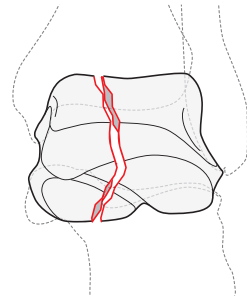
Foot, talus, body, **avulsion fracture**
81.1.A



Foot, talus, body, **partial articular fracture**
81.1.B



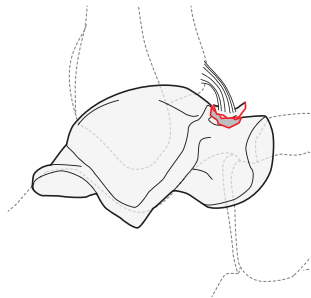
Foot, talus, body, **complete articular fracture**
81.1.C



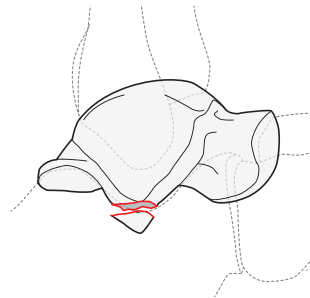
Type: Foot, talus, body, **avulsion fracture** 81.1.A

Groups:

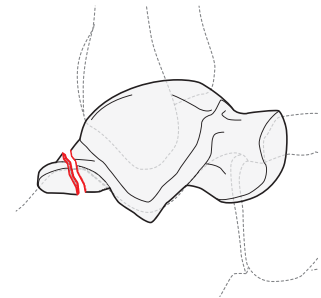
Foot, talus, body, avulsion fracture,
anterior neck
81.1.A1



Foot, talus, body, avulsion fracture,
lateral process
81.1.A2

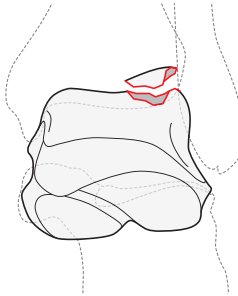


Foot, talus, body, avulsion fracture,
posterior process
81.1.A3

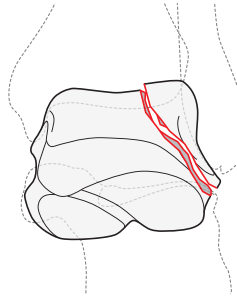


Type: Foot, talus, body, **partial articular fracture** 81.1.B

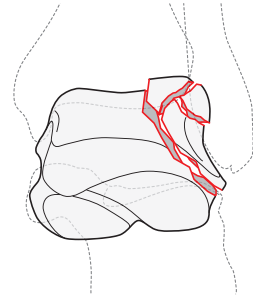
Groups:
Foot, talus, body, partial articular,
osteochondral fracture
81.1.B1



Foot, talus, body, partial articular,
simple fracture
81.1.B2

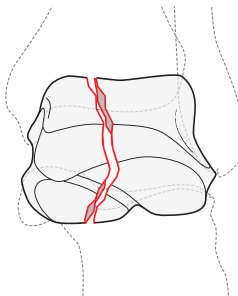


Talus, body, partial articular,
fragmentary fracture
81.1.B3

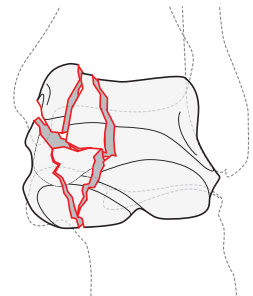


Type: Foot, talus, body, **complete articular fracture** 81.1.C

Groups:
Foot, talus, body, complete articular,
simple fracture
81.1.C1



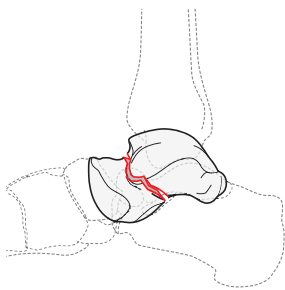
Foot, talus, body, complete articular,
multifragmentary fracture
81.1.C3



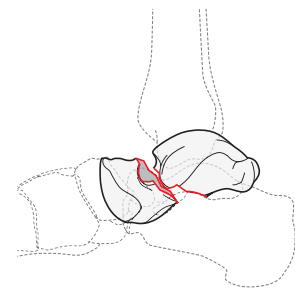
81.2.

Location: Foot, talus, **neck fracture** 81.2.

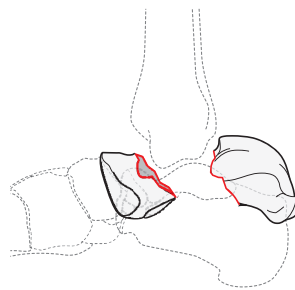
Types:
Foot, talus, neck, **nondisplaced**
(Hawkins 1)
81.2.A



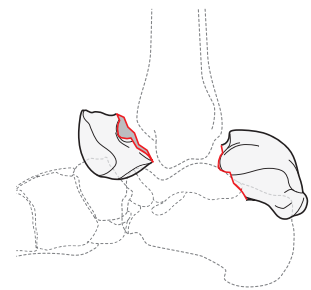
Foot, talus, neck, **displaced with**
subtalar joint subluxation/dis-
location (Hawkins 2)
81.2.B*



Foot, talus, neck, **displaced talar**
neck with talar body disloca-
tion (Hawkins 3)
81.2.C*



Foot, talus, neck, **displaced talar**
neck with talar body and head
dislocation (Hawkins 4)
81.2.D*



*Qualifications:

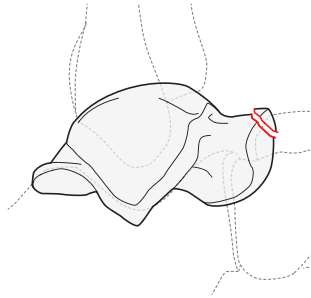
- a **Simple**
- b Multifragmentary

81.3.

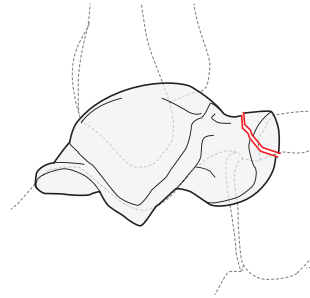
Location: Talus, **head** 81.3.

Types:

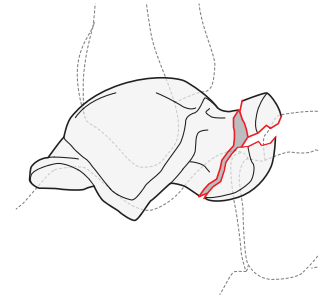
Talus, head, **avulsion fracture**
81.3.A



Talus, head, **partial articular fracture**
81.3.B*



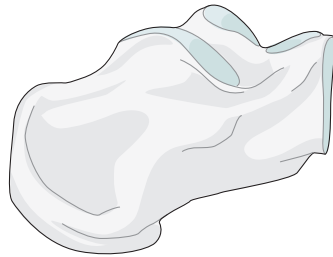
Talus, head, **complete articular fracture**
81.3.C*



*Qualifications:
a Simple
b Multifragmentary

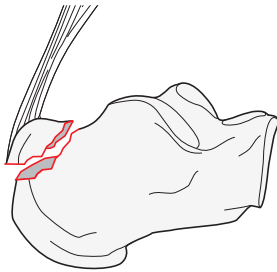
Calcaneus 82

Bone: Foot, **calcaneus** 82

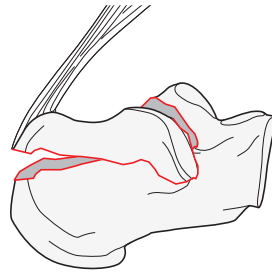


Types:

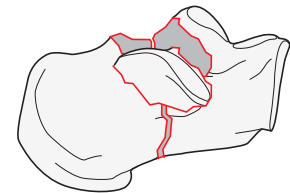
Foot, calcaneus, **extraarticular fracture**
82A



Foot, calcaneus, **tongue-type fracture exiting into posterior facet**
82B



Foot, calcaneus, **complete articular joint depression**
82C

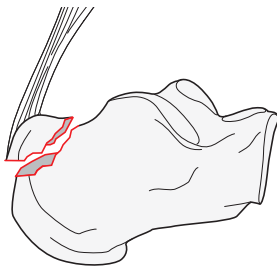


82A

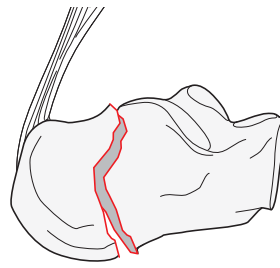
Type: Foot, calcaneus, **extraarticular fracture** 82A

Groups:

Foot calcaneus, extraarticular, **avulsion, posterior tuberosity fracture or extraarticular tongue fracture**
82A1



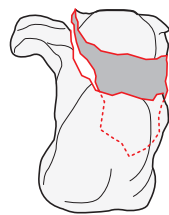
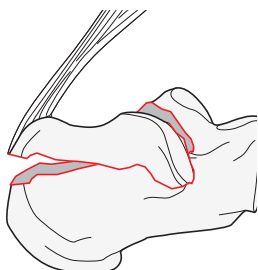
Foot calcaneus, extraarticular, **body fracture**
82A2



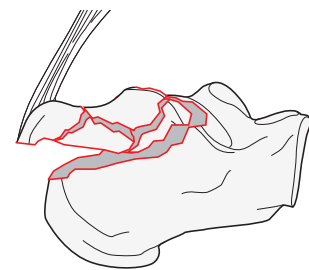
82B

Types: Foot, calcaneus, **tongue-type fracture exiting into posterior facet** 82B

Foot, calcaneus, tongue-type fracture exiting into posterior facet, **tongue-type, simple fracture**
82B1



Foot, calcaneus, tongue-type fracture exiting into posterior facet, **multifragmentary fracture**
82B3



82C

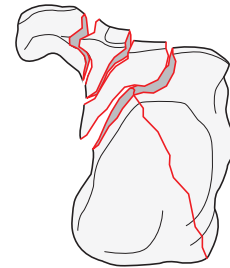
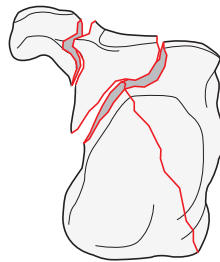
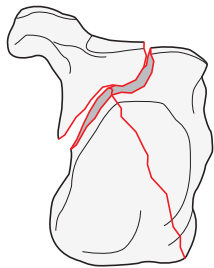
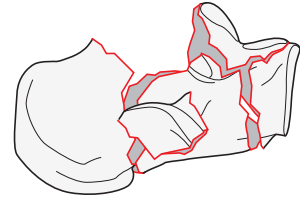
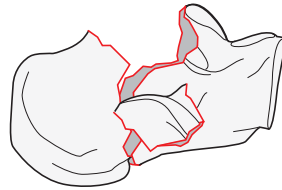
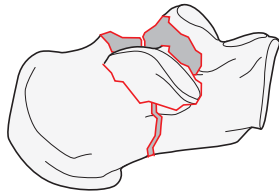
Type: Foot, calcaneus, **complete articular joint depression fracture** 82C

Groups:

Foot, calcaneus, complete articular fracture,
with joint depression (Sanders 2)
82C1

Foot, calcaneus, complete articular fracture,
with joint depression (Sanders 3)
82C2

Foot, calcaneus, complete articular fracture,
multifragmentary fracture (Sanders 4)
82C3

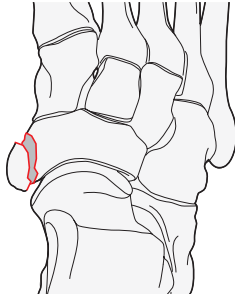


Navicular 83

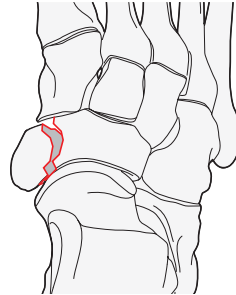
Bone: Foot, **navicular** 83

Types:

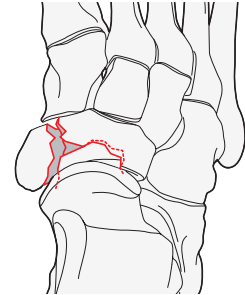
Foot, navicular, **avulsion fracture**
83A



Foot, navicular, **partial articular fracture**
83B*



Foot, navicular, **complete articular fracture**
83C*



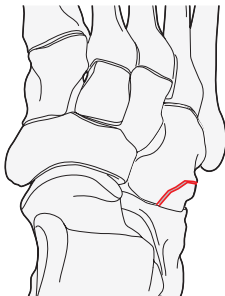
*Qualifications:
a Simple
b Multifragmentary

Cuboid 84

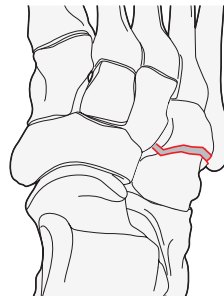
Bone: Foot, **cuboid** 84

Types:

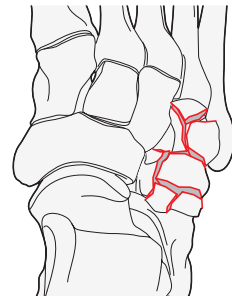
Foot, cuboid, **avulsion fracture**
84A



Foot, cuboid, **partial articular fracture**
84B*



Foot, cuboid, **complete articular fracture**
84C*



*Qualifications:
a Simple
b Multifragmentary

Cuneiform 85.____.

Bone: Foot, **cuneiform** 85.____.

Locations:

Foot, cuneiform, **medial**
85.1.

Foot, cuneiform, **middle**
85.2.

Foot, cuneiform, **lateral**
85.3.

→ The cuneiform locations are identified as follows: medial = 1, middle = 2, and lateral = 3.
→ The cuneiform location is added (between two dots .____) after the bone code.

85.1.

Types:

Foot, cuneiform, medial,
avulsion fracture
85.1.A

Foot, cuneiform, medial,
partial articular fracture
85.1.B

Foot, cuneiform, medial,
complete articular fracture
85.1.C

85.2.

Types:

Foot, cuneiform, middle,
avulsion fracture
85.2.A

Foot, cuneiform, middle,
partial articular fracture
85.2.B

Foot, cuneiform, middle,
complete articular fracture
85.2.C

85.3.

Types:

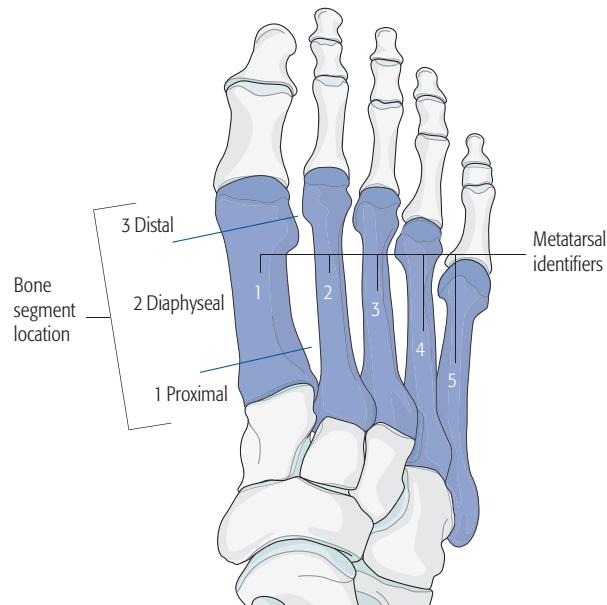
Foot, cuneiform, lateral,
avulsion fracture
85.3.A

Foot, cuneiform, lateral,
partial articular fracture
85.3.B

Foot, cuneiform, lateral
complete articular fracture
85.3.C

Metatarsals 87

Bone: Foot, **metatarsal** 87



- The metatarsal bones are identified as follows: First metatarsal = 1, second metatarsal = 2, third metatarsal = 3, fourth metatarsal = 4, fifth metatarsal = 5.
- The metatarsal identifier is added (between two dots .__.) after the bone code.
- The bone segment location is then added.
- Example: Foot, third metatarsal, proximal end segment = 87.3.1

Locations:

Foot, metatarsal,
proximal end segment
87.__.1

Foot, metatarsal,
diaphyseal segment
87.__.2

Foot, metatarsal,
distal end segment
87.__.3

87.__.1

Location: Foot, metatarsal, **proximal end segment** 87.__.1

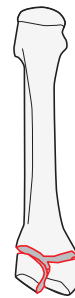
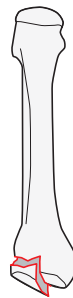
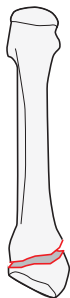
→ Example code for the third metatarsal is indicated with an underline 87.3.1

Types:

Foot, metatarsal, proximal end segment,
extraarticular fracture
87.3.1A*

Foot, metatarsal, proximal end segment,
partial articular fracture
87.3.1B*

Foot, metatarsal, proximal end segment,
complete articular fracture
87.3.1C*



*Qualifications:
a **Simple**
b Multifragmentary

87.__.2

Location: Foot, metatarsal, **diaphyseal segment** 87.3.2

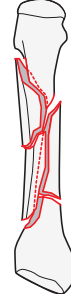
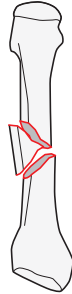
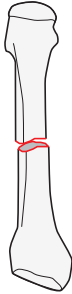
→ Example code for the third metatarsal is indicated with an underline 87.3.2

Types:

Foot, metatarsal, diaphyseal segment,
simple fracture
87.3.2A

Foot, metatarsal, diaphyseal segment,
wedge fracture
87.3.2B

Foot, metatarsal, diaphyseal segment,
multifragmentary fracture
87.3.2C



87.__.3

Location: Foot, metatarsal, **distal end segment** 87.__.3

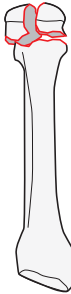
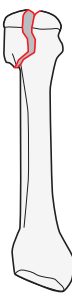
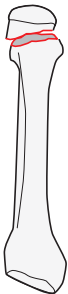
→ Example code for the third metatarsal is indicated with an underline 87.3.3

Types:

Foot, metatarsal, distal end segment,
extraarticular fracture
87.3.3A*

Foot, metatarsal, distal end segment,
partial articular fracture
87.3.3B*

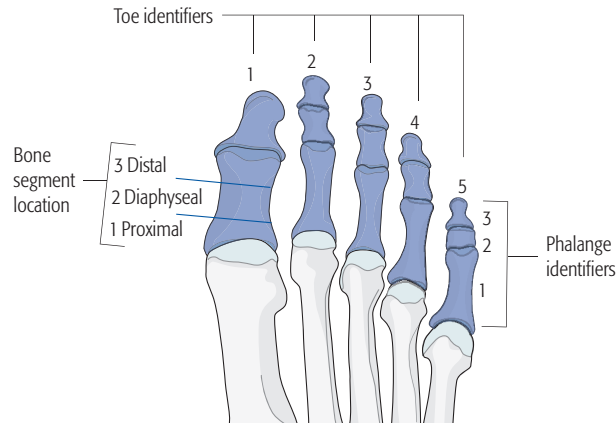
Foot, metatarsal, distal end segment,
complete articular fracture
87.3.3C*



*Qualifications:
a **Simple**
b Multifragmentary

Phalanx 88

Bone: Foot, **phalanx** 88



→ The toes and phalanges are identified as follows:

Toes: First or great toe = 1, second toe = 2, third toe = 3, fourth toe = 4, and fifth toe = 5.

Phalanges: Proximal phalanx = 1, middle phalanx = 2, and distal phalanx = 3.

→ The toe identifier plus phalanx identifier are added (between dots) after the bone code.

→ Example: Great toe, middle phalanx fracture is 88.1.2.

→ The phalangeal bone segment location is then added.

→ **Anatomical region+bone.Toe.Phalanx.Bone segment location+Type**

→ Example: Great toe, middle phalanx, proximal end segment is 88.1.2.1

Locations:

Foot, phalanx

proximal end segment

88. . . .1

Foot, phalanx

diaphyseal segment

88. . . .2

Foot, phalanx

distal end segment

88. . . .3

88. . . .1

Location: Foot, phalanx, **proximal end segment** 88.1.2.1

→ Example code for the proximal great toe is indicated with an underline 88.1.2.1

Types:

Foot, phalanx proximal end segment,
extraarticular fracture

88.1.2.1A

Foot, phalanx proximal end segment,
partial articular fracture

88.1.2.1B

Foot, phalanx proximal end segment,
complete articular fracture

88.1.2.1C

88. . . .2

Location: Foot, phalanx, **diaphyseal segment** 88.1.2.2

→ Example code for the proximal great toe is indicated with an underline 88.1.2.2

Types:

Foot, phalanx, diaphyseal segment,
simple fracture

88.1.2.2A

Foot, phalanx, diaphyseal segment,
wedge fracture

88.1.2.2B

Foot, phalanx, diaphyseal segment,
multifragmentary fracture

88.1.2.2C

88. . . .3

Location: Foot, phalanx, **distal end segment** 88.1.2.3

→ Example code for the proximal great toe is indicated with an underline 88.1.2.3

Types:

Foot, phalanx, distal end segment,
extraarticular fracture

88.1.2.3A

Foot, phalanx, distal end segment,
partial articular fracture

88.1.2.3B

Foot, phalanx, distal end segment,
complete articular fracture

88.1.2.3C

89

Location: Foot, **crush, multiple fractures whole foot** 89

Types:

Foot, crush, multiple fractures,

hindfoot

89A

Foot, crush, multiple fractures,

midfoot

89B

Foot, crush, multiple fractures,

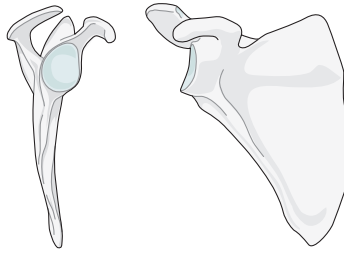
forefoot

89C

Qualifications are optional and applied to the fracture code where the asterisk is located as a lower-case letter within rounded brackets. More than one qualification can be applied for a given fracture classification, separated by a comma. For a more detailed explanation, see the compendium introduction.

Scapula

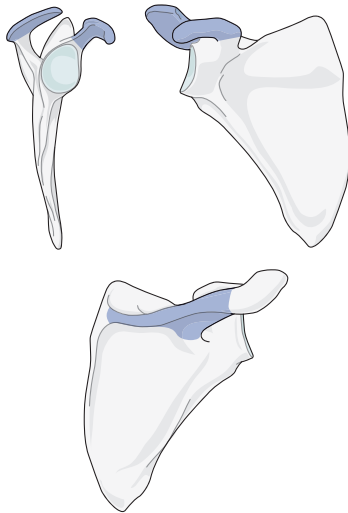
Bone: Scapula 14



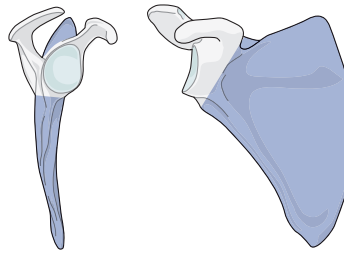
14

Locations:

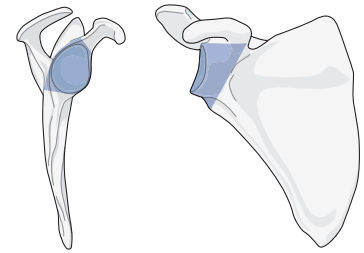
Scapula, **process**
14A



Scapula, **body**
14B*



Scapula, **glenoid fossa**
14F*



* Qualifications for process fractures:

- x Coracoid P1
- y Acromion P2
- z Both processes P3

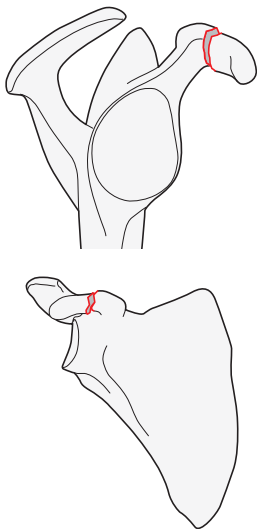
(These qualifications may be added to any fracture coded as type B or type F)

14A

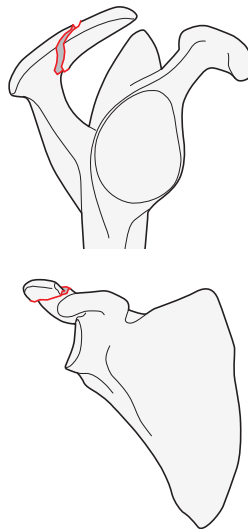
Location: Scapula, **process** 14A

Types:

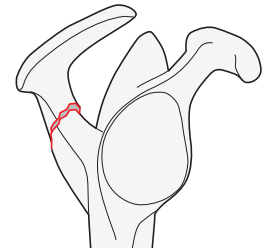
Scapula, process, **coracoid fracture**
14A1



Scapula, process, **acromion fracture**
14A2



Scapula, process, **spine fracture**
14A3



Qualifications are optional and applied to the fracture code where the asterisk is located as a lower-case letter within rounded brackets. More than one qualification can be applied for a given fracture classification, separated by a comma. For a more detailed explanation, see the compendium introduction.

14B

Location: Scapula, **body** 14B

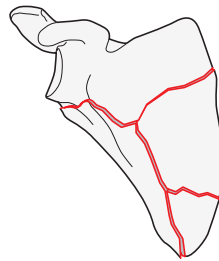
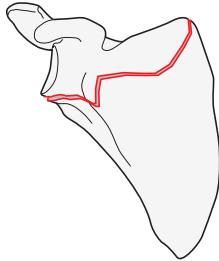
Types:

Scapula, body, **fracture exits the body at 2 or less points**

14B1*

Scapula, body, **fracture exits the body at 3 or more points**

14B2*



Qualifications:

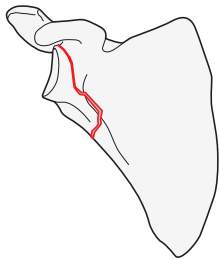
- l Lateral border fracture exit
- m Medial border fracture exit
- s Superior border fracture exit
- g Area immediately lateral to base of coracoid (glenoid side exit)

14F

Location: Scapula, **glenoid fossa** 14F

Type:

Scapula, glenoid fossa, **through the extraarticular subchondral bone of the glenoid fossa (glenoid neck)** 14F0



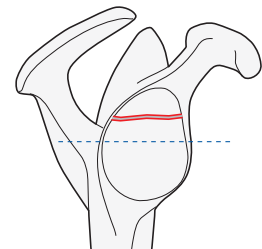
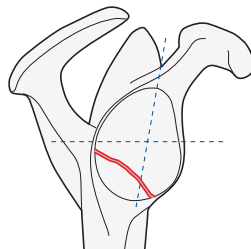
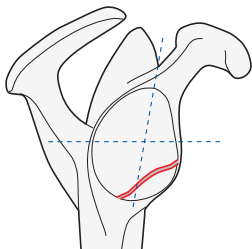
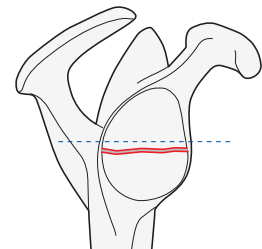
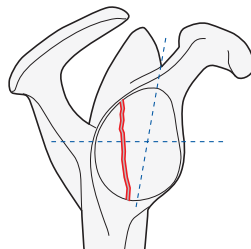
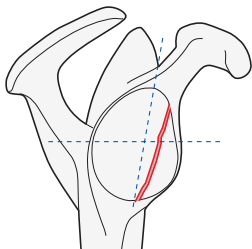
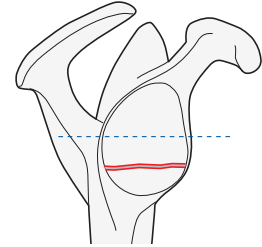
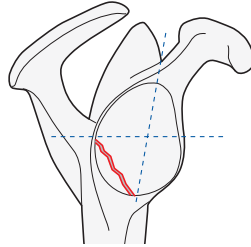
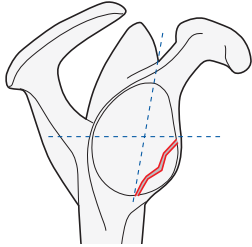
Type: Scapula, glenoid fossa, **simple fracture** 14F1

Groups:

Scapula, glenoid fossa, simple,
anterior rim fracture
14F1.1*

Scapula, glenoid fossa, simple,
posterior rim fracture
14F1.2*

Scapula, glenoid fossa, simple,
transverse or short oblique fracture
14F1.3*



*Qualifications:

- f Infraequatorial rim fracture located in lower quadrant
- r Rim fracture anterior or posterior to maximum glenoid meridian with exits superior and inferior to the glenoid equatorial line
- t Fracture is located in two infraequatorial anterior and posterior quadrants with side of fracture defined by the center of fracture line

*Qualifications:

- i Infraequatorial
- e Equatorial
- p Supraequatorial

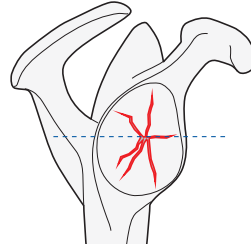
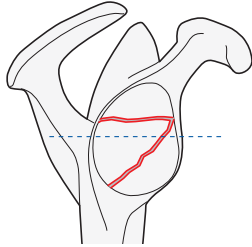
→ For more information about the four glenoid fossa quadrants, please refer to the Appendix.

Type: Scapula, glenoid fossa, **multifragmentary (three or more fracture lines)** 14F2

Groups:

Scapula, glenoid fossa, multifragmentary (3 or more articular fragments), **glenoid fossa fracture**
14F2.1

Scapula, glenoid fossa, multifragmentary (3 or more articular fragments with rim exits), **central fracture dislocation**
14F2.2



NOTE: Glenoid fractures with extension into the body are classified as a glenoid fracture, with the body fracture code added to the end of the code in square brackets [].

References

Audige L, Kellam JF, Lambert S, et al. The AO Foundation and Orthopaedic Trauma Association (AO/OTA) scapula fracture classification system: focus on body involvement. *J Shoulder Elbow Surg.* 2014 Feb;23(2):189–196.

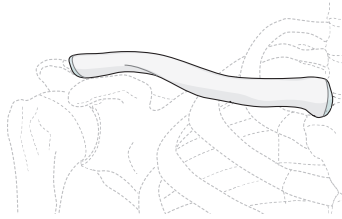
Harvey E, Audige L, Herscovici D, Jr, et al. Development and validation of the new international classification for scapula fractures. *J Orthop Trauma.* 2012 Jun;26(6):364–369.

Jaeger M, Lambert S, Sudkamp NP, et al. The AO Foundation and Orthopaedic Trauma Association (AO/OTA) scapula fracture classification system: focus on glenoid fossa involvement. *J Shoulder Elbow Surg.* 2013 Apr;22(4):512–520.

Qualifications are optional and applied to the fracture code where the asterisk is located as a lower-case letter within rounded brackets. More than one qualification can be applied for a given fracture classification, separated by a comma. For a more detailed explanation, see the compendium introduction.

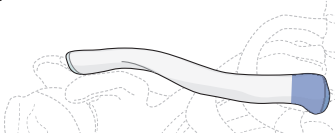
Clavicle

Bone: Clavicle 15



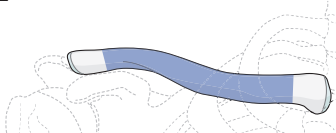
Locations:

Clavicle, **proximal (medial) end segment**
15.1



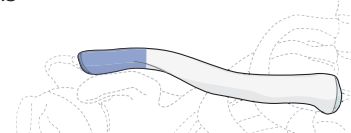
Location is determined by a square with sides the length of the widest portion of the medial end of the clavicle.

Clavicle, **diaphyseal segment**
15.2



The portion between the two end segments.

Clavicle, **distal (lateral) end segment**
15.3

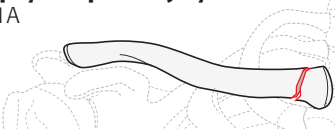

Begins at line perpendicular to the medial edge of the coracoid process. The coracoclavicular ligaments are part of this lateral end segment.

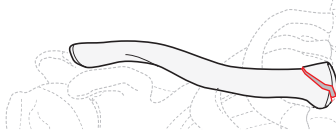
Location: Clavicle, **proximal (medial) end segment** 15.1

Types:

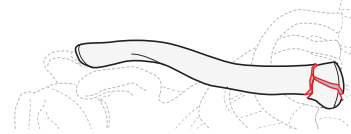Clavicle, proximal (medial) end segment, **extraarticular fracture including epiphyseal plate injury**
15.1A



Clavicle, proximal (medial) end segment, **partial articular fracture**
15.1B



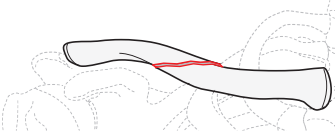
Clavicle, proximal (medial) end segment, **complete articular fracture**
15.1C



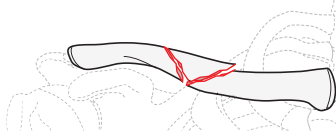
Location: Clavicle, **diaphyseal segment** 15.2

Types:

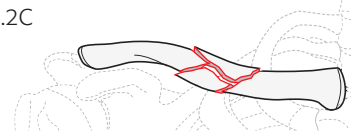
Clavicle, diaphyseal, **simple fracture**
15.2A



Clavicle, diaphyseal, **wedge fracture**
15.2B



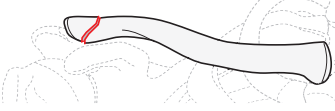
Clavicle, diaphyseal, **multifragmentary fracture**
15.2C



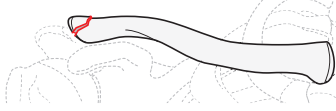
Location: Clavicle, **distal (lateral) end segment** 15.3

Types:

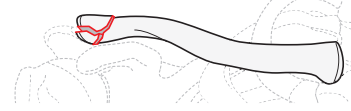
Clavicle, distal (lateral) end segment, **extraarticular fracture**
15.3A*



Clavicle, distal (lateral) end segment, **partial articular fracture**
15.3B*



Clavicle, distal (lateral) end segment, **complete articular fracture**
15.3C*



*Qualifications:

- a CC ligament complex intact
- b CC ligament complex, partial disruption
- c CC ligament complex, complete disruption

Qualifications are optional and applied to the fracture code where the asterisk is located as a lower-case letter within rounded brackets. More than one qualification can be applied for a given fracture classification, separated by a comma. For a more detailed explanation, see the compendium introduction.

OTA Open Fracture Classification (OTA-OFC)

The open fracture classification was developed by the OTA classification committee to address the limitation of the Gustilo-Anderson classification. The OTA-OFC is designed to be used at the time of initial debridement by the treating surgeon. It is generic, usable on all anatomical areas, and focused on factors related to injury not treatment.

Skin	<ol style="list-style-type: none">1. Laceration with edges that approximate.2. Laceration with edges that do not approximate.3. Laceration associated with extensive degloving.
Muscle	<ol style="list-style-type: none">1. No appreciable muscle necrosis, some muscle injury with intact muscle function.2. Loss of muscle but the muscle remains functional, some localized necrosis in the zone of injury that requires excision, intact muscle-tendon unit.3. Dead muscle, loss of muscle function, partial or complete compartment excision, complete disruption of a muscle-tendon unit, muscle defect does not reapproximate.
Arterial	<ol style="list-style-type: none">1. No major vessel disruption.2. Vessel injury without distal ischemia.3. Vessel injury with distal ischemia.
Contamination	<ol style="list-style-type: none">1. None or minimal contamination.2. Surface contamination (not ground in).3. Contaminant embedded in bone or deep soft tissues or high-risk environmental conditions (eg, barnyard, fecal, dirty water).
Bone loss	<ol style="list-style-type: none">1. None.2. Bone missing or devascularized bone fragments, but still some contact between proximal and distal fragments.3. Segmental bone loss.

Copyright © 2017 by Orthopaedic Trauma Association

Reference

Orthopaedic Trauma Association: Open Fracture Study Group. A new classification scheme for open fractures. *J Orthop Trauma*. 2010 Aug;24(8):457–464.

Dislocations

The coding is as follows:

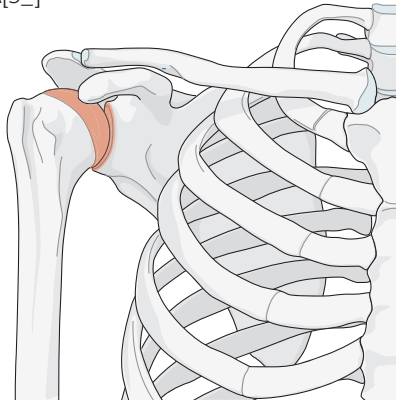
- The first number represents the distal bone of the dislocated joint.
- The second number is 0 which represents the dislocation (with the exception of the shoulder girdle where all dislocations are 10).
- The third character (A, B, C, D, and E) is used when there are more than two bone articulations in the anatomical region.
- The direction of the dislocation is coded using the universal modifier for dislocation direction, within square brackets [5_].

10

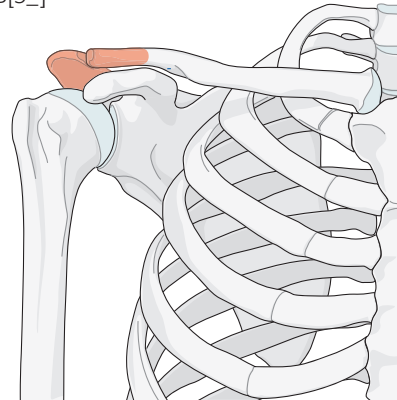
Anatomical region: Shoulder girdle 10

Locations:

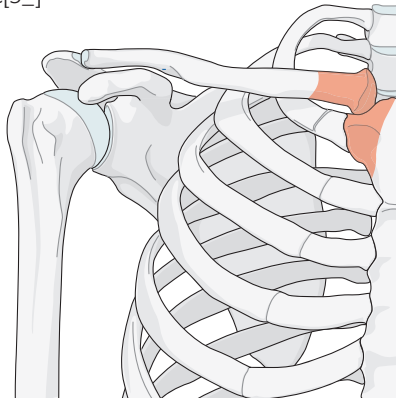
Shoulder girdle, **glenohumeral**
10A[5_]



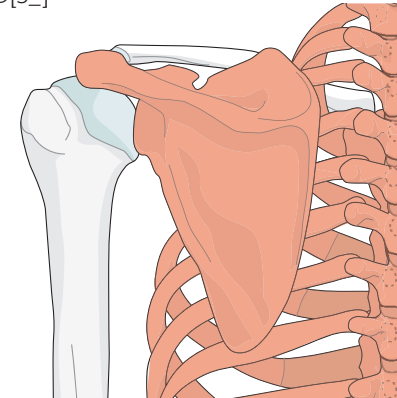
Shoulder girdle, **acromioclavicular**
10B[5_]



Shoulder girdle, **sternoclavicular**
10C[5_]



Shoulder girdle, **scapulothoracic**
10D[5_]



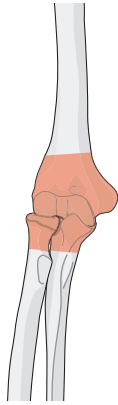
Qualifications are optional and applied to the fracture code where the asterisk is located as a lower-case letter within rounded brackets. More than one qualification can be applied for a given fracture classification, separated by a comma. For a more detailed explanation, see the compendium introduction.

20

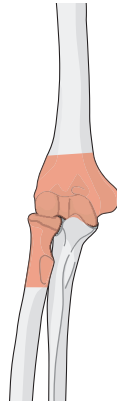Anatomical region: Elbow 20

Locations:

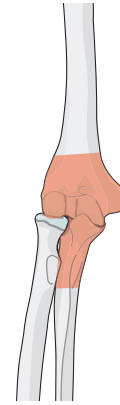
Elbow, **ulnohumeral with radiohumeral**
20A[5_]



Elbow, **radiohumeral**
20B[5_]

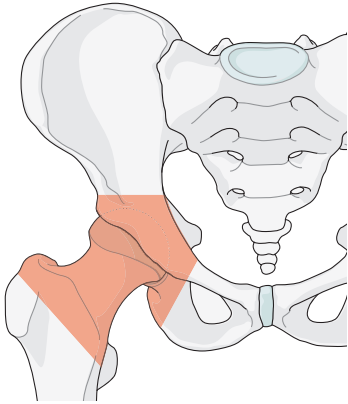


Elbow, **ulnohumeral**
20C[5_]



30

Anatomical region: Hip joint 30[5_]



40

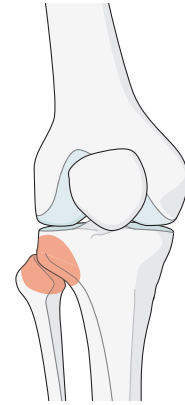
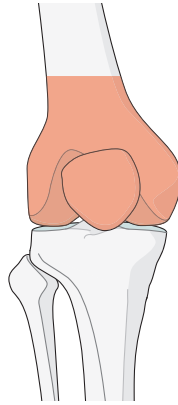
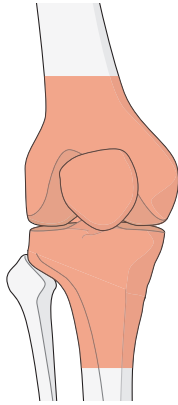
Anatomical region: Knee 40

Locations:

Knee, **tibiofemoral**
40A*[5_]

Knee, **patellofemoral**
40B[5_]

Knee, **tibiofibular proximal**
40C[5_]



***Qualifications:**

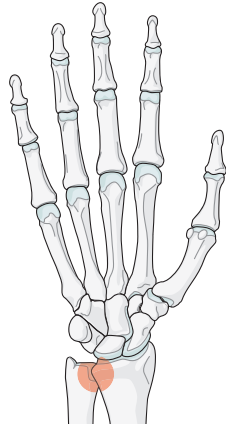
- a KD1—Multiligamentous rupture with either cruciate intact
 - b KDII—Bicruciate rupture with collateral ligaments intact
 - c KDIIIM—Bicruciate rupture with medial collateral ligament rupture
 - d KDIIIL—Bicruciate rupture with lateral collateral ligament rupture
 - e KDIV—MCL, LCL, ACL, PCL rupture
 - f KDV— Fracture dislocation
 - g associated arterial injury
 - h associated nerve injury
- More specific coding would use the fracture code and universal modifier for dislocation and direction.^{1,2}

70

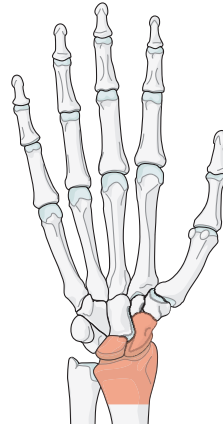
Anatomical region: Hand and wrist 70

Locations:

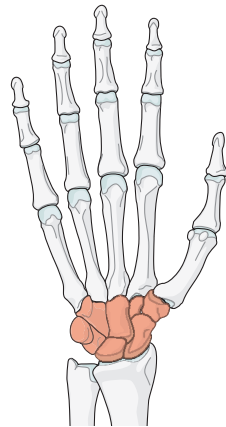
Hand and wrist, **distal radioulnar joint**
70A[5_]



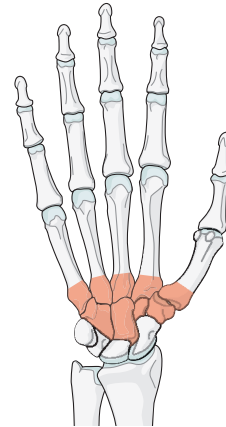
Hand and wrist, **radiocarpal joint**
70B[5_]



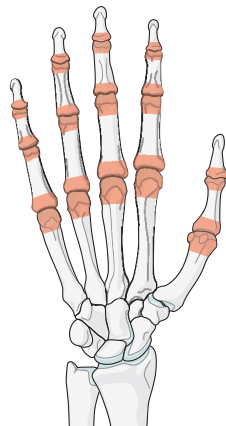
Hand and wrist, **intercarpal joint**
70C[5_]



Hand and wrist, **carpal-metacarpal joint**
70D[5_]



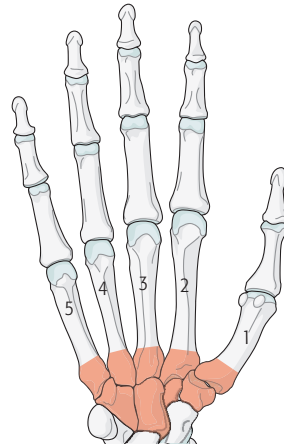
Hand and wrist, **phalangeal joint**
70E[5_]



70D

Location: Hand and wrist, **carpal-metacarpal joint** 70D

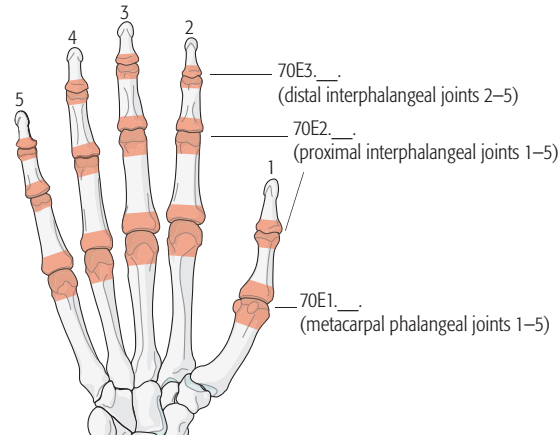
Types: Hand and wrist, carpal-metacarpal joint, **1st metacarpal-trapezium joint** 70D1[5_]
Hand and wrist, carpal-metacarpal joint, **2nd metacarpal-trapezoid joint** 70D2[5_]
Hand and wrist, carpal-metacarpal joint, **3rd metacarpal capitate joint** 70D3[5_]
Hand and wrist, carpal-metacarpal joint, **4th metacarpal hamate joint** 70D4[5_]
Hand and wrist, carpal-metacarpal joint, **5th metacarpal triquetrum joint** 70D5[5_]
Hand and wrist, carpal-metacarpal joint, **multiple carpal-metacarpal joint** 70D6[5_]



70E

Location: Hand and wrist, **phalangeal joint** 70E

Type: Hand and wrist, phalangeal joint, **metacarpal phalangeal joint** 70E1



→ The interphalangeal joints are identified as follows: thumb = 1, index = 2, long or middle = 3, ring = 4, and little = 5.

→ The identifier is added to the code after the type code.

Groups: Hand and wrist, phalangeal joint, **1st metacarpal phalangeal joint** 70E1.1.[5_]
 Hand and wrist, phalangeal joint, **2nd metacarpal phalangeal joint** 70E1.2.[5_]
 Hand and wrist, phalangeal joint, **3rd metacarpal phalangeal joint** 70E1.3.[5_]
 Hand and wrist, phalangeal joint, **4th metacarpal phalangeal joint** 70E1.4.[5_]
 Hand and wrist, phalangeal joint, **5th metacarpal phalangeal joint** 70E1.5.[5_]

Type: Hand and wrist, phalangeal joint, **proximal interphalangeal joint** 70E2

Groups: Hand and wrist, phalangeal joint, **proximal interphalangeal joint, thumb** (1st) 70E2.1[5_]
 Hand and wrist, phalangeal joint, **proximal interphalangeal joint, index** (2nd) 70E2.2[5_]
 Hand and wrist, phalangeal joint, **proximal interphalangeal joint, long** (3rd) 70E2.3[5_]
 Hand and wrist, phalangeal joint, **proximal interphalangeal joint, ring** (4th) 70E2.4[5_]
 Hand and wrist, phalangeal joint, **proximal interphalangeal joint, little** (5th) 70E2.5[5_]

Type: Hand and wrist, phalangeal joint, **distal interphalangeal joint** 70E3

Groups: Hand and wrist, phalangeal joint, **distal interphalangeal joint, index** (2nd) 70E3.2[5_]
 Hand and wrist, phalangeal joint, **distal interphalangeal joint, long** (3rd) 70E3.3[5_]
 Hand and wrist, phalangeal joint, **distal interphalangeal joint, ring** (4th) 70E3.4[5_]
 Hand and wrist, phalangeal joint, **distal interphalangeal joint, little** (5th) 70E3.5[5_]

Type: Hand and wrist, **sesamoid joint dislocation** 70E4[5_]

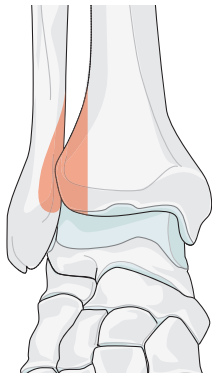
Type: Hand and wrist, **multiple phalangeal joint dislocations** 70E5

80

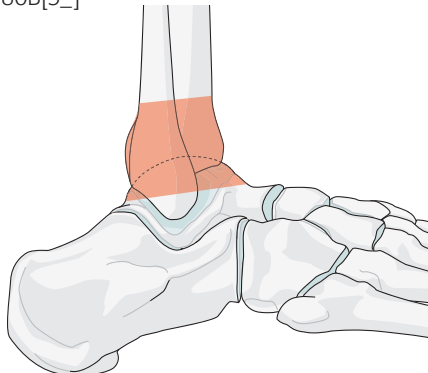
Anatomical region: Foot and ankle 80D

Locations:

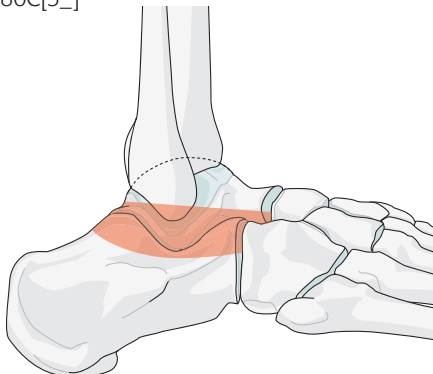
Foot and ankle, **syndesmosis**
80A[5_]



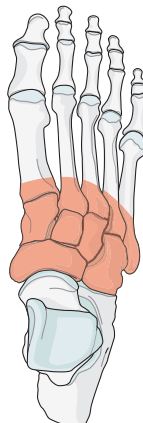
Foot and ankle, **ankle joint (tibiotalar/talocrural)**
80B[5_]



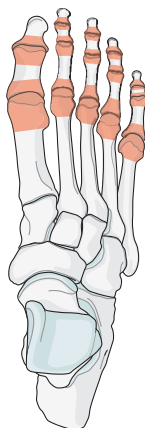Foot and ankle, **hindfoot (subtalar joint)**
80C[5_]



Foot and ankle, **midfoot**
80D



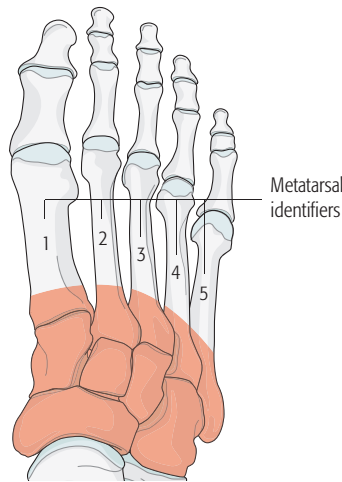
Foot and ankle, **forefoot**
80E



80D

Location: Foot and ankle, **midfoot** 80D

Types: Foot and ankle, midfoot, **talonavicular joint** 80D1[5_]
 Foot and ankle, midfoot, **calcaneocuboid joint** 80D2[5_]
 Foot and ankle, midfoot, **navicular-cuneiform joint** 80D3[5_]
 Foot and ankle, midfoot, **intercuneiform joint** 80D4[5_]
 Foot and ankle, midfoot, **tarsal-metatarsal joint** 80D5



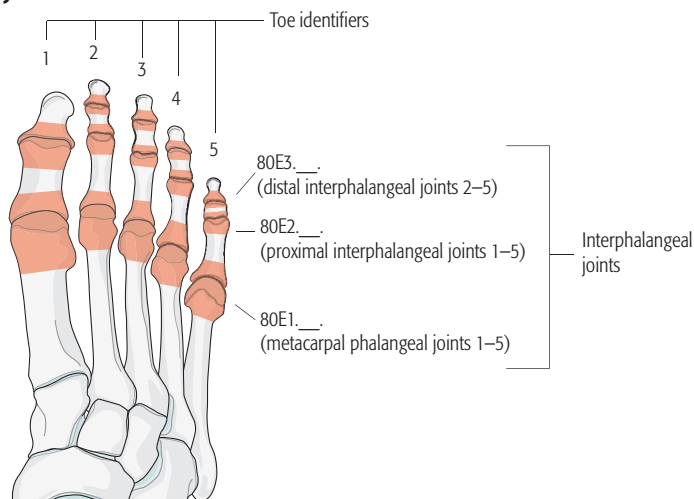
Groups: Foot and ankle, midfoot, tarsal-metatarsal joint, **1st metatarsal medial cuneiform** 80D5.1[5_]
 Foot and ankle, midfoot, tarsal-metatarsal joint, **2nd metatarsal middle cuneiform** 80D5.2[5_]
 Foot and ankle, midfoot, tarsal-metatarsal joint, **3rd metatarsal lateral cuneiform** 80D5.3[5_]
 Foot and ankle, midfoot, tarsal-metatarsal joint, **4th metatarsal cuboid** 80D5.4[5_]
 Foot and ankle, midfoot, tarsal-metatarsal joint, **5th metatarsal cuboid** 80D5.5[5_]
 Foot and ankle, midfoot, tarsal-metatarsal joint, **multiple metatarsal-tarsal** 80D5.6[5_]
 Foot and ankle, midfoot, **multiple joint dislocations** 80D6

Type: Foot and ankle, midfoot, **multiple joint dislocations** 80D6

80E

Location: Foot and ankle, **forefoot** 80E

Type: Foot and ankle, forefoot, **phalangeal joint** 80E1



Groups (by joint medial to lateral): Foot and ankle, forefoot, phalangeal joint, **1st metatarsal phalangeal joint** 80E1.1.[5_]
 Foot and ankle, forefoot, phalangeal joint, **2nd metatarsal phalangeal joint** 80E1.2.[5_]
 Foot and ankle, forefoot, phalangeal joint, **3rd metatarsal phalangeal joint** 80E1.3.[5_]
 Foot and ankle, forefoot, phalangeal joint, **4th metatarsal phalangeal joint** 80E1.4.[5_]
 Foot and ankle, forefoot, phalangeal joint, **5th metatarsal phalangeal joint** 80E1.5.[5_]

Type: Forefoot, phalangeal joint, **proximal interphalangeal joint** 80E2

Groups (by joint medial to lateral): Forefoot, phalangeal joint, proximal interphalangeal joint, **1st toe** (IP joint as there is no DIP in great toe) 80E2.1.[5_]
 Forefoot, phalangeal joint, proximal interphalangeal joint, **2nd toe** 80E2.2.[5_]
 Forefoot, phalangeal joint, proximal interphalangeal joint, **3rd toe** 80E2.3.[5_]
 Forefoot, phalangeal joint, proximal interphalangeal joint, **4th toe** 80E2.4.[5_]
 Forefoot, phalangeal joint, proximal interphalangeal joint, **5th toe** 80E2.5.[5_]

Type: Forefoot, phalangeal joint, **distal interphalangeal joint** 80E3

Groups (by joint medial to lateral): Forefoot, phalangeal joint, distal interphalangeal joint, **2nd toe** 80E3.2.[5_]
 Forefoot, phalangeal joint, distal interphalangeal joint, **3rd toe** 80E3.3.[5_]
 Forefoot, phalangeal joint, distal interphalangeal joint, **4th toe** 80E3.4.[5_]
 Forefoot, phalangeal joint, distal interphalangeal joint, **5th toe** 80E3.5.[5_]

Type: Foot and ankle, forefoot, **sesamoid dislocation (any)** 80E4[5_]

Type: Foot and ankle, forefoot, **multiple dislocations** 80E5

References

1. **Schenck RC, Jr.** The dislocated knee. *Instr Course Lect.* 1994;43:127–136.
2. **Wascher DC.** High-velocity knee dislocation with vascular injury. Treatment principles. *Clin Sports Med.* 2000 Jul;19(3):457–477.

Qualifications are optional and applied to the fracture code where the asterisk is located as a lower-case letter within rounded brackets. More than one qualification can be applied for a given fracture classification, separated by a comma. For a more detailed explanation, see the compendium introduction.

AO Pediatric Comprehensive Classification of Long Bone Fractures (PCCF)

Introduction

In adult fractures the injury severity and fracture pattern are important. In pediatric fractures another component is added—the phenomenon of growth. Previous classifications of children's fractures are very specific, but not universal in application¹⁻⁶ and none have been scientifically validated.⁷⁻⁹ Finally, there is no classification system available for diaphyseal long bone fractures. Any classification for pediatric fractures must be applicable for all fractures and recognize the importance of growth through the epiphyseal plate. To address these needs, the validated AO Pediatric Comprehensive Classification of Long Bone Fractures (PCCF)¹ was introduced to the AO/OTA Compendium of Fractures and Dislocations in 2007.¹⁰⁻¹²

The principles and definitions of the pediatric long bone fracture classification

The terminology and coding of the PCCF are based on the principles found in Müller's Long Bone Comprehensive Classification of Fractures.¹³ This system only addresses the four long bones.

Bone

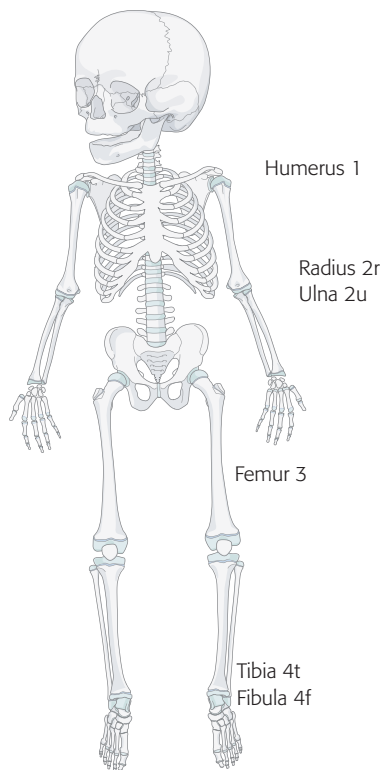


Fig 1 Designation of bone location.

The bones are coded: Humerus (1), Radius (2r), Ulna (2u), Femur (3), Tibia (4t) and Fibula (4f) (**Fig 1**). Note that the paired bones radius/ulna or tibia/fibula are classified as individual bones (**Fig 2**) allowing the detailed documentation of combined fractures of the radius and ulna, or the tibia and fibula.

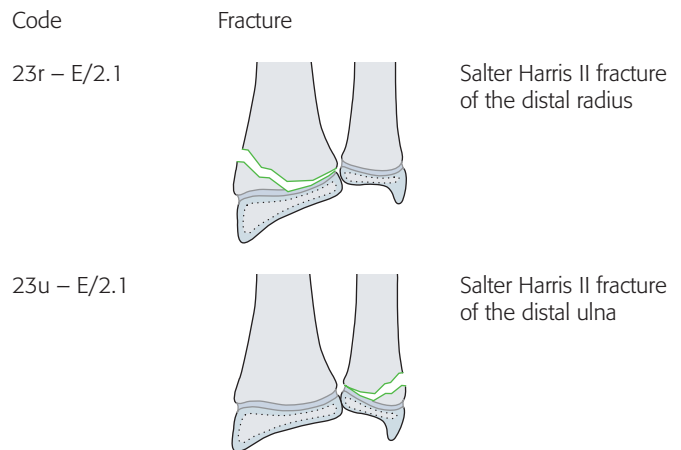


Fig 2 Coding of same fracture but different bone in paired bones.

Fracture location

The location within the bones is the proximal end segment (1), diaphyseal segment (2), and, distal end segment (3). The end segment consists of the epiphysis and metaphysis. The metaphyseal end segment is determined by a square whose sides are the same length as the widest part of the visible epiphyseal growth plate (**Fig 3**).¹¹ For the radius/ulna and tibia/fibula, both bones must be included in the square.

Consequently, the three segments can be defined as:

- Proximal end segment (1) and distal end segment (3)
 - Subsegments are the epiphysis (E) and metaphysis (square) (M)
- Diaphyseal segment (2)
 - Subsegment is the section between two end segments (D).

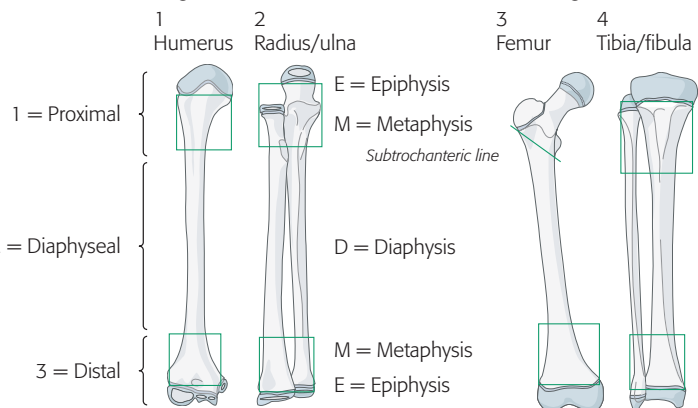


Fig 3 Definition of bone segments and types. For children, the square must be placed over the larger part of the physis.

Malleolar fractures are infrequent in children and do not justify a specific coding. They are simply coded as distal end segment tibia and/or fibula fractures.

The subsegments follow the segment and are the diaphysis (D), metaphysis (M) and epiphysis (E) (Fig 3). Epiphyseal fractures are by definition intraarticular fractures. (Fig 3 and Fig 4). The square definition is not applied to the proximal femur where metaphyseal fractures are located between the physis of the head and the intertrochanteric line.

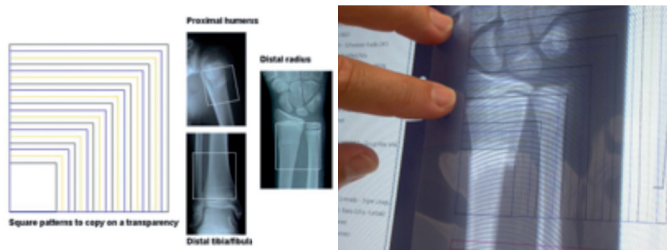


Fig 4 Use of the square patterns to classify a fracture as epiphyseal (E), metaphyseal (M) or diaphyseal (D). The square patterns are copied onto a transparency sheet and applied over the radiograph for more reliable and accurate diagnosis.

Fracture displacement may distort the fracture fragment’s exact anatomy so the end segment square may not be accurate necessitating reclassification after the fracture reduction.

Child code

A forward slash “/” (Fig 5) is used to identify the specific child fracture codes:

- Epiphyseal fracture codes (Fig 6)
- Specific metaphyseal fracture child codes (Fig 7)
- Specific diaphyseal fracture child codes (Fig 8)

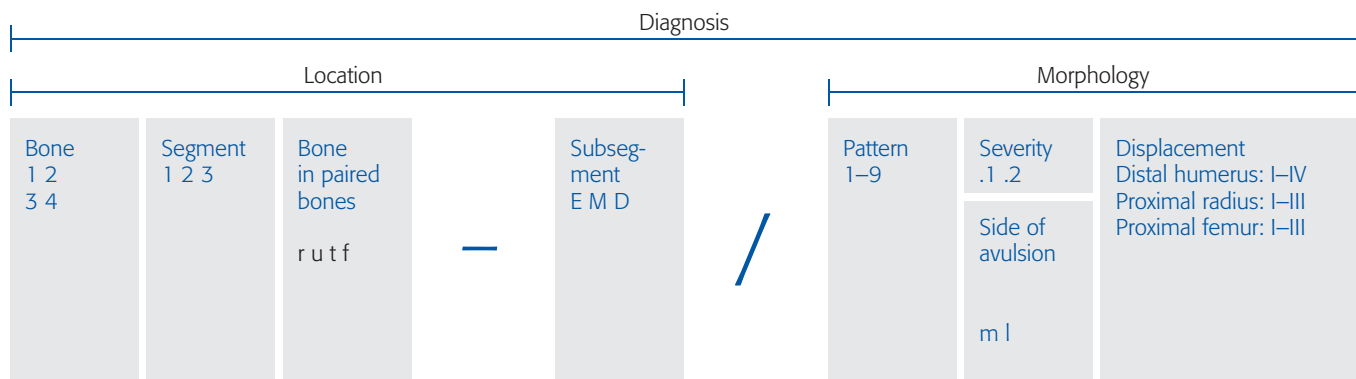


Fig 5 Overall structure of the pediatric fracture classification

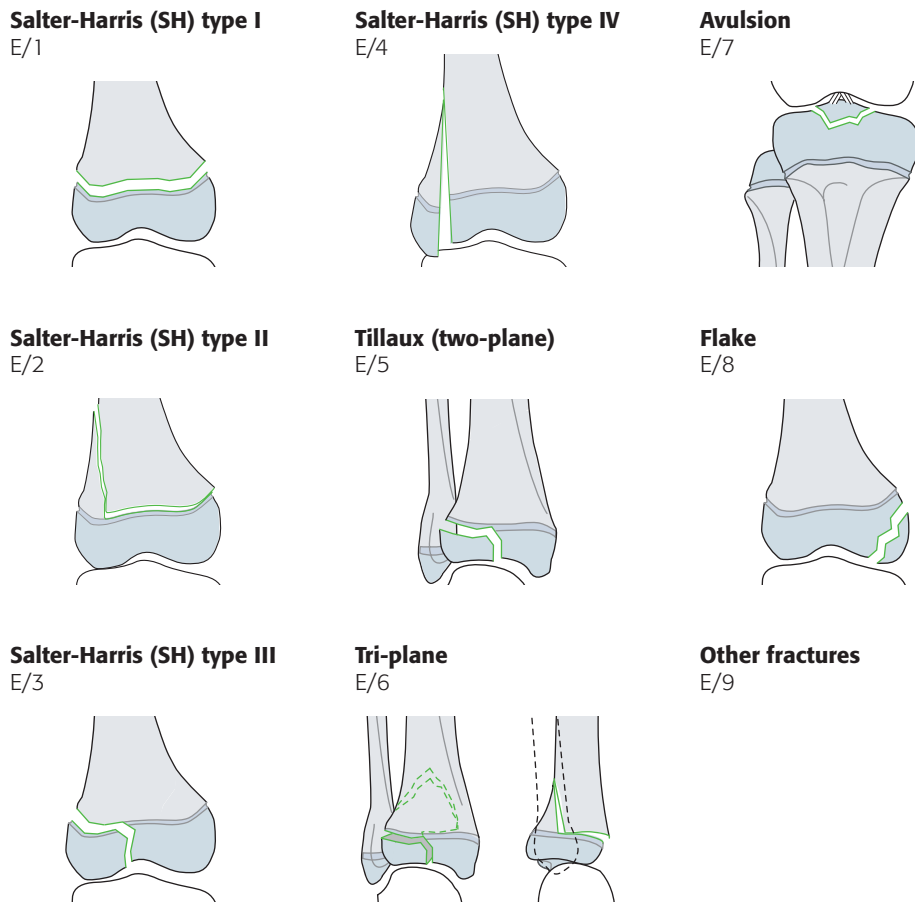


Fig 6 Definition of child patterns for epiphyseal fractures.

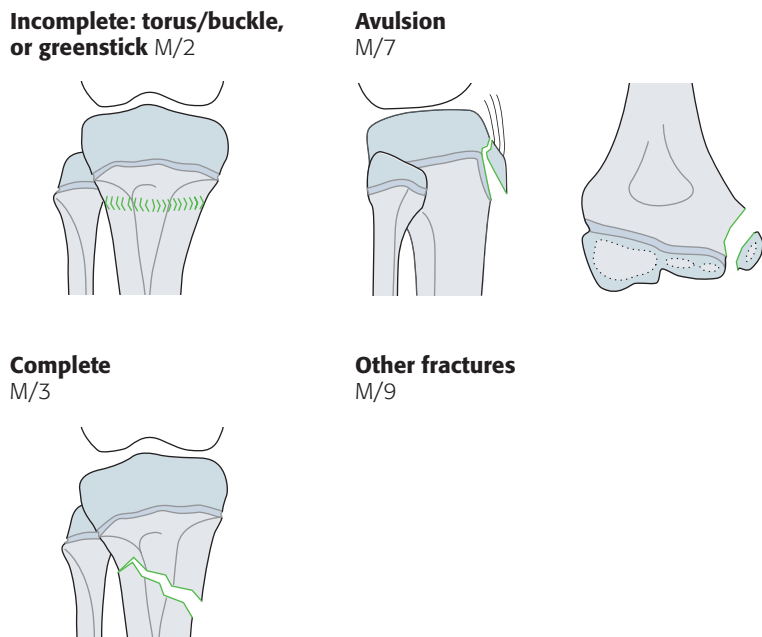


Fig 7 Definition of child patterns for metaphyseal fractures.

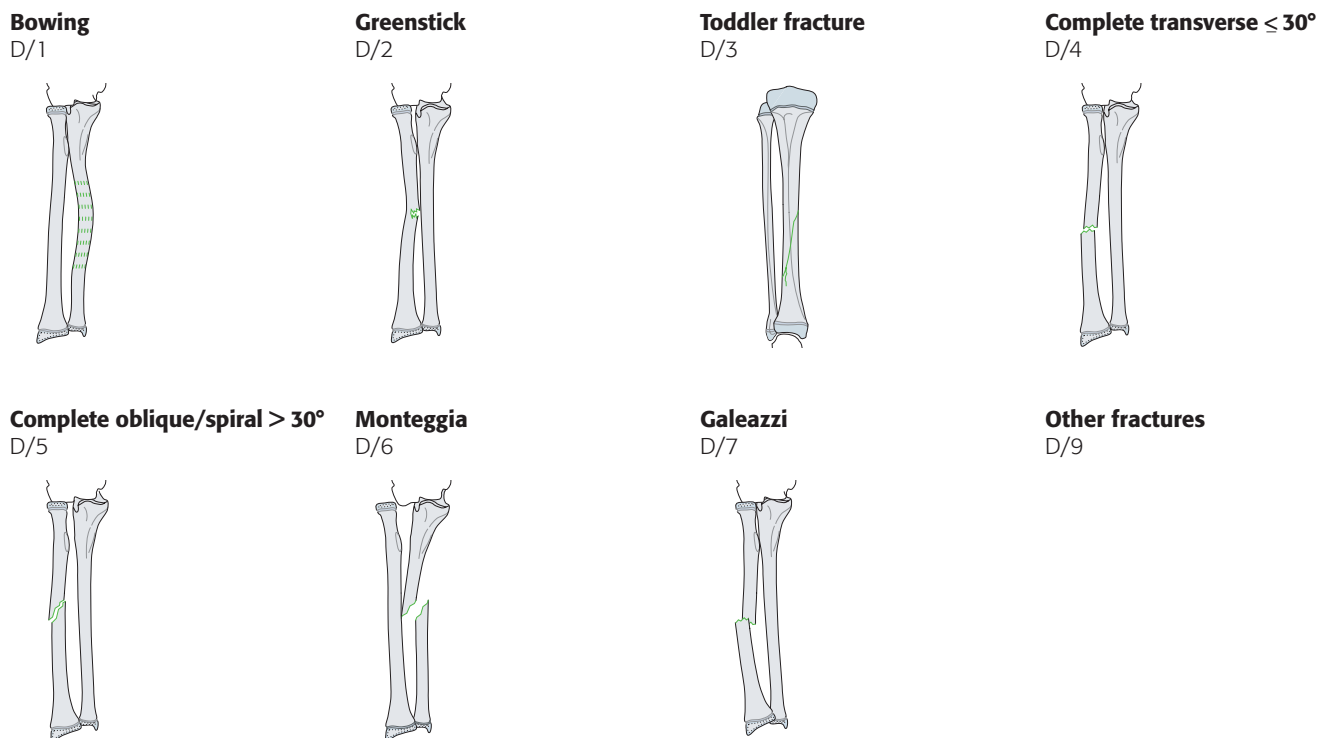
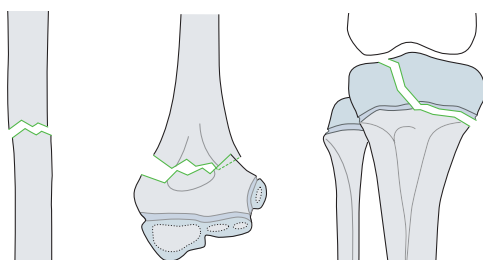


Fig 8 Definition of child patterns for diaphyseal fractures.

Fracture severity code

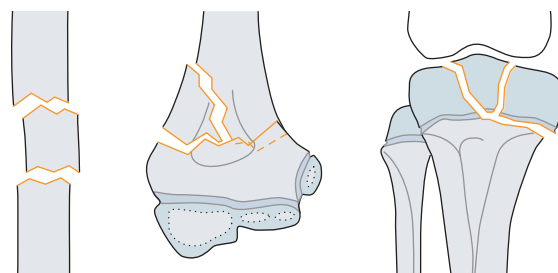
This code distinguishes between two grades of fracture severity: simple (.1) and multifragmentary (.2) (**Fig 9**).

.1 Simple



Two main fragments

.2 Multifragmentary



Two main fragments and at least one intermediate fragment

Fig 9 Severity implies anticipated difficulties and method of treatment, not the prognosis.

Qualifications

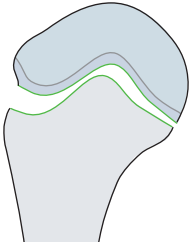
These codes are added as roman numerals between rounded brackets at the end of the fracture code, eg 13-M/3.1(III). These are described by an additional code for the grade of angulation.

Humerus 1

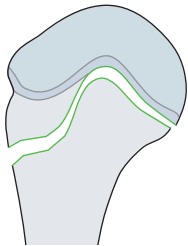
Proximal epiphyseal fractures 11-E

Simple

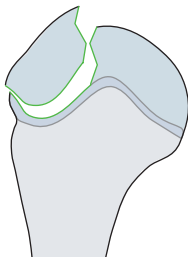
Epiphysiolysis, SH I 11-E/1.1



Epiphysiolysis with metaphyseal wedge, SH II 11-E/2.1

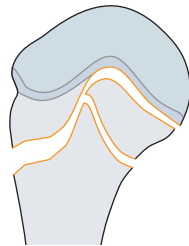


Epiphyseal, SH III 11-E/3.1

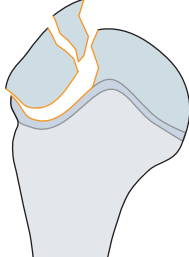


Multifragmentary

Epiphysiolysis with metaphyseal wedge, SH II 11-E/2.2

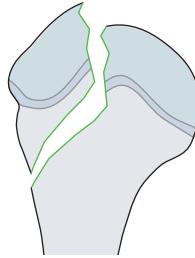


Epiphyseal, SH III 11-E/3.2

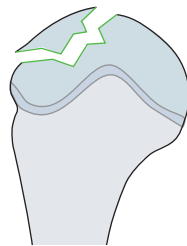


Simple

Epi-/metaphyseal, SH IV 11-E/4.1

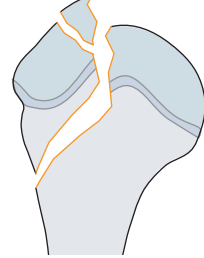


Intraarticular flake 11-E/8.1

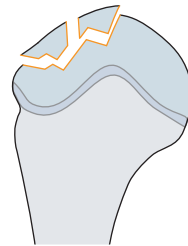


Multifragmentary

Epi-/metaphyseal, SH IV 11-E/4.2

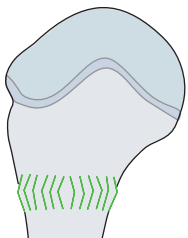


Intraarticular flake 11-E/8.2

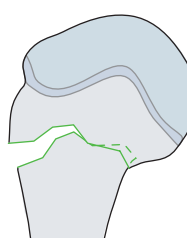


Proximal metaphyseal fractures 11-M

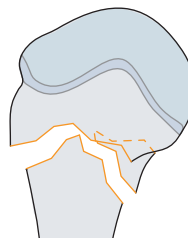
Torus/buckle 11-M/2.1



Complete 11-M/3.1



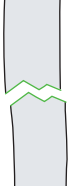
Complete 11-M/3.2



Diaphyseal fractures 12-D

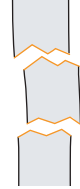Simple

Complete transverse (< 30°)
12-D/4.1



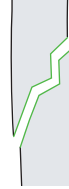Multifragmentary

Complete transverse (< 30°)
12-D/4.2



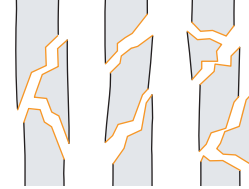
Simple

Complete oblique or spiral (≥ 30°)
12-D/5.1



Multifragmentary

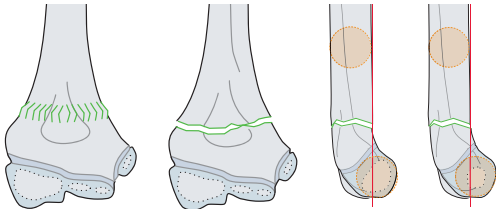
Complete oblique or spiral (≥ 30°)
12-D/5.2



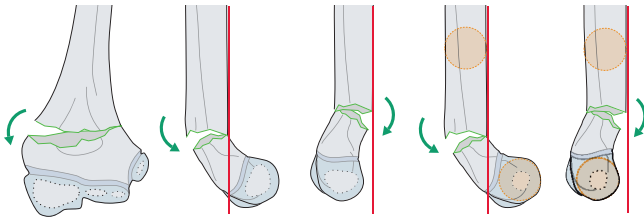
Distal metaphyseal fractures 13-M

Simple

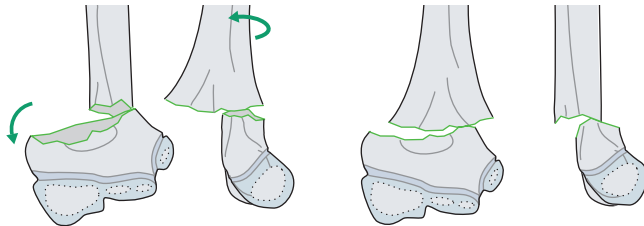
Incomplete, nondisplaced 13-M/3.1 I



Incomplete, displaced 13-M/3.1 II

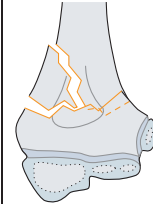


Complete with contact between fracture planes 13-M/3.1 III

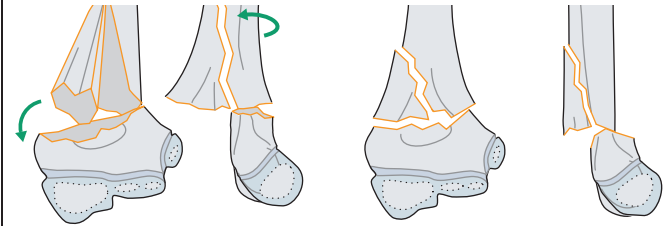


Multifragmentary

Incomplete, displaced 13-M/3.2 II

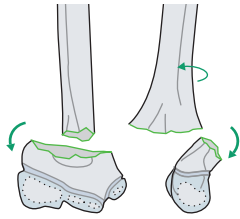


Complete with contact between fracture planes 13-M/3.2 III

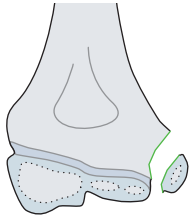


Simple

Complete without contact between fracture planes 13-M/3.1 IV

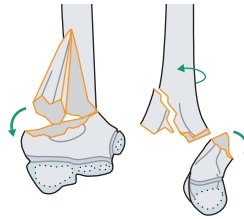


Avulsion of the epicondyle (extraarticular) 13-M/7m



Multifragmentary

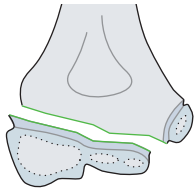
Complete without contact between fracture planes 13-M/3.2 IV



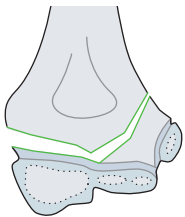
Distal epiphyseal fractures 13-E

Simple

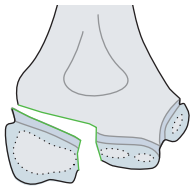
Epiphysiolysis, SH I
13-E/1.1



Epiphysiolysis with metaphyseal wedge, SH II 13-E/2.1

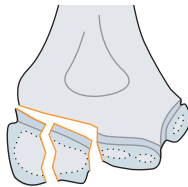


Epiphyseal, SH III 13-E/3.1



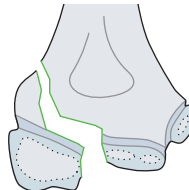
Multifragmentary

Epiphyseal, SH III 13-E/3.2

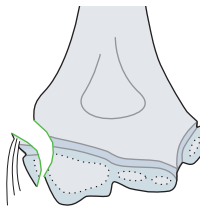


Simple

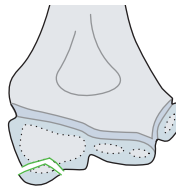
Epi-/metaphyseal, SH IV
13-E/4.1



Avulsion of/by the collateral ligament 13-E/7

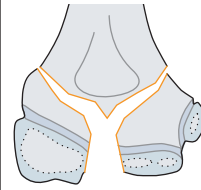


Intraarticular flake 13-E/8.1

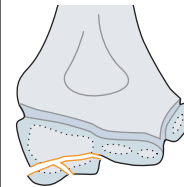


Multifragmentary

Epi-/metaphyseal, SH IV
13-E/4.2



Intraarticular flake 13-E/8.2



Radius/ulna 2

Proximal epiphyseal fractures 21-E

Isolated fractures of the radius

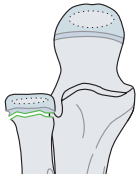
Simple

Multifragmentary

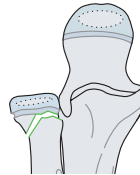
Simple

Multifragmentary

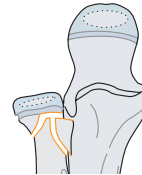
Epiphysiolysis, SH I, no angulation and no displacement
21r-E/1.1 I*



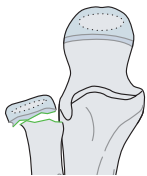
Epiphysiolysis with metaphyseal wedge, SH II, no angulation and no displacement
21r-E/2.1 I*



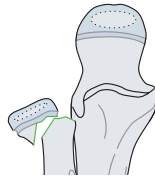
Epiphysiolysis with metaphyseal wedge, SH II, no angulation and no displacement 21r-E/2.2 I*



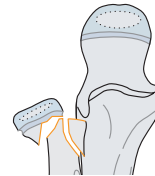
Epiphysiolysis, SH I, angulation with displacement of up to half of the bone diameter
21r-E/1.1 II*



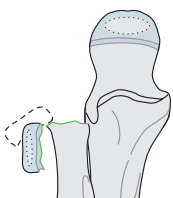
Epiphysiolysis with metaphyseal wedge, SH II, angulation with displacement of up to half of the bone diameter
21r-E/2.1 II*



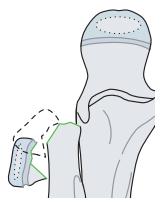
Epiphysiolysis with metaphyseal wedge, SH II, angulation with displacement of up to half of the bone diameter
21r-E/2.2 II*



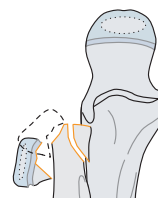
Epiphysiolysis, SH I, angulation with displacement of more than half of the bone diameter
21r-E/1.1 III*



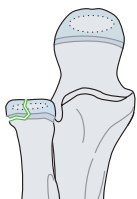Epiphysiolysis with metaphyseal wedge, SH II, angulation with displacement of more than half of the bone diameter
21r-E/2.1 III*



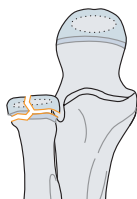
Epiphysiolysis with metaphyseal wedge, SH II, angulation with displacement of more than half of the bone diameter
21r-E/2.2 III*



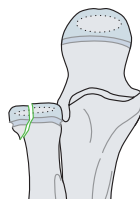
Epiphyseal, SH III 21r-E/3.1



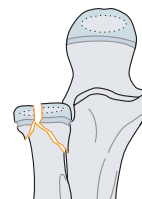
Epiphyseal, SH III 21r-E/3.2



Epi-/metaphyseal, SH IV
21r-E/4.1



Epi-/metaphyseal, SH IV
21r-E/4.2



*Qualifications for displaced radial head and neck fractures:

Type I No angulation and no displacement

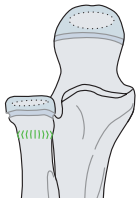
Type II Angulation with displacement of up to half of the bone diameter

Type III Angulation with displacement of more than half of the bone diameter

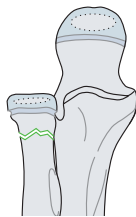Proximal metaphyseal fractures 21-M

Isolated fractures of the radius

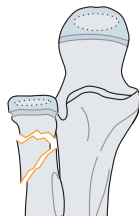Torus/buckle 21r-M/2.1



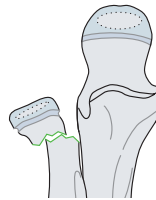Complete, no angulation and no displacement 21r-M/3.1 I



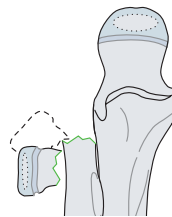Complete, no angulation and no displacement 21r-M/3.1 II



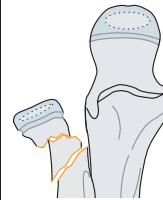Complete, angulation with displacement of up to half of the bone diameter 21r-M/3.1 II



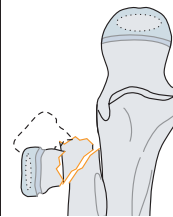
Complete, angulation with displacement of up to half of the bone diameter 21r-M/3.1 II



Complete, angulation with displacement of up to half of the bone diameter 21r-M/3.2 II

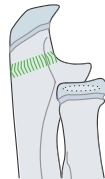

Complete, angulation with displacement of up to half of the bone diameter 21r-M/3.2 II

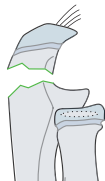


Isolated fractures of the ulna

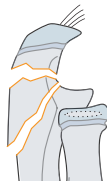Torus/buckle 21u-M/2.1



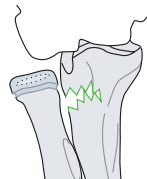
Complete 21u-M/3.1



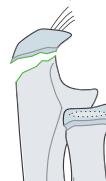Complete 21u-M/3.2



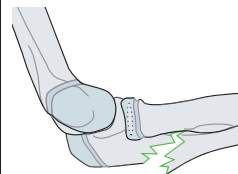
Greenstick, dorsal radial head dislocation (Bado II) 21u-M/6.1



Avulsion of the apophysis 21u-M/7



Greenstick, lateral radial head dislocation (Bado III) 21u-M/6.1

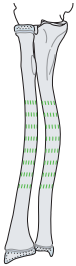

Diaphyseal fractures 22-D

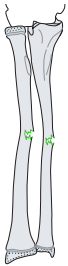Fractures of both bones

Simple

Bowing 22-D/1.1



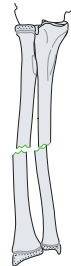
Greenstick 22-D/2.1



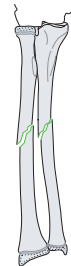
Multifragmentary

Simple

Complete transverse (< 30°)
22-D/4.1

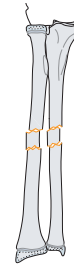


Complete oblique or spiral (≥ 30°)
22-D/5.1

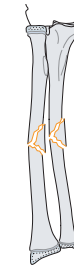


Multifragmentary

Complete transverse (< 30°)
22-D/4.2

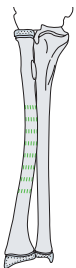


Complete oblique or spiral (≥ 30°)
22-D/5.2

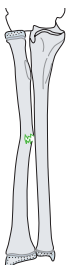

Isolated fractures of the radius

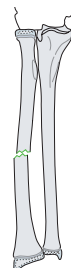
Bowing 22r-D/1.1



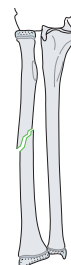
Greenstick 22r-D/2.1



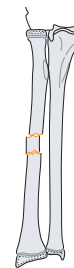
Complete transverse (< 30°)
22r-D/4.1



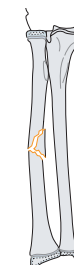Complete oblique or spiral (≥ 30°)
22r-D/5.1



Complete transverse (< 30°)
22r-D/4.2



Complete oblique or spiral (≥ 30°)
22r-D/5.2



Simple

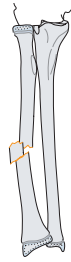
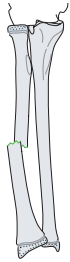
Multifragmentary

Simple

Multifragmentary

Galeazzi 22r-D/7.1

Galeazzi 22r-D/7.2

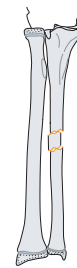
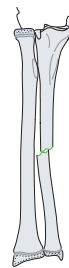
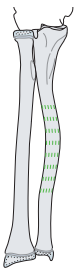


Isolated fractures of the ulna

Bowing 22u-D/1.1

Complete transverse (< 30°)
22u-D/4.1

Complete transverse (< 30°)
22u-D/4.2

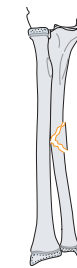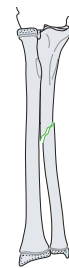

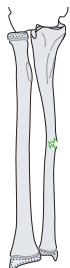
Isolated fractures of the radius

Greenstick 22u-D/2.1

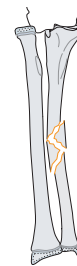
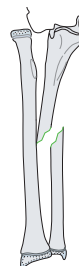
Complete oblique or spiral (≥ 30°)
22u-D/5.1

Complete oblique or spiral (≥ 30°)
22u-D/5.2



Monteggia 22u-D/6.1

Monteggia 22u-D/6.2

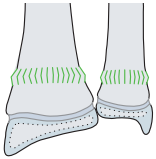


Distal metaphyseal fractures 23-M

Fractures of both bones

Simple

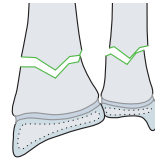
Torus/buckle 23-M/2.1



Multifragmentary

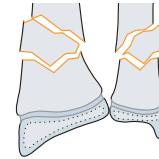
Simple

Complete 23-M/3.1



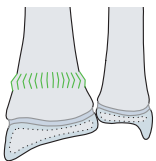
Multifragmentary

Complete 23-M/3.2

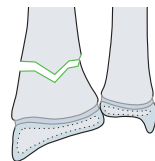


Isolated fractures of the radius

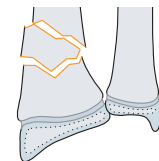
Torus/buckle 23r-M/2.1



Complete 23r-M/3.1

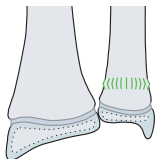


Complete 23r-M/3.2

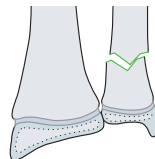


Isolated fractures of the ulna

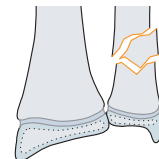
Torus/buckle 23u-M/2.1



Complete 23u-M/3.1



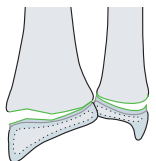
Complete 23u-M/3.2



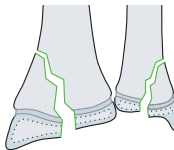
Distal epiphyseal fractures 23-E

Fractures of both bones

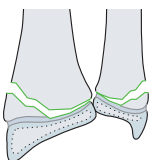
Epiphysiolysis, SH I 23-E/1



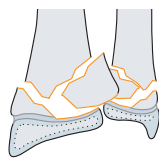
Epi-/metaphyseal, SH IV
23-E/4.1



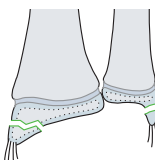
Epiphysiolysis with metaphyseal wedge, SH II 23-E/2.1



Epiphysiolysis with metaphyseal wedge, SH II 23-E/2.2



Avulsion of the styloid
23-E/7



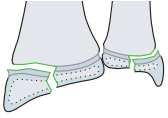
Simple

Multifragmentary

Simple

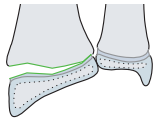
Multifragmentary

Epiphyseal, SH III 23r-E/3

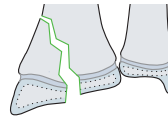


Isolated fractures of the radius 23-E

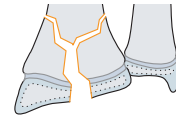
Epiphysiolysis, SH I 23r-E/1



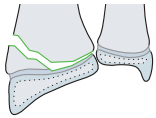
Epi-/metaphyseal, SH IV
23r-E/4.1



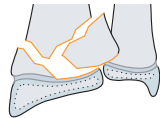
Complete 23r-E/4.2



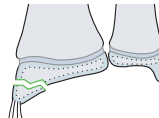
Epiphysiolysis with metaphyseal wedge, SH II 23r-E/2.1



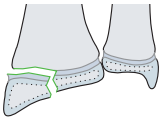
Epiphysiolysis with metaphyseal wedge, SH II 23r-E/2.2



Avulsion of the styloid
23r-E/7

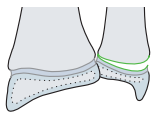


Epiphyseal, SH III 23r-E/3

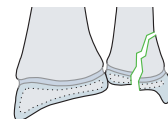


Isolated fractures of the ulna 23-E

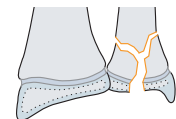
Epiphysiolysis, SH I
23u-E/1.1



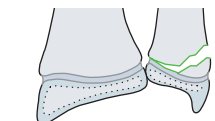
Epi-/metaphyseal, SH IV
23-M/3.1



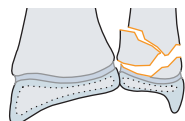
Epi-/metaphyseal, SH IV
23-M/3.1



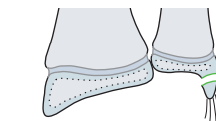
Epiphysiolysis with metaphyseal wedge, SH II 23u-E/2.1



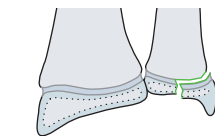
Epiphysiolysis with metaphyseal wedge, SH II 23u-E/2.2



Avulsion of the styloid
23u-E/7



Epiphyseal, SH III 23u-E/3

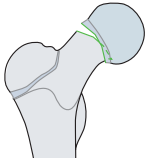


3 Femur

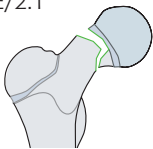
Proximal epiphyseal fractures 31-E

Simple

Epiphysiolysis (SUFE/SCFE), SH I 31-E/1.1



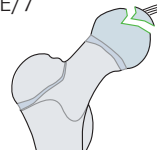
Epiphysiolysis (SUFE/SCFE) with metaphyseal wedge, SH II 31-E/2.1



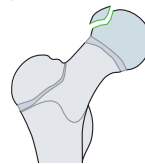
Multifragmentary

Simple

Avulsion of/by the ligament of the head of the femur 31-E/7

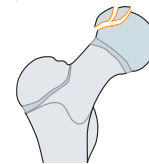

Intraarticular flake 31-E/8.1



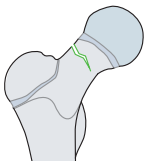
Multifragmentary

Intraarticular flake 31-E/8.2

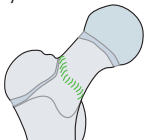


Proximal metaphyseal fractures 31-M

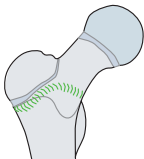
Incomplete midcervical 31-M/2.1 I*



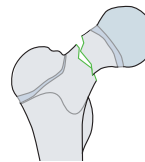
Incomplete basicervical 31-M/2.1 II*



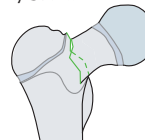
Incomplete transtrochanteric 31-M/2.1 III*



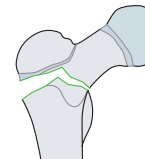
Complete midcervical 31-M/3.1 I*



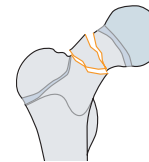
Complete basicervical 31-M/3.1 II*



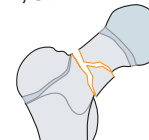
Complete transtrochanteric 31-M/3.1 III*



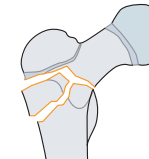
Complete midcervical 31-M/3.2 I*



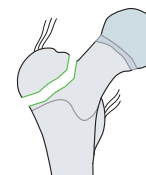
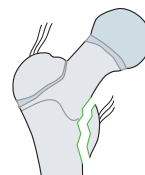
Complete basicervical 31-M/3.2 II*



Complete transtrochanteric 31-M/3.2 III*



Avulsion of the greater or lesser trochanter 31-M/7



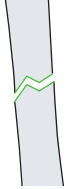*Qualifications for femoral neck fractures:

- Type I Midcervical
- Type II Basicervical
- Type III Transtrochanteric

Diaphyseal fractures 32-D

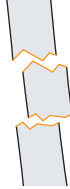Simple

Complete transverse (< 30°) 32-D/4.1



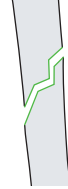Multifragmentary

Complete transverse (< 30°) 32-D/4.2



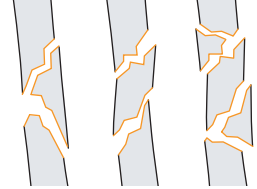
Simple

Complete oblique or spiral (≥ 30°) 32-D/5.1



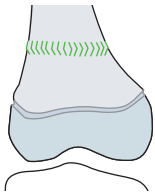
Multifragmentary

Complete oblique or spiral (≥ 30°) 32-D/5.2

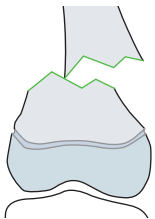


Distal metaphyseal fractures 33-M

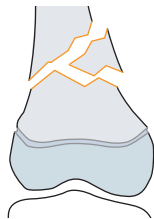
Torus/buckle 33-M/2.1



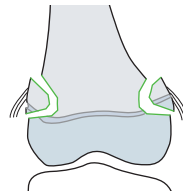
Complete 33-M/3.1



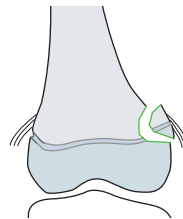
Complete 33-M/3.2



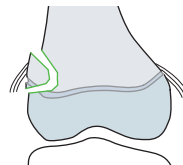
Bilateral avulsion 33-M/7



Medial avulsion 33-M/7m

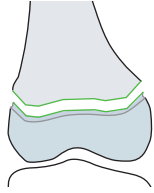


Lateral avulsion 33-M/7l

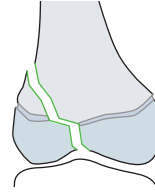


Distal epiphyseal fractures 33-E

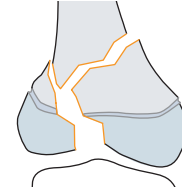
Epiphysiolysis, SH I
33-E/1.1



Epi-/metaphyseal, SH IV
33-E/4.1

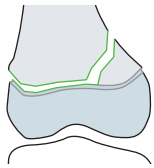


Epi-/metaphyseal, SH IV
33-E/4.2



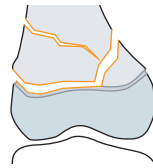Simple

Epiphysiolysis with metaphyseal wedge, SH II 33-E/2.1



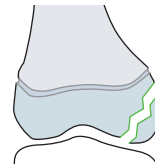Multifragmentary

Epiphysiolysis with metaphyseal wedge, SH II 33-E/2.2



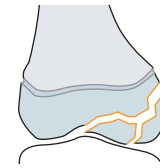
Simple

Intraarticular flake 33-E/8.1

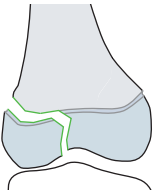


Multifragmentary

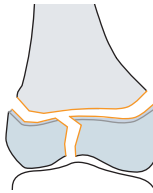
Intraarticular flake 33-E/8.2



Epiphyseal, SH III 33-E/3.1



Epiphyseal, SH III 33-E/3.2

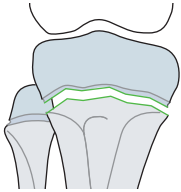


Tibia/fibula 4

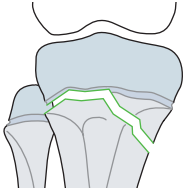
Proximal epiphyseal fractures 41-E

Isolated fractures of the tibia

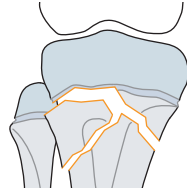
Epiphysiolysis, SH I
41t-E/1.1



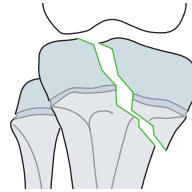
Epiphysiolysis, with metaphyseal wedge, SH II
41t-E/2.1



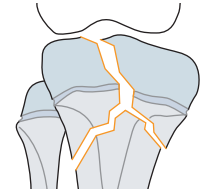
Epiphysiolysis, with metaphyseal wedge, SH II
41t-E/2.2



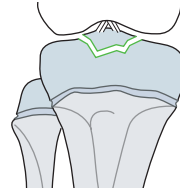
Epi-/metaphyseal, SH IV
41t-E/4.1



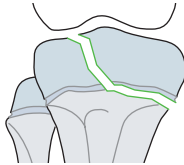
Epi-/metaphyseal, SH IV
41t-E/4.2



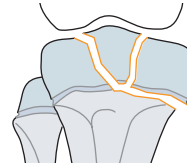
Avulsion of the tibial spine
41t-E/7



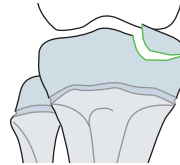
Epiphyseal, SH III 41t-E/3.1



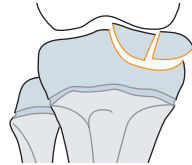
Epiphyseal, SH III 41t-E/3.2



Intraarticular flake 41t-E/8.1



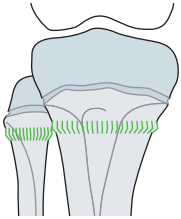
Intraarticular flake 41t-E/8.2



Proximal metaphyseal fractures 41-M

Fractures of both bones

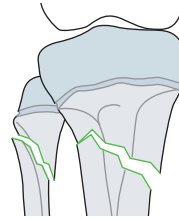
Torus/buckle 41-M/2.1



Simple

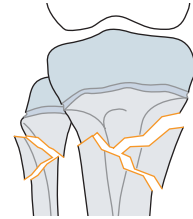
Multifragmentary

Complete 41-M/3.1



Simple

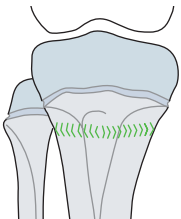
Complete 41-M/3.2



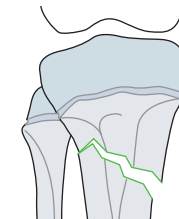
Multifragmentary

Isolated fractures of the tibia

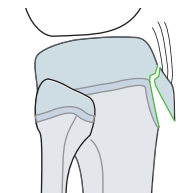
Torus/buckle 41t-M/2.1



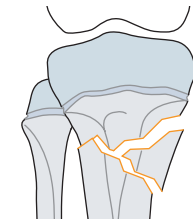
Complete 41t-M/3.1



Avulsion of the apophysis
41t-M/7

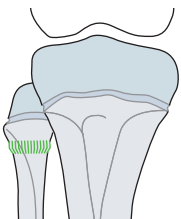


Complete 41t-M/3.2

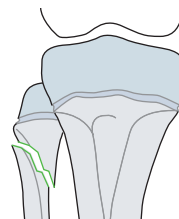


Isolated fractures of the fibula

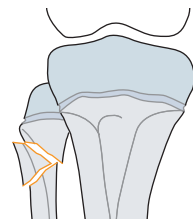
Torus/buckle 41f-M/2.1



Complete 41f-M/3.1



Complete 41f-M/3.2

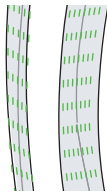


Diaphyseal fractures 42-D

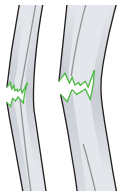Fractures of both bones

Simple

Bowing 42-D/1.1



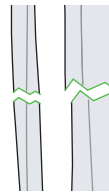
Greenstick 42-D/2.1



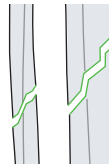
Multifragmentary

Simple

Complete transverse (< 30°)
42-D/4.1

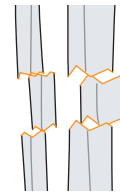


Complete oblique or spiral (≥ 30°)
42-D/5.1

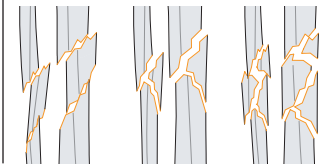


Multifragmentary

Complete transverse (< 30°)
42-D/4.2

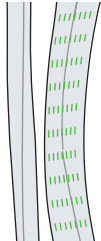


Complete oblique or spiral (≥ 30°)
42-D/5.2



Isolated fractures of the tibia

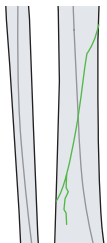
Bowing 42t-D/1.1



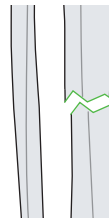Greenstick 42t-D/2.1



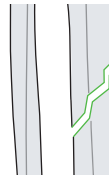
Toddler fracture 42t-D/3.1



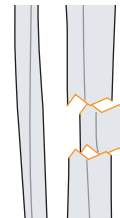
Complete transverse (< 30°)
42t-D/4.1



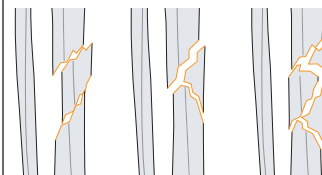
Complete oblique or spiral (≥ 30°)
42t-D/5.1



Complete transverse (< 30°)
42t-D/4.2



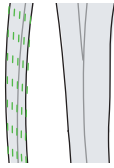
Complete oblique or spiral (≥ 30°)
42t-D/5.2



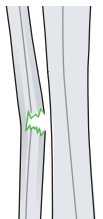
Isolated fractures of the fibula

Simple

Bowing 42f-D/1.1



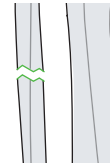
Greenstick 42f-D/2.1



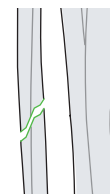Multifragmentary

Simple

Complete transverse (< 30°)
42f-D/4.1

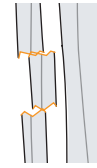


Complete oblique or spiral (≥ 30°) 42f-D/5.1

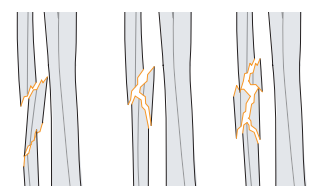


Multifragmentary

Complete transverse (< 30°)
42f-D/4.2



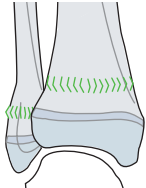
Complete oblique or spiral (≥ 30°) 42f-D/5.2



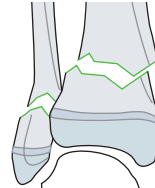
Distal metaphyseal fractures 43-M

Fractures of both bones

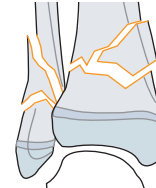
Torus/buckle 43-M/2.1



Complete 43-M/3.1

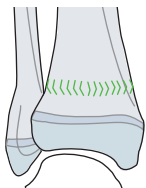


Complete 43-M/3.2

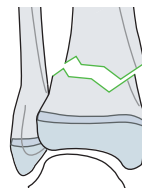


Isolated fractures of the tibia

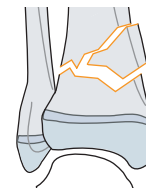
Torus/buckle 43t-M/2.1



Complete 43t-M/3.1

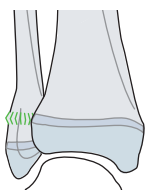


Complete 43t-M/3.2

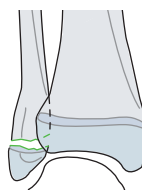


Isolated fractures of the fibula

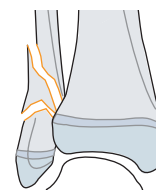
Torus/buckle 43f-M/2.1



Complete 43f-M/3.1



Complete 43f-M/3.2

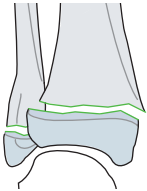


Distal epiphyseal fractures 43-E

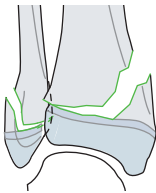
Fractures of both bones

Simple

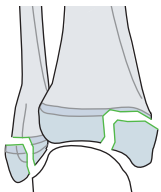
Epiphysiolysis, SH I 43-E/1.1



Epiphysiolysis with metaphyseal wedge, SH II 43-E/2.1



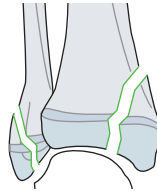
Epiphyseal, SH III 43-E/3.1



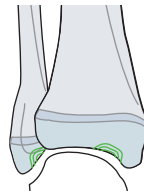
Multifragmentary

Simple

Epi-/metaphyseal, SH IV 43-E/4.1



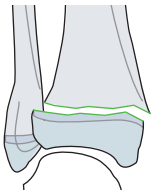
Intraarticular flake 43-E/8.1



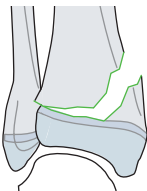
Multifragmentary

Isolated fracture of the tibia

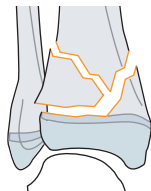
Epiphysiolysis, SH I 43t-E/1.1



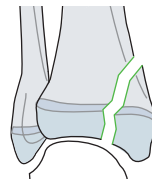
Epiphysiolysis with metaphyseal wedge, SH II 43t-E/2.1



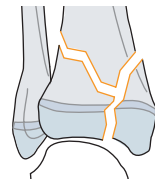
Epiphysiolysis with metaphyseal wedge, SH II 43t-E/2.2



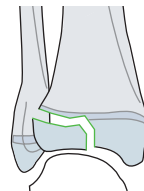
Epi-/metaphyseal, SH IV 43t-E/4.1



Epi-/metaphyseal, SH IV 43t-E/4.2

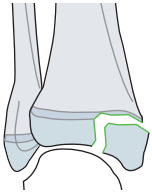


Tillaux (two-plane), SH III 43t-E/5.1

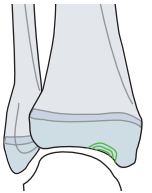


Simple

Epiphyseal, SH III 43t-E/3.1



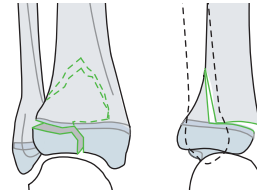
Intraarticular flake 43t-E/8.1



Multifragmentary

Simple

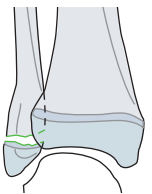
Tri-plane, SH IV 43t-E/6.1



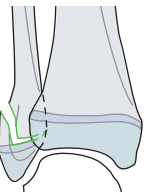
Multifragmentary

Isolated fractures of the fibula

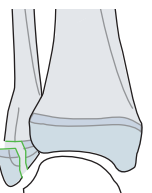
Epiphysiolysis, SH I 43f-E/1.1



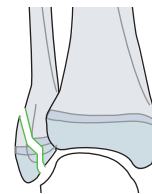
Epiphysiolysis with metaphyseal wedge, SH II 43f-E/2.1



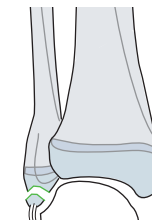
Epiphyseal, SH III 43f-E/3.1



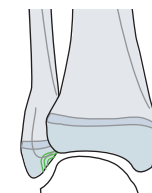
Epi-/metaphyseal, SH IV 43f-E/4.1



Avulsion 43f-E/7



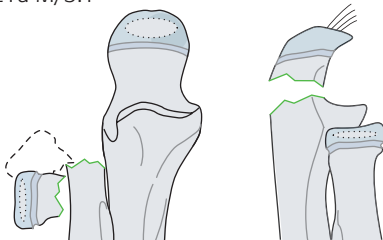
Intraarticular flake 43f-E/8.1



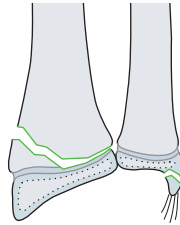
Frequent fracture combinations

Radius/ulna

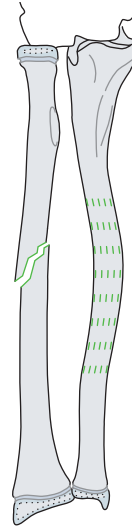
Complete radial neck fracture type III and olecranon fracture 21r-M/3.1 III, 21u-M/3.1



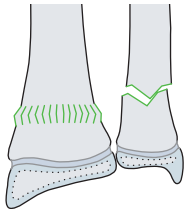
Radial SH II and avulsion of the ulnar styloid 23r-E/2.1, 23u-E/7



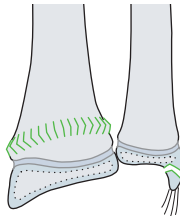
Simple oblique or spiral complete radial fracture and bowing ulnar fracture 22r-D/5.1, 22u-D/1.1



Torus/buckle fracture of the radius and complete metaphyseal ulnar fracture 23r-M/2.1, 23u-M/3.1

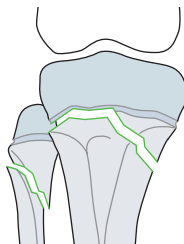


Torus/buckle fracture of the radius and avulsion of the ulnar styloid 23r-M/2.1, 23u-E/7

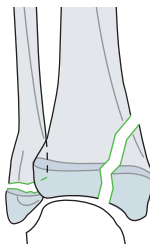


Tibia/fibula

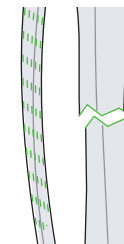
Proximal: SH II tibial fracture and complete metaphyseal fibular fracture 41t-E/2.1, 41f-M/3.1



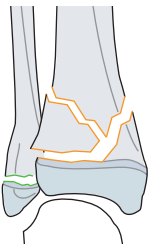
SH III tibial and SH I fibular fracture 43t-E/4.1, 43f-E/1.1



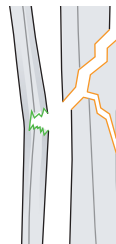Complete transverse (< 30°) tibial fracture and bowing fibular fracture 42t-D/4.1, 42f-D/1.1



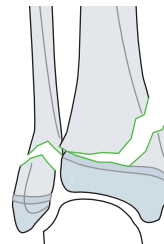
Multifragmentary epiphyseal tibia SH II and SH I fibular fracture 43t-E/2.2, 43f-E/1.1



Multifragmentary oblique or spiral (> 30°) tibial fracture and fibular greenstick fracture 42t-D/5.2, 42f-D/2.1



Distal: SH II tibial fracture and complete metaphyseal fibular fracture 43t-E/2.1, 43f-M/3.1



References

1. **Salter RB, Harris WR.** Injuries Involving the Epiphyseal Plate. *JBJS.* 1963;45(3):587–622.
2. **Baumann E. Ellbogen.** In Nigst, H, ed. *Spezielle Frakturen- und Luxationslehre: ein kurzes Handbuch in fünf Bänden. Band. II/1 ed.* Stuttgart: Thieme; 1965.
3. **Gartland JJ.** Management of supracondylar fractures of the humerus in children. *Surg Gynecol Obstet.* 1959 Aug;109(2):145–54.
4. **von Laer, L.** Frakturen und Luxationen im Wachstumsalter. 4. überarbeitete und aktualisierte Auflage ed. 2001.
5. **Judet J, Judet R, Lefranc J.** Fractures du col radial chez l'enfant. *Ann Chir.* 1962 Sep;16:1377–1385.
6. **von Laer L, Gruber R, Dallek M, et al.** Classification and documentation of children's fractures. *European Journal of Trauma.* 2000;26(1):2–14.
7. **Audige L, Bhandari M, Kellam J.** How reliable are reliability studies of fracture classifications? A systematic review of their methodologies. *Acta Orthop Scand.* 2004 Apr;75(2):184–194.
8. **Audigé L, Hunter J, Weinberg AM, et al.** Development and evaluation process of a pediatric long-bone fracture classification proposal. *European Journal of Trauma.* 2004;30(4):248–254.
9. **Audige L, Bhandari M, Hanson B, et al.** A concept for the validation of fracture classifications. *J Orthop Trauma.* 2005 Jul;19(6):401–406.
10. **Slongo T, Audigé L, Schlickewei W, et al.** Development and validation of the AO pediatric comprehensive classification of long bone fractures by the Pediatric Expert Group of the AO Foundation in collaboration with AO Clinical Investigation and Documentation and the International Association for Pediatric Traumatology. *J Pediatr Orthop.* 2006 Jan–Feb;26(1):43–49.
11. **Slongo T, Audigé L, Clavert JM, et al.** The AO comprehensive classification of pediatric long-bone fractures: a web-based multicenter agreement study. *J Pediatr Orthop.* 2007 Mar;27(2):171–180.
12. **Slongo T, Audigé L, Lutz N, et al.** Documentation of fracture severity with the AO classification of pediatric long-bone fractures. *Acta Orthop.* 2007 Apr;78(2):247–253.
13. **Müller ME, Nazarian S, Koch, P, et al.** *The Comprehensive Classification of Fractures of Long Bones.* Berlin, Heidelberg, New York: Springer-Verlag; 1990.

Unified Classification System for Periprosthetic Fractures (UCPF)

Principles

The UCPF is based upon the following factors:

1. The fracture location may involve either the bone supporting the implant or distant to it.
2. The stability of the components must be assessed to determine if the bone implant surface is stable prior to fracture and after fracture.
3. The adequacy of the bone stock and bone strength supporting the implant must be sufficient to support internal fixation or a revision without additional major reconstruction.
4. For clinical use, the definitions and terminology of the UCPF are used. In order to maintain consistency in coding and allow easy data retrieval for data collection, the UCPF has been modified so that the AO/OTA bone code appears first.
5. The UCPF code follows as a qualification in square brackets.
6. Fractures about or in a bone with a nonarthroplasty implant are coded using the universal modifier [12] following the AO/OTA fracture code.

Classification and coding process

1. The bone is identified by the AO/OTA code (see **Fig 1**). The fracture morphology may be classified in as much detail as needed.
2. The UCPF for the joint involved is added as a modifier in square brackets [] after the bone code (see **Fig 1**).
3. The fracture type is based on the location of the fracture in relation to the implant as follows:
 - **Apophysis adjacent implant with no effect on implant stability—Type A**
 - Tuberosities of the humerus
 - Epicondyles or olecranon of distal humerus
 - Trochanters and epicondyles of femur
 - Spines of the pelvis
 - Poles or tips of the patella
 - Tibial tuberosity and malleoli
 - **Bed of the implant or around the implant—Type B**
 - Good bone no implant loosening—Type B1
 - Good bone but implant loose—Type B2
 - Poor bone or defect, implant loose—Type B3
 - **Clear of the implant—Type C**
 - **Dividing the bone between two implants—Type D**
 - **Each of the two bones supporting the implant—Type E**
 - **Facing and articulating with a hemiarthroplasty—Type F**

The table provides the unified codes that follow the fracture classification.

Example: A spiral fracture about a femoral prosthesis of a total hip, which on x-rays shows loosening of the implant but good bone stock = 32A1[IVB2]

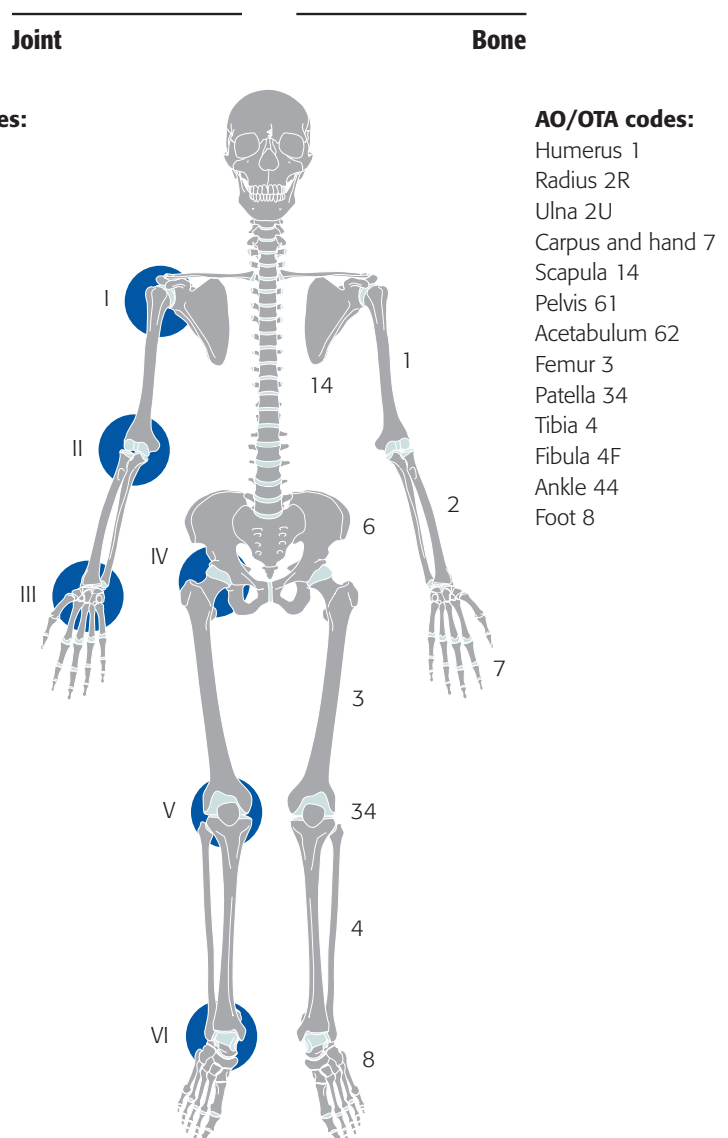





Fig 1 AO/OTA bone codes and UCPF joint codes.

		I Shoulder 		II Elbow 		III Wrist 		
		I.14	I.1	II.1	II.2	III.2	III.7	
Type		Glenoid/scapula	Humerus, proximal	Humerus, distal	Ulna/radius, proximal	Radius/ulna, distal	Carpus/metacarpals	
A Apophyseal or extraarticular/periarticular	A1 Avulsion of	Coracoid process	Greater tuberosity	Lateral epicondyle	Olecranon tip	Radial styloid	–	
	A2 Avulsion of	Acromion	Lesser tuberosity	Medial epicondyle	Coronoid process, radial tuberosity	Ulnar styloid, if ulna retained	–	
B Bed of the implant or around the implant	B1 Prosthesis stable, good bone	Glenoid implant stable, good bone	Humeral implant stable, good bone	Humeral implant stable, good bone	Ulnar implant stable, good bone	Radial implant stable, good bone	Carpal/metacarpal implant stable, good bone	
	B2 Prosthesis loose, good bone	Glenoid implant loose, good bone	Humeral implant loose, good bone	Humeral implant loose, good bone	Ulnar implant loose, good bone	Radial implant loose, good bone	Carpal/metacarpal implant loose, good bone	
	B3 Prosthesis loose, poor bone or bone defect	Glenoid implant loose, poor bone, defect	Humeral implant loose, poor bone, defect	Humeral implant loose, poor bone, defect	Ulnar implant loose, poor bone, defect	Radial implant loose, poor bone, defect	Carpal/metacarpal implant loose, poor bone, defect	
C Clear of or distant to the implant	–	Body of the scapula	Distal to the implant	Proximal to the implant	Distal to the implant	Proximal to the implant	Distal metacarpals	
D Dividing the bone between two implants or interprosthetic or intercalary	–	–	Between shoulder and elbow arthroplasties, close to the shoulder	Between shoulder and elbow arthroplasties, close to the elbow	–	Between wrist and radial-head prosthesis	–	
E Each of two bones supporting one arthroplasty or polyperiprosthetic	–	Scapula and humerus		Humerus and ulna/radius		Radius/ulna and carpus/metacarpals		
F Facing and articulating with a hemiarthroplasty	–	Fracture of the glenoid articulating with the humeral hemiarthroplasty	–	Distal humeral fracture articulating with the radial-head prosthesis	–	–	–	

IV Hip		V Knee			VI Ankle		Type
IV.6	IV.3	V.3	V.4	V.34	VI.4	VI.8	
Acetabulum/pelvis	Femur, proximal	Femur, distal	Tibia, proximal	Patella	Tibia, distal	Talus	A Apophyseal or extraarticular/periarticular
Anterior inferior and superior iliac spine	Greater trochanter	Lateral epicondyle	Medial or lateral plateau, nondisplaced	Disrupted extensor, proximal pole	Tip of the medial malleolus	–	
Ischial tuberosity	Lesser trochanter	Medial epicondyle	Tibial tubercle	Disrupted extensor, distal pole	Tip of the lateral malleolus	–	B Bed of the implant or around the implant
Acetabular rim or good bone	Stem stable, good bone; Surface replacement: femoral neck	Proximal to stable stem, good bone	Stem and component stable, good bone	Intact extensor, implant stable, good bone	Transverse or medial malleolus shear, good bone	Body of the talus, good bone	
Loose cup, good bone	Loose stem, good bone; Surface replacement: loose implant, no proximal femoral bone loss	Proximal to loose stem, good bone	Loose component/stem, good bone	Loose implant, good bone	Tibial implant loose, good bone	Body of the talus, loose, good bone	C Clear of or distant to the implant
Loose cup, poor bone, defect; Pelvic discontinuity	Loose stem, poor bone, defect; Surface replacement: loose implant, bone loss	Proximal to loose stem, poor bone defect	Loose component/stem, poor bone, defect	Loose implant, poor bone	Tibial implant loose, poor bone, defect	Body of the talus, bone defect	
Pelvic/acetabular fractures distant to the implant	Distal to the implant and cement mantle	Proximal to the implant and cement mantle	Distal to the implant and cement mantle	–	Proximal to the implant	Neck or head of the talus	D Dividing the bone between two implants or interprosthetic or intercalary
Pelvic fracture between bilateral total hip arthroplasties	Between hip and knee arthroplasties, close to the hip	Between hip and knee arthroplasties, close to the knee	Between ankle and knee arthroplasties, close to the knee	–	Between knee and ankle arthroplasties, close to the ankle	Between an ankle and talonavicular arthroplasties	
Pelvis and femur		Femur and tibia/patella			Tibia and talus		E Each of two bones supporting one arthroplasty or polyperiprosthetic
Fracture of the acetabulum articulating with the femoral hemiarthroplasty	–	Fracture of femoral condyle articulating with tibial hemiarthroplasty	–	Fracture of the patella that has no surface replacement and articulates with the femoral component of the total knee arthroplasty	–	–	F Facing and articulating with a hemiarthroplasty

Reference

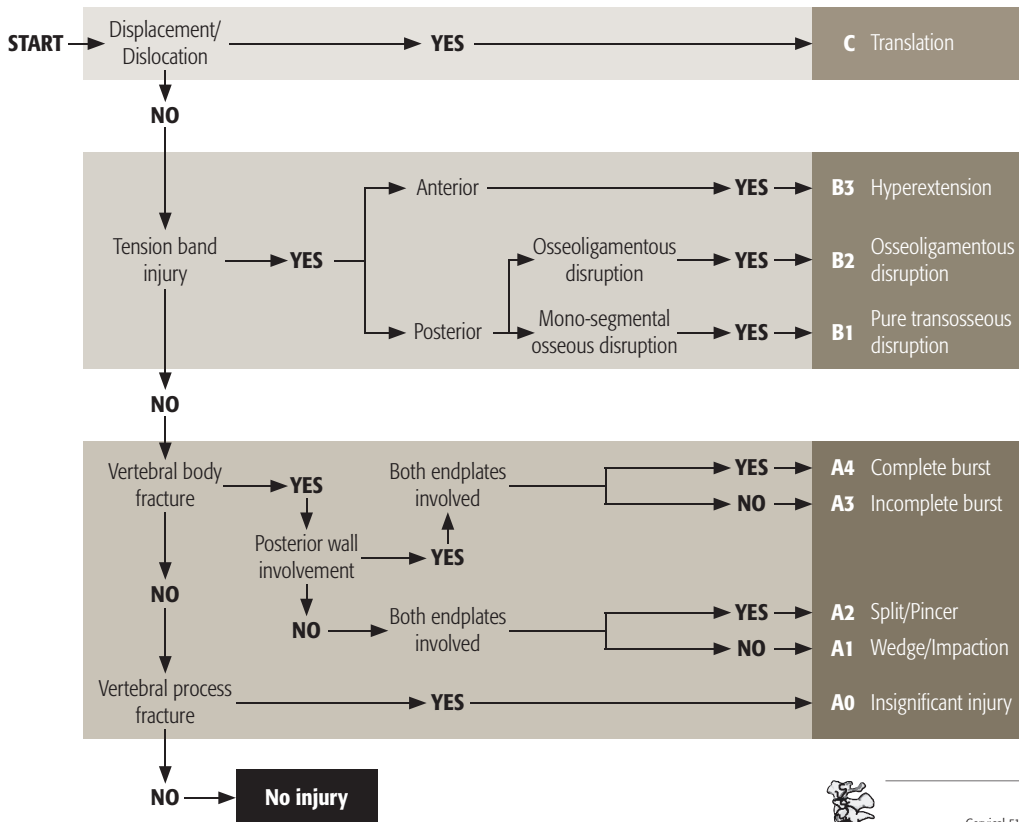
Duncan CP, Haddad FS. Classification. In: Schütz M, Perka C, ed. *Periprosthetic Fracture Management*. Stuttgart: Georg Thieme; 2013:47–90.

Spine

Diagnostic and coding process

This classification system includes morphological injury characteristics, as well as neurological and patient-specific modifiers to augment the clinical relevance.

Algorithm for morphologic classification



Bone: Spine 5

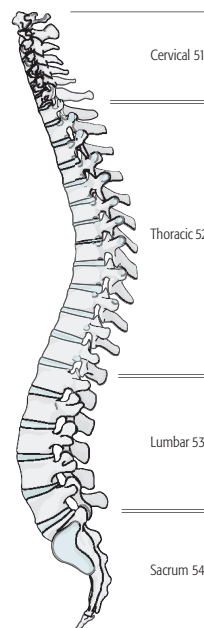
Locations:

Spine, **Cervical 51**, **Thoracic 52**, **Lumbar 53**, and **Sacrum 54**

→ The vertebral body number is added between two dots. . after the location code. Example: Fracture of thoracic vertebra 7 is 52.7

→ The motion segment—the numbers of the two vertebral bodies involved are separated by a back slash between two dots / . placed after the location code.

Example: Fracture dislocation of thoracic vertebra 7 on 8 is 52.7/8.



Cervical spine

Location: Spine, **upper cervical (C1 or C2)** 51.__X

- The classification for this region is presently under development
- The axial spine is defined as cervical vertebra 1 and 2
- The generic fracture code 51.__X is used to code these injuries

Location: Spine, **subaxial cervical spine (vertebra 3 to 7)**

Types:

Spine, subaxial cervical, **compression injury of the vertebral body** 51.__A

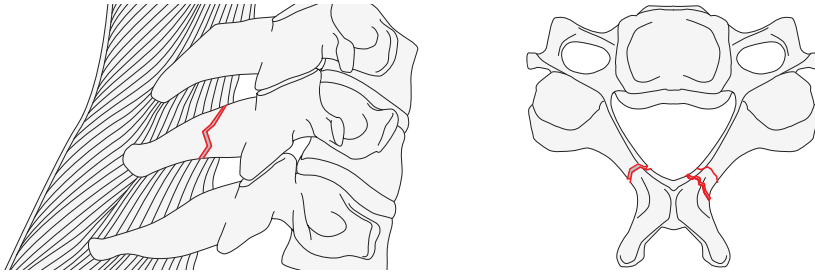
Spine, subaxial cervical, **tension band injury** 51.__B

Spine, subaxial cervical, **displacement/translational injury** 51.__C

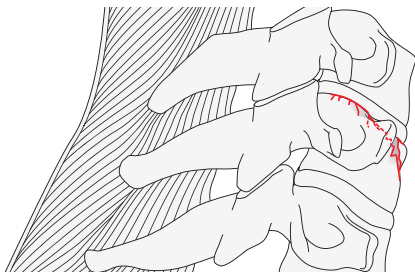
51.__A

Type: Spine, subaxial cervical, **compression injury of the vertebral body** 51.__A

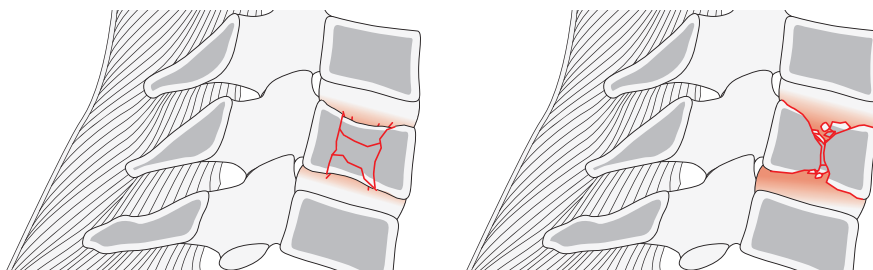
Group: Spine, subaxial cervical, compression injury, **minor nonstructural fracture** (eg. spinous process) 51.__A0



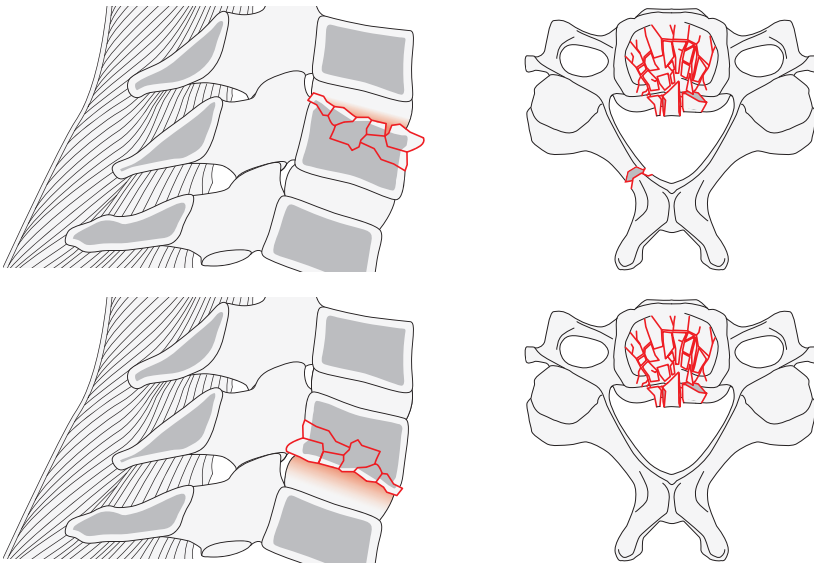
Group: Spine, subaxial cervical, compression injury, **compression or impaction fractures of a single endplate without involvement of the posterior wall of the vertebral body** 51.__A1



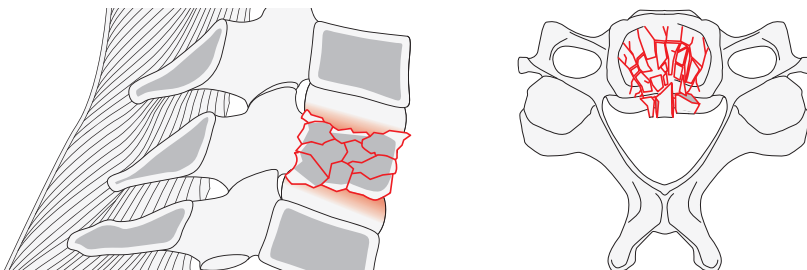
Group: Spine, subaxial cervical, compression injury, **coronal split of pincers type fractures involving both end plates without posterior vertebral wall involvement** 51.__A2



Group: Spine, cervical, compression injuries, **incomplete burst fractures involving a single endplate with any involvement of the posterior vertebral wall** 51.__A3



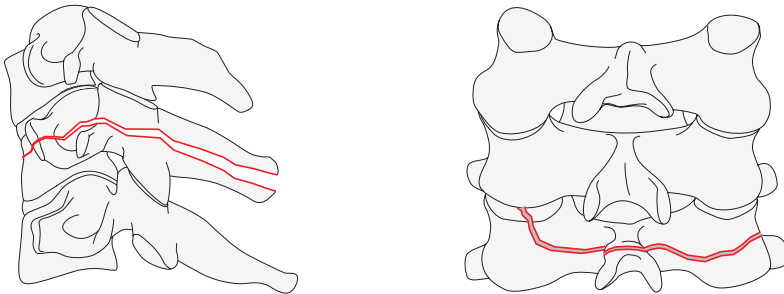
Group: Spine, cervical, compression injuries, **complete burst fractures involving both endplates as well as the posterior vertebral wall** 51.__A4



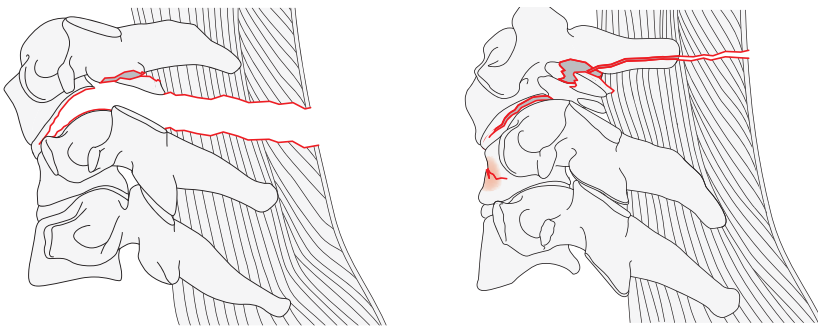
51._B

Type: Spine, subaxial cervical, **tension band injury** 51._B

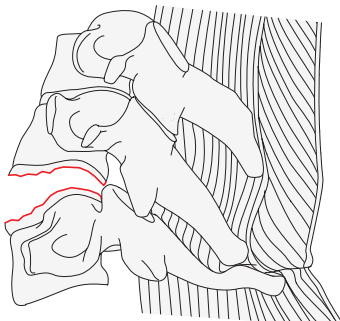
Group: Spine, subaxial cervical, tension band injury, **monosegmental osseous failure of the posterior tension band extending into vertebral body (Chance Fracture)** 51._B1*



Group: Spine, subaxial cervical, tension band injury, **disruption of the posterior tension band with or without osseous involvement. Posterior tension band injury maybe bone, capsule or ligament or a combination** 51._B2*

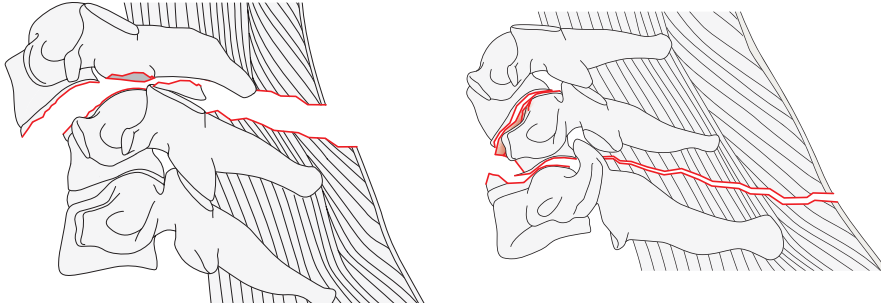


Group: Spine, subaxial cervical, tension band injury, **anterior tension band injury with physical disruption or separation of the anterior structures (bone/disk) with a tethering of the posterior elements** 51._B3*



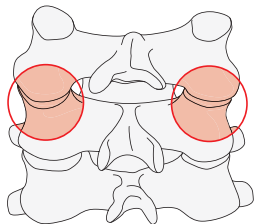
51._C

Type: Spine, subaxial cervical, **displacement/translational injury** 51._C*



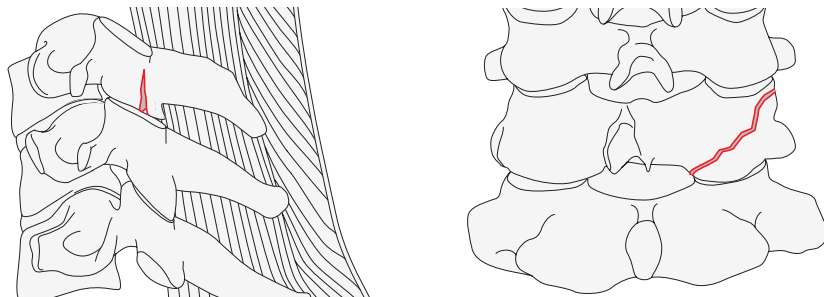
***Qualifications:**

bl = Bilateral posterior injuries

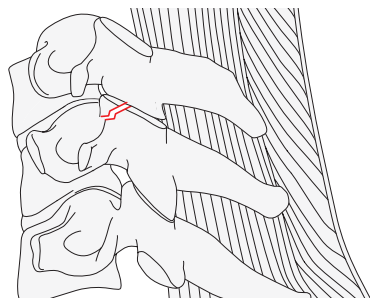


F = Facet Injuries

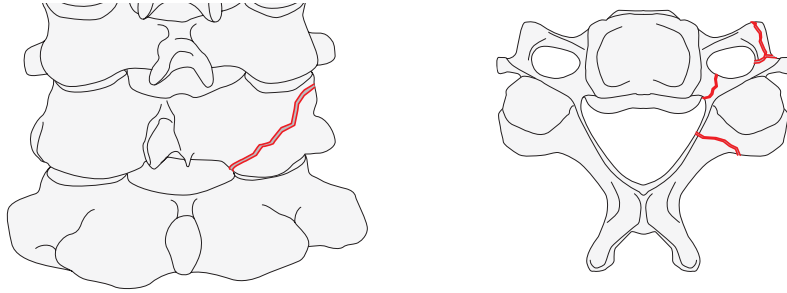
F1: Nondisplaced facet injuries (fragment <1 cm and < 40% of lateral mass)



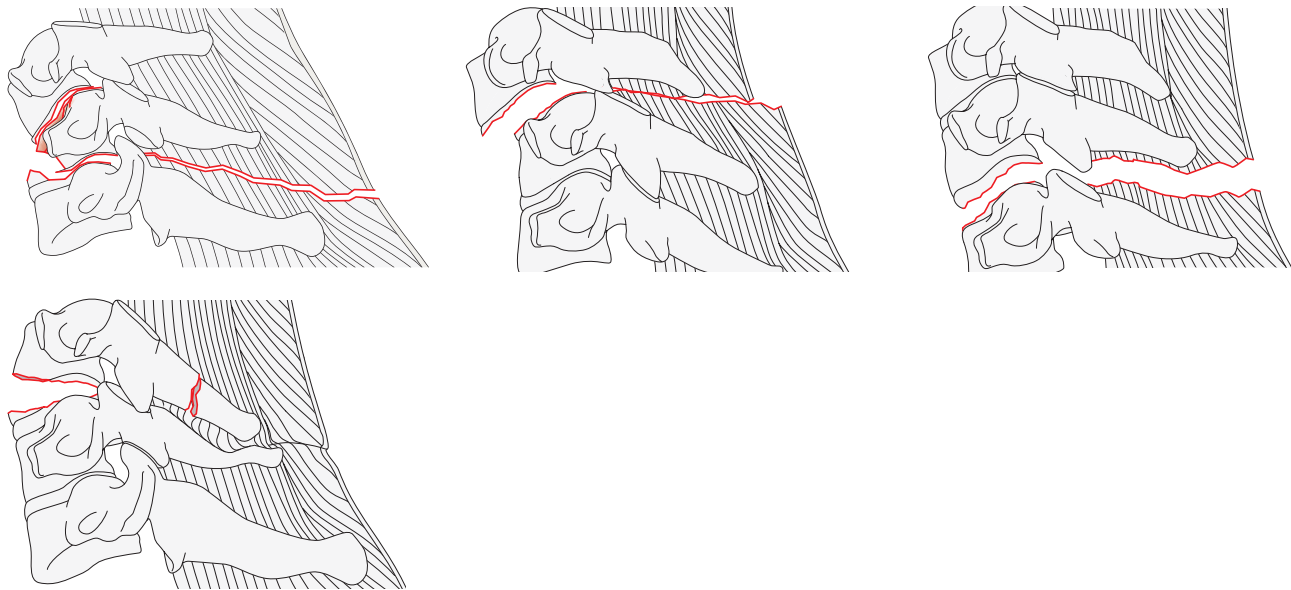
F2: Facet fracture with potential for instability (fragment >1cm and >40% of lateral mass or displaced)



F3: Floating lateral mass



F4: Subluxation of perched/dislocated facet



Qualifications for neurological deficit grades (applicable to all cervical spine codes):

These grades are added to any spinal code to identify the neurological deficit. They are added to the end of code between (_). Multiple qualifications are separated by a comma.

- NX cannot be examined
- N0 neurologically intact
- N1 transient neurological deficit
- N2 nerve root injury
- N3 cauda equina injury or incomplete spinal cord injury
- N4 complete spinal cord injury (unlikely in sacral fractures)
- + ongoing cord compression in the setting of an incomplete neurological deficit.

Qualifications for patient specific conditions (applicable to all cervical spine codes):

- M1 posterior capsuloligamentous complex injury without complete disruption
- M2 critical disk herniation
- M3 Stiffening/metabolic bone disease (ie, DISH, AS, OPL, OLF)
- M4 Vertebral artery abnormality.

Qualifications are added at the end of the code between rounded brackets (_).

Thoracic or Lumbar spine

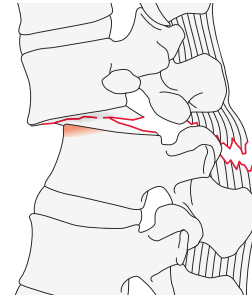
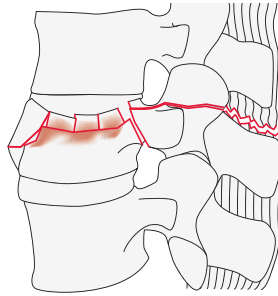
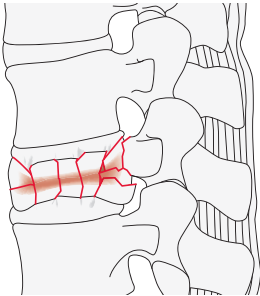
Location: Spine, **thoracic** 52.___ or **lumbar** 53.___.

Types:

Spine, thoracic or lumbar, **compression injury of the vertebral body**
52.___A or 53.___A

Spine, thoracic or lumbar, **tension band injury**
52 __.B or 53. __B

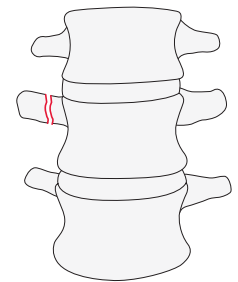
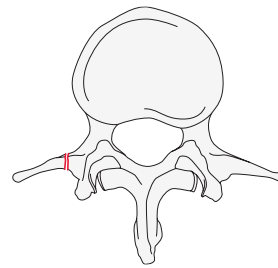
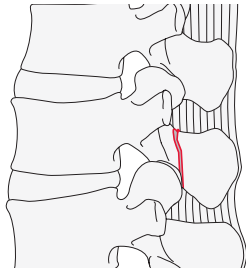
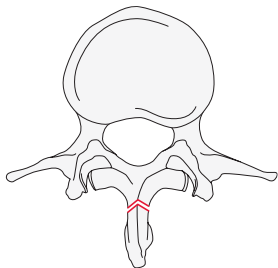
Spine thoracic or lumbar, **displacement/translational Injury**
52.___C or 53.___C



52.___A or 53.___A

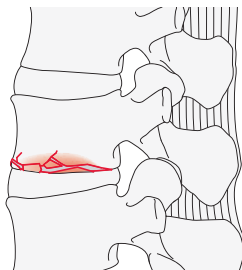
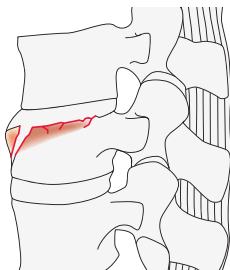
Type: Spine, thoracic or lumbar, **compression injury of the vertebra**
52.___A or 53.___A

Group: Spine, thoracic or lumbar, compression injury of the vertebra, **minor nonstructural fractures** (ie, spinous or transverse processes)
52.___A0 or 53.___A0



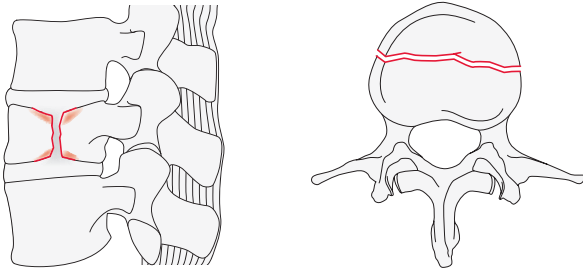
Group: Spine, thoracic or lumbar, compression injury of the vertebra, **compression or impaction fractures of a single endplate without involvement of the posterior wall of the vertebral body**

52.___A1 or 53.___A1



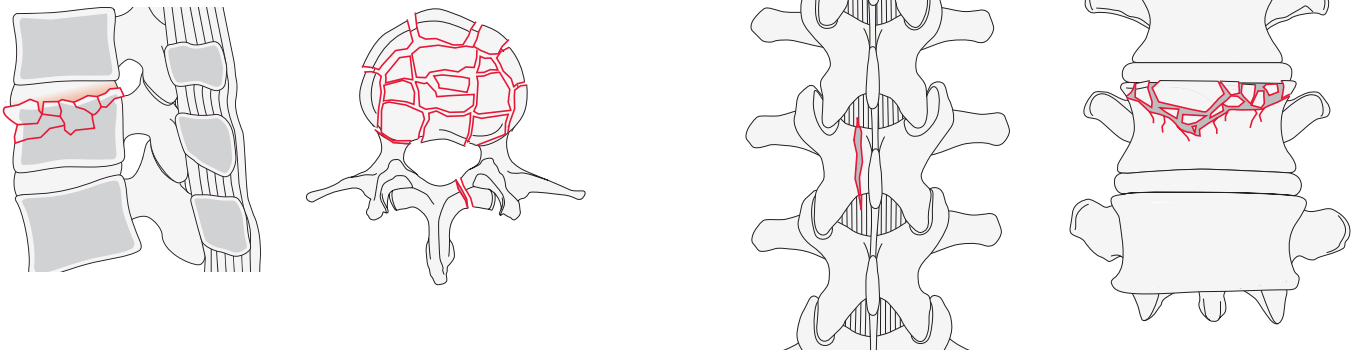
Group: Spine, thoracic or lumbar, compression injury of the vertebra, **coronal split of pincers type fractures involving both endplates without posterior vertebral wall involvement**

52.___A2 or 53.___A2



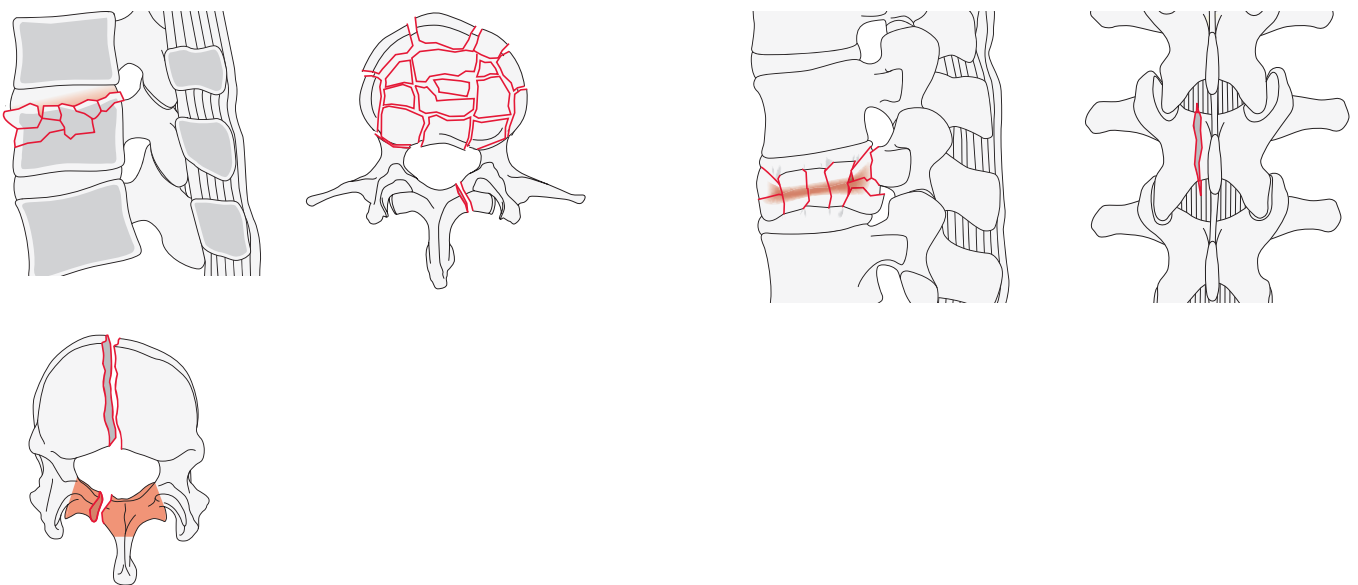
Group: Spine, thoracic or lumbar, compression injury to the vertebra, **incomplete burst fracture involving a single endplate with any involvement of the posterior vertebral wall**

52.___A3 or 53.___A3



Group: Spine, thoracic or lumbar, compression injury to the vertebra, **complete burst fracture involving both endplates as well as the posterior wall**

52.___A4 or 53.___A4

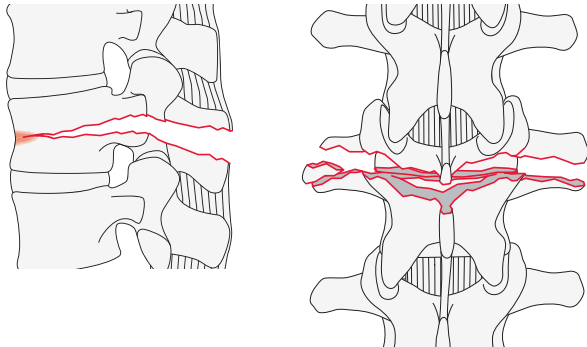


52.__.B or 53.__.B

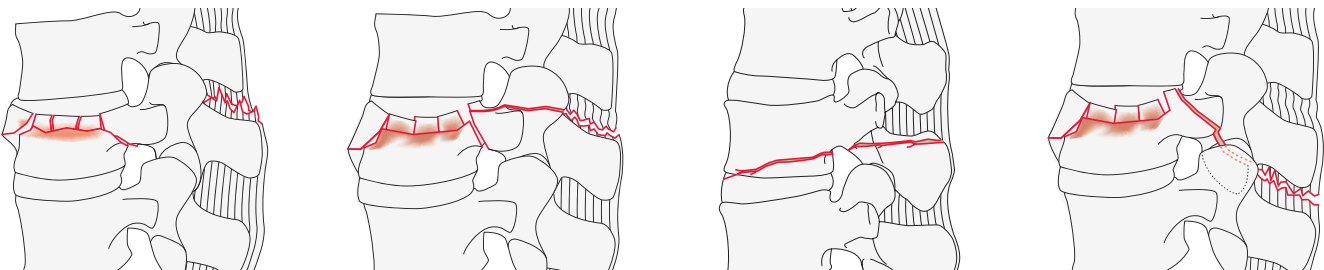
Type: Spine, thoracic or lumbar, **tension band injury** 52.__.B or 53.__.B

Group: Spine, thoracic or lumbar, distraction injury, **monosegmental osseous failure of the posterior tension band extending into the vertebral body (Chance fracture)**

52.__.B1 or 53.__.B1

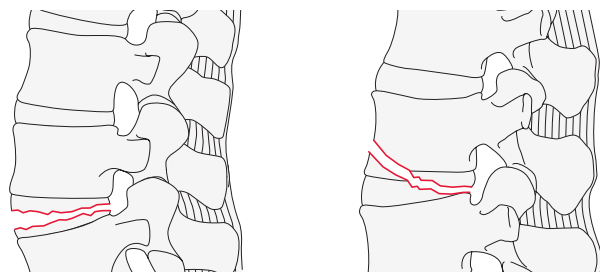


Group: Spine, thoracic or lumbar, distraction injury, **disruption of the posterior tension band with or without osseous involvement. Posterior tension band injury maybe bone, capsule, ligament or a combination** 52.__.B2 or 53.__.B2



Group: Spine, thoracic or lumbar, distraction injury, **anterior tension band injury with disruption or separation of the anterior bone and/or disc with tethering of the posterior elements**

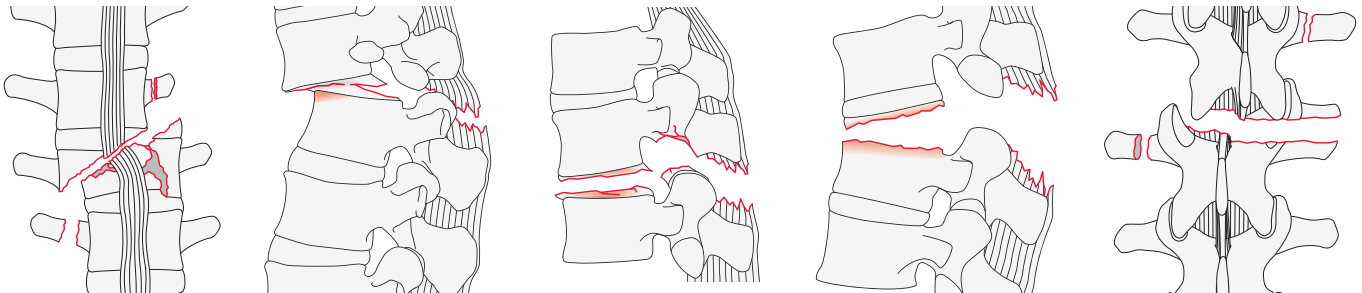
52.__.B3 or 53.__.B3



52.__.C/53.__.C**Type:** Spine, thoracic or lumbar, **displacement/translational injury**

52.__.C or 53.__.C

Failure of all elements leading to dislocation, displacement or translation in any plane or complete disruption of a soft tissue hinge even in the absence of any translation. Can be combined with subtypes of A and B allowing for two separate codes for the injury

**Qualifications for neurological deficit grades (applicable to all thoracic or lumbar spine codes):**

These grades are added to any spinal code to identify the neurological deficit. They are added to the end of code between (__). Multiple qualifications are separated by a comma.

- NX cannot be examined
- N0 neurologically intact
- N1 transient neurological deficit
- N2 nerve root injury
- N3 cauda equina injury or incomplete spinal cord injury
- N4 complete spinal cord injury
- + Indicates there is ongoing cord compression in the setting of an incomplete neurological deficit.

Qualifications for patient specific conditions (applicable to all thoracic or lumbar spine codes):

- M1 Used to designate fractures with an indeterminate injury to the tension band based on spinal imaging with or without MRI. This modifier is important for designating those injuries with stable injuries from a bony standpoint for which ligamentous insufficiency may help determine whether operative stabilization is a consideration.
- M2 Used to designate a patient-specific comorbidity, which might argue either for or against surgery for patients with relative surgical indications. Examples of an M2 modifier include ankylosing spondylitis or burns affecting the skin overlying the injured spine.

Sacral spine

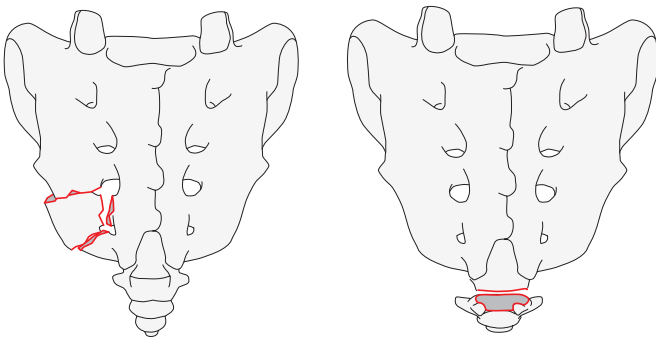
Location: Spine, **sacrum** 54

This classification is intended to be used for isolated sacral fractures not associated with a pelvic ring injury. As the sacrum is part of the posterior pelvic ring arch, sacral fractures are a major component of determining the stability of a pelvic ring injury. Consequently, sacral fractures associated with a pelvic ring injury (61) are recommended to be classified in that category using the qualification modifiers.

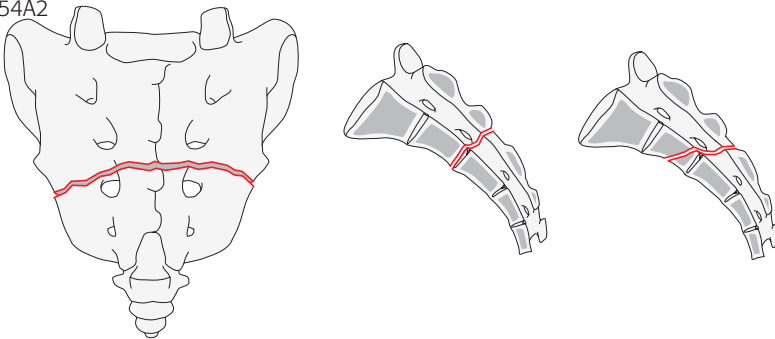
54A

Type: Spine, sacrum, **fractures of the lower segments not associated with sacroiliac joint.** (Injuries with no impact on pelvic or spino-pelvis stability They may have a neurological injury.) 54A

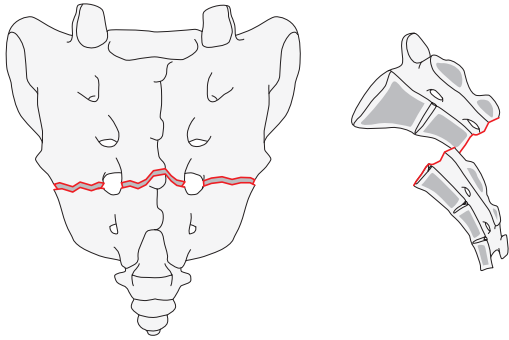
Group: Spine, sacrum, fractures of the lower sacral segments not associated with sacroiliac joint, **coccygeal or sacral compression injuries** 54A1



Group: Spine, sacrum, fractures of the lower sacral segments not associated with sacroiliac joint, **transverse fractures, nondisplaced** 54A2



Group: Spine, sacrum, fractures of the lower sacral segments not associated with sacroiliac joint, **transverse fractures, displaced** 54A3

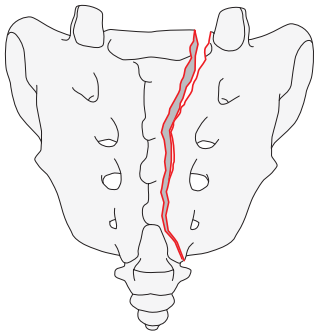


54B

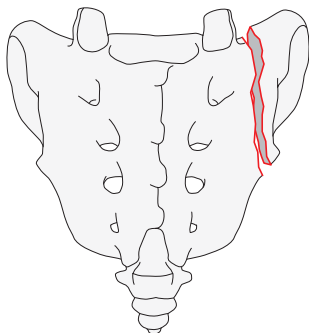
Type: Spine, sacrum, **fractures involving the upper sacral segments associated with sacroiliac joint** 54B

These are unilateral longitudinal or vertical fractures that occur through the upper sacral segments that are associated with the sacroiliac joint. These will have an impact on pelvic stability. They may have neurological injury. The groups are ordered differently than the published Denis classification or the former compendiums.

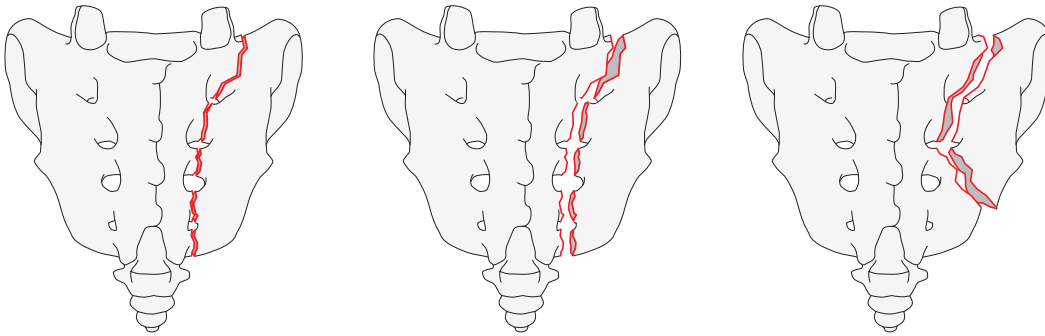
Group: Spine, sacrum, fractures involving the upper sacral segments associated with sacroiliac joint, **isolated vertical central fractures medial to the foramina involving the spinal canal (Denis III)** 54B1



Group: Spine, sacrum, fractures involving the upper sacral segments associated with sacroiliac joint, **transalar fractures lateral to the foramina or spinal canal (Denis I)** 54B2



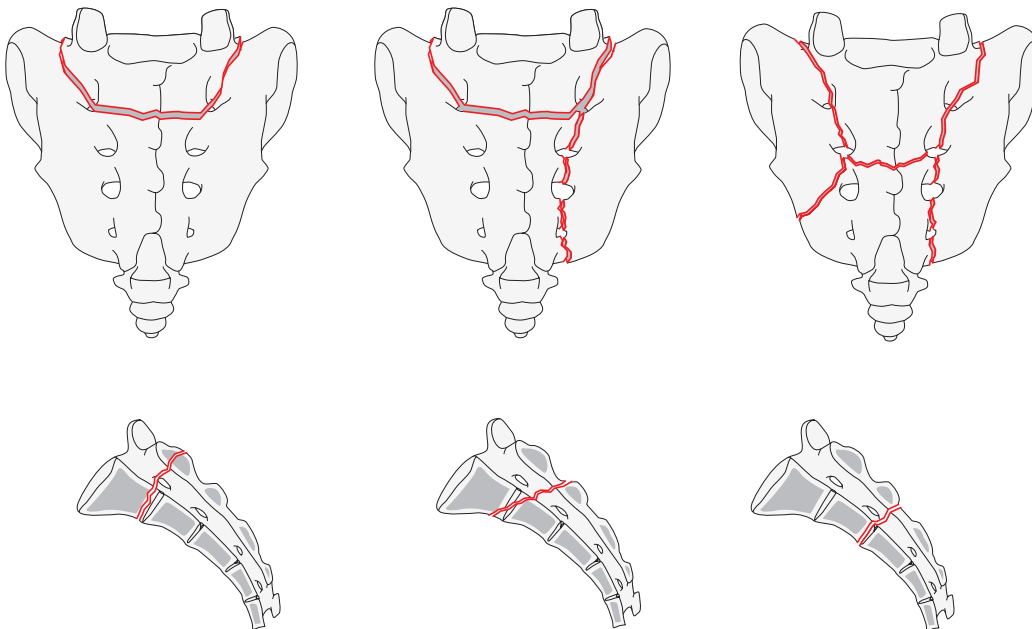
Group: Spine, sacrum, fractures involving the upper sacral segments associated with sacroiliac joint, **transforaminal fractures involving the foramina but not the spinal canal (Denis II)** 54B3



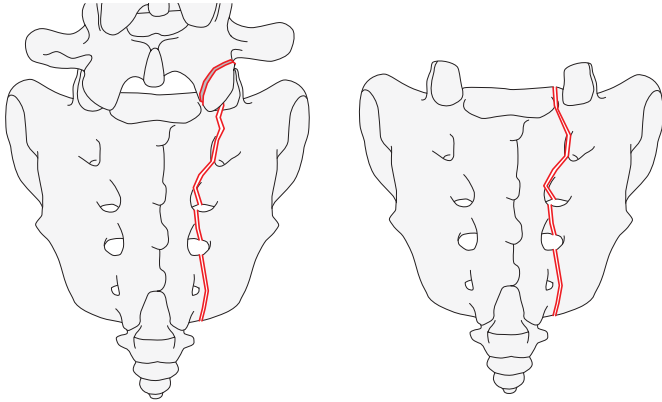
54C

Type: Spine, sacrum, **injuries resulting in spino-pelvic instability** 55C

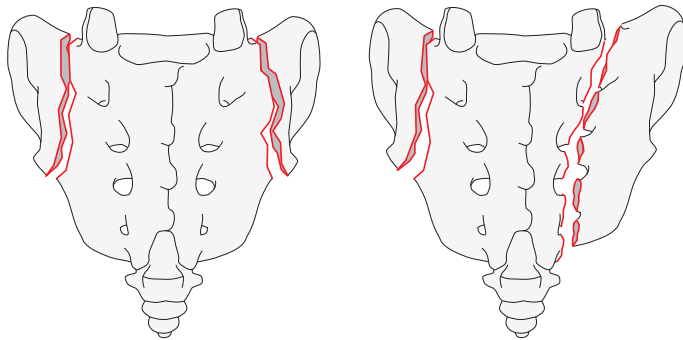
Group: Spine, sacrum, injuries resulting in spino-pelvic instability, **non-displaced U-type variant (commonly low energy insufficiency fracture)** 55C0



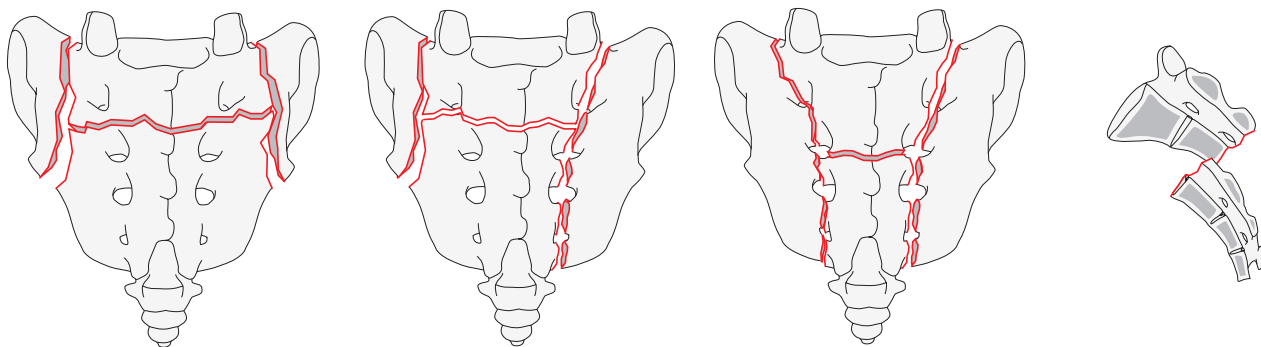
Group: Spine, sacrum, injury resulting in spino-pelvic instability, **U-type variant without posterior pelvic instability** (any unilateral B group fracture where ipsilateral S1 facet is discontinuous with medial part of sacrum) 54C1



Group: Spine, sacrum, injury resulting in spino-pelvic instability, **bilateral complete B-type injuries without transverse fracture** 54C2



Group: Spine, sacrum, injury resulting in spino-pelvic instability, **displaced U-type fracture** 54C3



Qualifications for neurological deficit grades (applicable to all sacral spine codes):

These grades are added to any spinal code to identify the neurological deficit. They are added to the end of code between (__). Multiple qualifications are separated by a comma.

- NX cannot be examined
- N0 neurologically intact
- N1 transient neurological deficit
- N2 nerve root injury
- N3 cauda equina injury or incomplete spinal cord injury

Qualifications for patient specific conditions (applicable to all sacral spine codes):

- M1 soft tissue injury
- M2 metabolic bone disease
- M3 Anterior pelvic ring injury
- M4 Sacroiliac joint injury

References

AOSpine Injury Classification Systems. AOSpine website. <https://aospine.aofoundation.org/Structure/education/online-education/classifications/Pages/classifications.aspx>. Accessed July 7, 2017.

Kepler CK, Vaccaro AR, Koerner JD, et al. Reliability analysis of the AOSpine thoracolumbar spine injury classification system by a worldwide group of naive spinal surgeons. *Eur Spine J.* 2016 Apr;25(4):1082–1086.

Schnake KJ, Schroeder GD, Vaccaro AR, et al. AOSpine Classification Systems (Subaxial, Thoracolumbar). *J Orthop Trauma.* 2017 Sep;31 Suppl 4:S14–s23.

Vaccaro AR, Koerner JD, Radcliff KE, et al. AOSpine subaxial cervical spine injury classification system. *Eur Spine J.* 2016 Jul;25(7):2173–2184.

Vaccaro AR, Oner C, Kepler CK, et al. AOSpine thoracolumbar spine injury classification system: fracture description, neurological status, and key modifiers. *Spine (Phila Pa 1976).* 2013 Nov 01;38(23):2028–2037.

Thorax

Anatomical location: Thorax 16

Bone: Thorax, Rib*

The ribs are identified as follows:

Right side = 16.1.____

Left side = 16.2.____

Rib number = 1 to 12

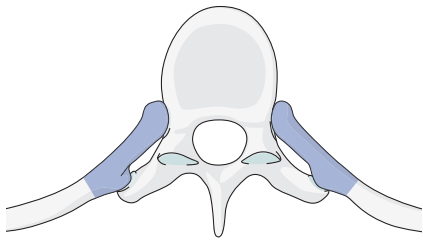
→ The body side and rib number are added to the code (between dots ____ after the bone code.
Example: Left second rib is 16.2.2.

→ **Bone.left or right.rib number.location**

Locations:

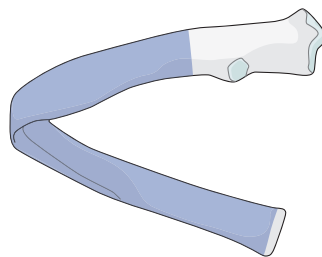
Rib, **posterior end segment**

16.____.1



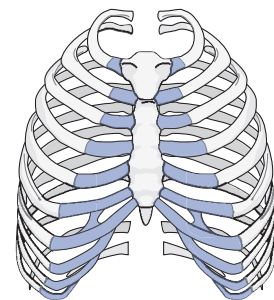
Rib, **shaft**

16.____.2



Rib, **anterior end segment**

16.____.3



The portion of the rib from the costovertebral joint to the tip of the transverse process (costotransverse articulations).

The bone between the two end segments.

The costochondral cartilage.

→ The location number is added after the bone code and rib number identifier.

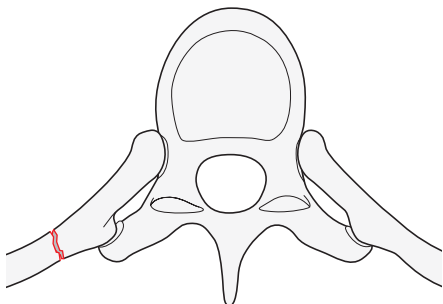
Example: Left second rib, posterior segment fracture is 16.2.2.1

Location: Rib, posterior end segment 16.____.1

Types:

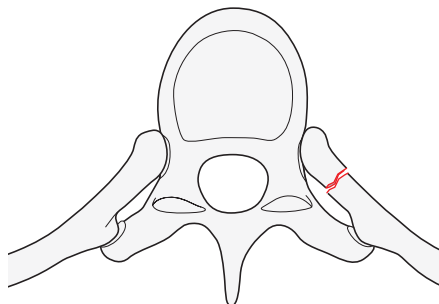
Rib, posterior end segment, **extraarticular fracture**

16.____.1A*



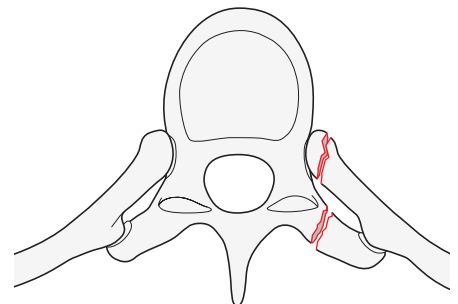
Rib, posterior end segment, **partial costotransverse disruption**

16.____.1B*



Rib, posterior end segment, **complete costotransverse disruption**

16.____.1C*

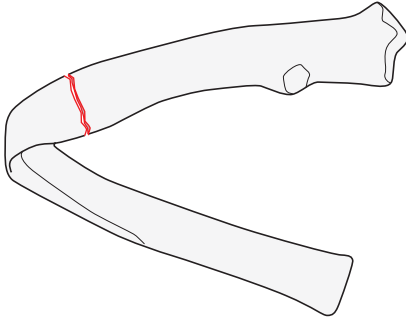


Qualifications are optional and applied to the fracture code where the asterisk is located as a lower-case letter within rounded brackets. More than one qualification can be applied for a given fracture classification, separated by a comma. For a more detailed explanation, see the compendium introduction.

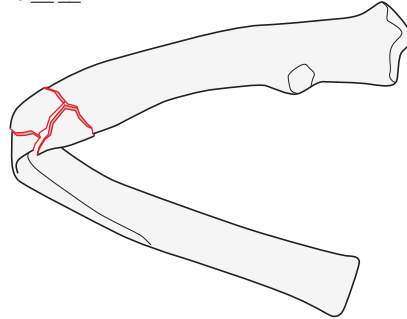
Location: Rib, shaft 16.____.2

Types:

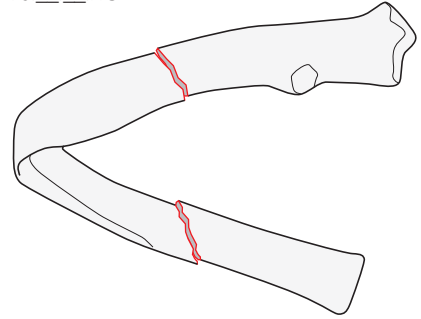
Rib, shaft, **simple fracture**
16.____.2A*



Rib, shaft, **multifragmentary wedge fracture**
16.____.2B*



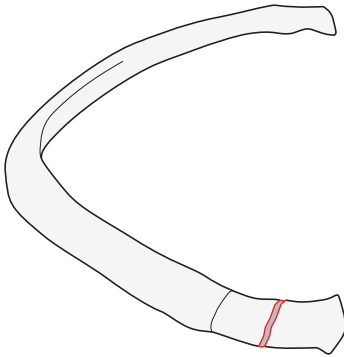
Rib, shaft, **multifragmentary segmental fracture**
16.____.2C*



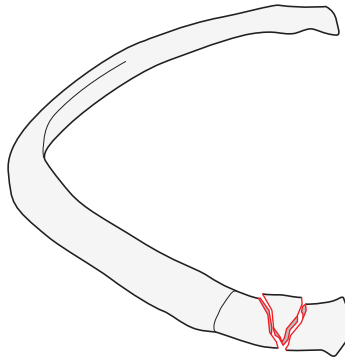
Location: Rib, anterior end segment 16.____.3

Types:

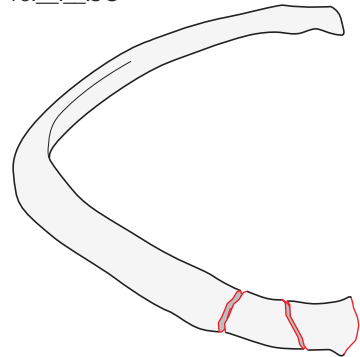
Rib, anterior end segment, **simple fracture**
16.____.3A*



Rib, anterior end segment, **wedge fracture**
16.____.3B*



Rib, anterior end segment, **multifragmentary fracture**
16.____.3C*



*Qualification for all rib fractures:

- f Flail segment—for each fracture that is part of a flail segment
- s fracture series—for each fracture that is part of a rib fractures series

→ The type character is added after the location code.
Example: Right 9th rib, shaft, simple lateral fracture 16.1.9.2A

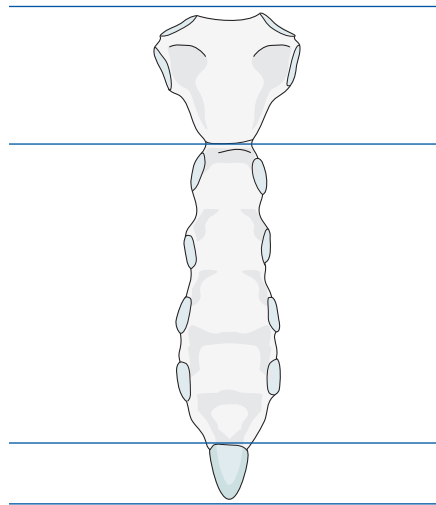
Coding of multiple fractures

Use a separate code for each fractured rib.

Thorax—Sternum

Bone: Thorax, Sternum 16.3._.

Locations:



Sternum, **manubrium fracture**
16.3.1

Sternum, **body fracture**
16.3.2

Sternum, **xiphoid fracture**
16.3.3

→ The location number is added to the code between two dots after the bone code.

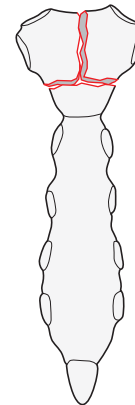
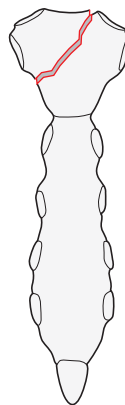
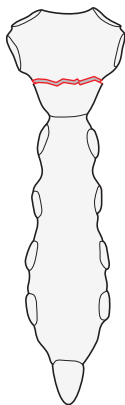
Location: Sternum, **manubrium fracture** 16.3.1.

Types:

Sternum, manubrium, **transverse fracture**
16.3.1.A

Sternum, manubrium, **oblique fracture**
16.3.1.B

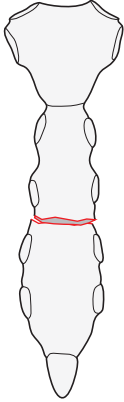
Sternum, manubrium, **multifragmentary fracture**
16.3.1.C



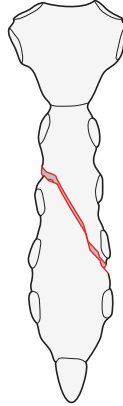
Location: Sternum, **body fracture** 16.3.2.

Types:

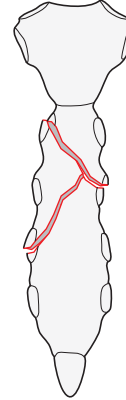
Sternum body fracture, **transverse (sagittal instability) fracture** 16.3.2.A



Sternum body fracture, **oblique fracture** 16.3.2.B



Sternum body fracture, **multifragmentary fracture** 16.3.2.C

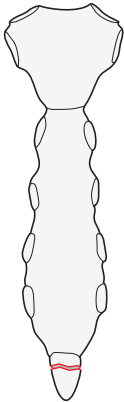


Example: Simple fracture of sternal body 16.3.2.A

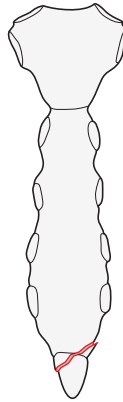
Location: Sternum, **xiphoid fracture** 16.3.3.

Types:

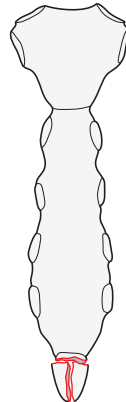
Sternum, xiphoid, **transverse fracture or avulsion (sagittal instability)** 16.3.3.A



Sternum, xiphoid, **oblique (partial avulsion) fracture** 16.3.3.B



Sternum, xiphoid, **multifragmentary fracture** 16.3.3.C



Universal fracture modifiers for the thorax section only

- Universal modifiers may be added to the end of the fracture code within squared brackets [1]
- Multiple universal modifiers may be contained within the same set of squared brackets and separated by a comma and no space [1,2,3,etc]

1	Lung contusion
2	Pneumothorax
3	Hemothorax
4	Cardiac injury
5	Great vessel injury
6	Intercostal artery injury
7	Soft tissue injury

Acknowledgements

The Thoracic segment classification has been developed with the collaboration of the AO Foundation TK Thoracic Surgery Expert Group. The members are:

Michael Bemelman, MD; St Elisabeth Hospital, Department of Surgery and Trauma, Hilvarenbeekseweg 60, 5022 GC, Tilburg, Netherlands.

Edward A Black, FRCS; Cardiothoracic Department, PO Box 1006, Al Ain, United Arab Emirates.

Mario Gasparri, MD; SSM Health, St Mary's Madison, Division of Thoracic Surgery; 700 S Park Street, Madison, WI 53715, USA.

Arthur T Martella, MD; University of Pennsylvania, School of Medicine, Department of Cardiothoracic Surgery; MOB 824 Main Street, Suite 302, Phoenixville, PA 19460, USA.

Fredric M Pieracci, MD/MPH, FACS; Associate Professor of Surgery, University of Colorado Denver SOM, 777 Bannock Street, Denver, CO 80204, USA.

Stefan Schulz-Drost, MD, PhD, FEBS.EmSurg; Senior Surgeon, Unfallkrankenhaus Berlin, Department of Trauma and Orthopedic Surgery, Warener Strasse 7, 12683 Berlin, and University Hospital Erlangen, Department of Trauma Surgery, Krankenhausstrasse 12, 91054 Erlangen, Germany.

Qualifications are optional and applied to the fracture code where the asterisk is located as a lower-case letter within rounded brackets. More than one qualification can be applied for a given fracture classification, separated by a comma. For a more detailed explanation, see the compendium introduction.

Appendix

In this section, guides to help the coder classify fractures are provided. Within each bone segment, references are made to this section if specific definitions or suggestions for coding are required.

Radius and Ulna

To facilitate the coding of radius and ulna fractures, they are coded by the individual bone. The following guidelines are suggested:

- The location of the end segment requires that the square has as its side dimension the widest part of the end segment, which includes both the radius and ulna (**Fig 1**).

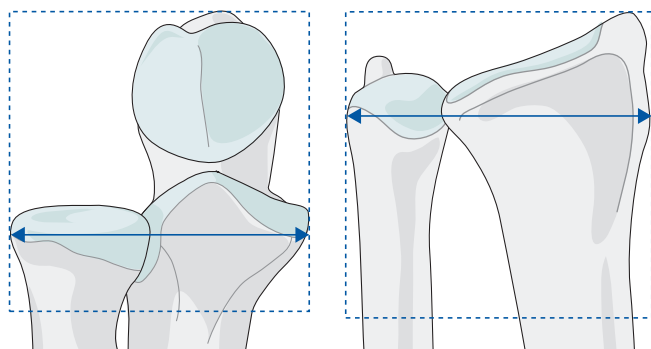
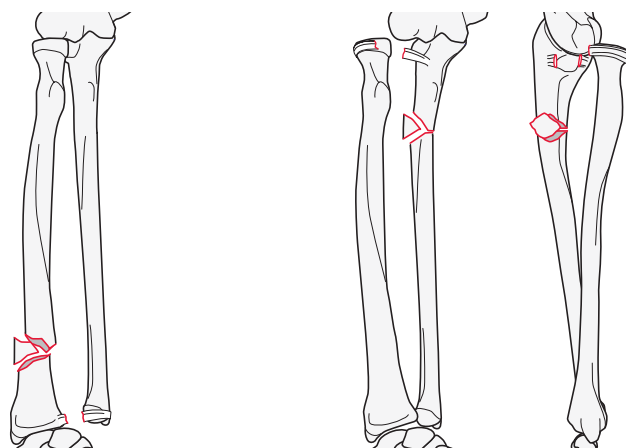


Fig 1 Determine the location of the end segment.

- Each fracture is coded, stored, and searched for separately ie, as two codes.
- **Galeazzi** and **Monteggia** fracture codes:
 - Galeazzi and Monteggia fracture patterns consist of a shaft fracture with associated joint dislocation or injury. The code for the injury complex is the radius or ulna fracture code with a qualifier of **g** for Galeazzi representing disruption of the distal radioulnar joint (DRUJ) and **m** for Monteggia representing disruption of the proximal radio-ulnar joint (PRUJ). This qualification is placed at the end of the code in round brackets (___).
 - If the coder feels that it is necessary to code for joint dislocation and its direction, the dislocation code from the universal modifiers is added within square brackets [5_] following the round brackets (**Fig 2**).



Galeazzi

Radial shaft, distal diaphysis, intact wedge fracture = 2R2B2(c) with dislocation of distal radio-ulnar joint 2R2B2(c,g)

Monteggia

Ulna, proximal diaphysis, intact wedge fracture = 2U2B2(a) with anterior dislocation of proximal radio-ulnar joint [5a] = 2U2B2(a,m)[5a]

Fig 2 Example of a Galeazzi and a Monteggia fracture.

Femur

It is recognized that there is an ongoing controversy concerning the proper terminology for trochanteric fractures (James Krieg, personal communication, October 2016; Christopher Colton, personal communication, May 2017).¹⁻⁵ The CCF and past compendiums have established that the term **peritrochanteric means through the trochanters** as shown in group A1 and group A2. **Intertrochanteric means between trochanters** as represented in group A3. This term should be preferred to reverse oblique. To remain consistent, this revision maintains these definitions and recommends their use as noted above.

The coding system separates the peritrochanteric fractures into two groups (A1 and A2) based on the amount of fragmentation in the trochanteric region. The differentiation between groups is defined by the **lateral wall height (d)** of the greater trochanter (**Fig 3**). Lateral wall height or thickness is defined as the distance in millimeters (mm) from a reference point 3 cm below the innominate tubercle of the greater trochanter angled 135° upward to the fracture line on the anteroposterior x-ray. The thickness (d) must be less than 20.5 mm for the fracture to be considered an A2 fracture. It is recommended that the measurement for the lateral wall be taken using the traction view with the leg in neutral rotation.^{6,7}

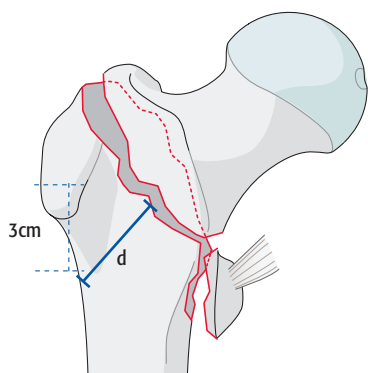


Fig 3 Defining lateral wall thickness.

Fibula

The lower leg, like the forearm is a two-bone system. In previous editions of the compendium, the fibula had its classification linked to the tibia code. To provide more flexibility in coding, a fibula code based on the CCF principles has been added. The use of an F is required to designate the fibula. The F follows the 4 which represents the anatomical area of the lower leg or tibia/fibula. If a fibula fracture is part of ankle fracture it is coded as a 44. The fibula code is used only for fibula fractures not associated with ankle fractures.

Proximal tibia (tibial plateau)

A more detailed description of the morphology and location of the proximal end segment articular fracture lines has been suggested (Mauricio Kfuri, personal communication, July 24, 2017). Kfuri and Schatzker have divided the proximal tibial articular surface into quadrants. The anterior and posterior segments are created by a virtual line from the anterior aspect of the fibular head (FH) to the posterior edge of the medial collateral ligament (MCL), which coincides with the medial tibial crest. The medial and lateral sides are determined by a line from the medial side of the anterior tibial tubercle to the posterior cortex and runs between the tibial spines. Using these two virtual planes, four quadrants of the tibial surface are defined: AL (anterolateral zone), PL (posterolateral zone), PM (posteromedial zone), AM (anteromedial zone) (**Fig 4**).

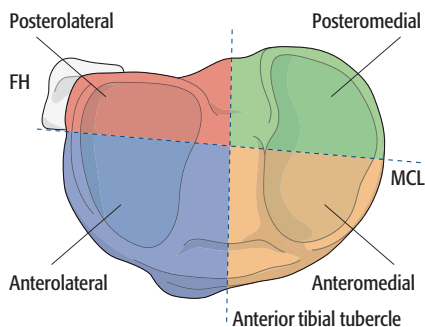


Fig 4 Quadrants of the proximal tibial articular surface.

The following rules apply to this detailed addition of the proximal tibia:

1. Using the CT scan, the quadrants are defined on the axial plane of the proximal tibia surface.
2. The fracture lines are followed until they emerge on the metaphyseal cortex. This will dictate the plane of the main fracture line.
3. If the main fracture plane emerges posterior to the virtual equator it is a P. If the main fracture plane emerges anterior to the virtual equator it is an A.
4. If the majority of the fragmentation or articular surface occurs either medially or laterally it is correlated with the cortical exit and coded using the qualifications for alphanumeric codes: AM for anteromedial, AL for anterolateral, PM for posterior medial or PL for posterior lateral.
5. These are usually applied to bicondylar fractures but may also be used for unilateral plateau fractures.

Malleolar segment

An isolated medial malleolar fracture is classified as a tibial distal end segment partial articular fracture, 43B1.2 or 43B2.2.

If the medial malleolar fracture is associated with a lateral side ankle injury, it is classified as a malleolar fracture, 44.

A fracture of the posterior articular margin (Volkman) without a lesion of the fibula is considered a fracture of the distal end segment of the tibia ie, 43B1.1 or 43B2.1.

If a fibula fracture is part of ankle fracture it is coded as a 44. The fibula code is used only for fibula fractures not associated with ankle fractures.

Scapula

The four quadrants (**Fig 5**) are defined by the equatorial line and the intertubercular line (maximum glenoid meridian) running from the supraglenoid tubercle to the infraglenoid tubercle.

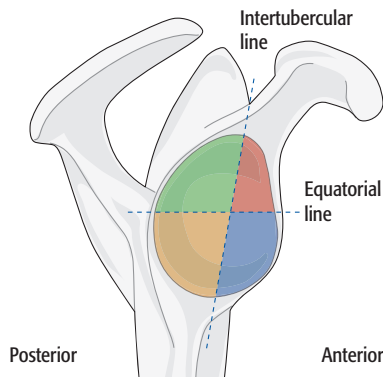


Fig 5 Quadrants of the proximal glenoid fossa.

Dislocations

The coding is as follows:

- The first number represents the distal bone of the dislocated joint
- The second number is 0 for dislocation (with the exception of the shoulder girdle where all dislocations are 10).
- The third letter (A, B, C, D, or E) is utilized when there are more than two bone articulations in the anatomical region.
- The direction of the dislocation is coded using the universal modifiers for dislocation direction [5_]. By convention, the direction of the dislocation is defined as the position of the distal bone relative to its anatomical position.

17 Periprosthetic fracture—arthroplasty related

The importance of the Unified Classification of Periprosthetic Fractures (UCPF) is its descriptive nature of the prosthesis-bone interface and relationship of the fracture to the prosthesis. Consequently, the use of the classification demands that the UCPF be used as the description of the fracture in the clinical scenario.

To standardize the coding process for the compendium, a modification of the UCPF was required. In collaboration with Duncan and Haddad, an agreement was reached to have the bone fracture code described first followed by the UCPF code enclosed in square brackets, thereby utilizing it as a universal modifier.

References

1. **Stimson LA.** *A Practical Treatise on Fractures and Dislocations.* 8th ed. New York and Philadelphia: Lea & Febiger; 1917:394.
2. **Watson-Jones, R.** *Fractures and Other Bone and Joint Injuries: Second Edition.* Edinburgh: E&S Livingstone; 1941:4934.
3. **Bohler, L.** *The Treatment of Fractures.* Vol 2. New York: Grune and Stratton; 1957:1370–1376.
4. **Wilson PD, Cochrane WA.** *Fractures and Dislocations.* Philadelphia and London: JB Lippincott; 1925: 513–519.
5. **Tang HC, Chen JJ, Yeh YC, et al.** Correlation of parameters on preoperative CT images with intra-articular soft-tissue injuries in acute tibial plateau fractures: A review of 132 patients receiving ARIF. *Injury.* 2017 Mar;48(3):745–750.
6. **Palm H, Jacobsen S, Sonne-Holm S, et al.** Hip Fracture Study Group. Integrity of the lateral femoral wall in intertrochanteric hip fractures: An important predictor of a reoperation. *J Bone Joint Surg Am.* 2007;89:470–475.
7. **Hsu CE, Shih CM, Wang CC, et al.** Lateral femoral wall thickness. A reliable predictor of post-operative lateral wall fracture in intertrochanteric fractures. *Bone Joint J.* 2013 Aug;95-b(8):1134–1138.

